



**PATIENT**

Daisy Douglas

**PRESENTING CLINICAL SIGNS**

Intermittent shaking, lethargy, possible neuropathy  
Abnormal PE/Chem/CBC/UA Results: nsf

**SPECIES**

Canine

**ULTRASONOGRAPHIC EXAMINATION OF THE ABDOMEN**

**Urinary System**

The **urinary bladder**, trigone, and pelvic urethra presented normal thicknesses and normal tone. The ureters were not visible which is normal. No uroliths or sediment were visualized and anechoic urine was present. No evidence of inflammatory or neoplastic changes was noted. Ureteral papillae were normal.

**BREED**

Bull Terrier

**SEX**

Spayed Female

The **kidneys** revealed largely normal size and structure, corticomedullary definition and ratio (cortex 1/3 of medulla) were essentially maintained with some age-related loss of curvilinear patterns regarding the capsule and C/M junction. The cortices presented largely uniform texture with some increased echogenicity expected for this age patient. Medullary structure differed distinctly from that of the cortex and no evidence of pelvic dilation was present. The right kidney measured 6.19 cm. The left kidney measured 4.8 cm.

**AGE**

9 years

**WEIGHT**

33.5 lbs

**Adrenal Glands**

Both **adrenal glands** were visualized and recognized as having normal shape, size, position and echogenicity for this breed. The phrenic vasculature, glandular echogenicity and detail were unremarkable. Capsule, cortex, and medullary definition were normal for this age patient. The left adrenal gland measured 3.19 x 0.5 cm at the caudal pole and 0.5 cm at the cranial pole. The right adrenal gland measured 2.8 x 0.63 cm at the caudal pole and 0.9 cm at the cranial pole.

**INTERPRETED BY**

Eric Lindquist, DMV  
DABVP, Cert. IVUSS

**IMAGING PERFORMED BY**

Diane McFadden, RVT

**Spleen**

The **spleen** was largely smooth with subtle heterogeneous parenchymal changes while maintaining normal echogenic relationship to the liver and kidney. These changes are consistent with normal age-related alteration. The capsule was smooth without noticeable impingement from within the spleen or from pathology in the adjacent abdomen. The splenic vasculature demonstrated normal volume without signs of congestion or significant contraction. No evidence of active acute or chronic inflammatory, neoplastic, or infarctual changes was noted.

**HOSPITAL NAME**

Rockaway

**INVOICE**

95022

**Liver**

**DATE**

1/5/22

The **liver** images from right and left intercostal as well as subcostal views revealed subjectively normal liver size, contour, and structure. Some age-related parenchymal remodeling was noted but likely not clinically significant at this time. Vascular and biliary tracts were of normal volume and no evidence of congestion was noted. The gallbladder presented some dependent debris with essentially normal contour. The cystic and common bile ducts were normal. No overt evidence of active inflammatory, infiltrative or regenerative pathology was noted but should be paired with current or past LE elevations regarding any clinical significance to this presentation. The hepatic lymph nodes were unremarkable.



**PATIENT**

**Gastrointestinal**

Daisy Douglas

Examination of the **gastrointestinal tract** revealed a stomach and intestine free of stasis, of normal wall thickness, acceptable curvilinear mural detail, and peristaltic activity. Small and large intestine demonstrated normal luminal chyme and stool consistency respectively. No obstructive or overt infiltrative disease was noted. No associated abnormal lymphatic activity was noted.

**SPECIES**

Canine

**BREED**

Bull Terrier

**Pancreas**

The base and limbs of the **pancreas** were observed to be largely isoechoic to surrounding omental fat. Pancreatic duct and capsular contour were acceptably normal and parenchyma respected normal curvilinear patterns. No overt evidence of active inflammatory or neoplastic disease was noted.

**SEX**

Spayed Female

**ULTRASONOGRAPHIC FINDINGS**

Age related abdominal changes.

**AGE**

9 years

**INTERPRETATION OF THE FINDINGS & FURTHER RECOMMENDATIONS**

**WEIGHT**

33.5 lbs

There was no evidence of contributing pathology.

**INTERPRETED BY**

Eric Lindquist, DMV  
DABVP, Cert. IVUSS

**IMAGING PERFORMED BY**

Diane McFadden, RVT

**HOSPITAL NAME**

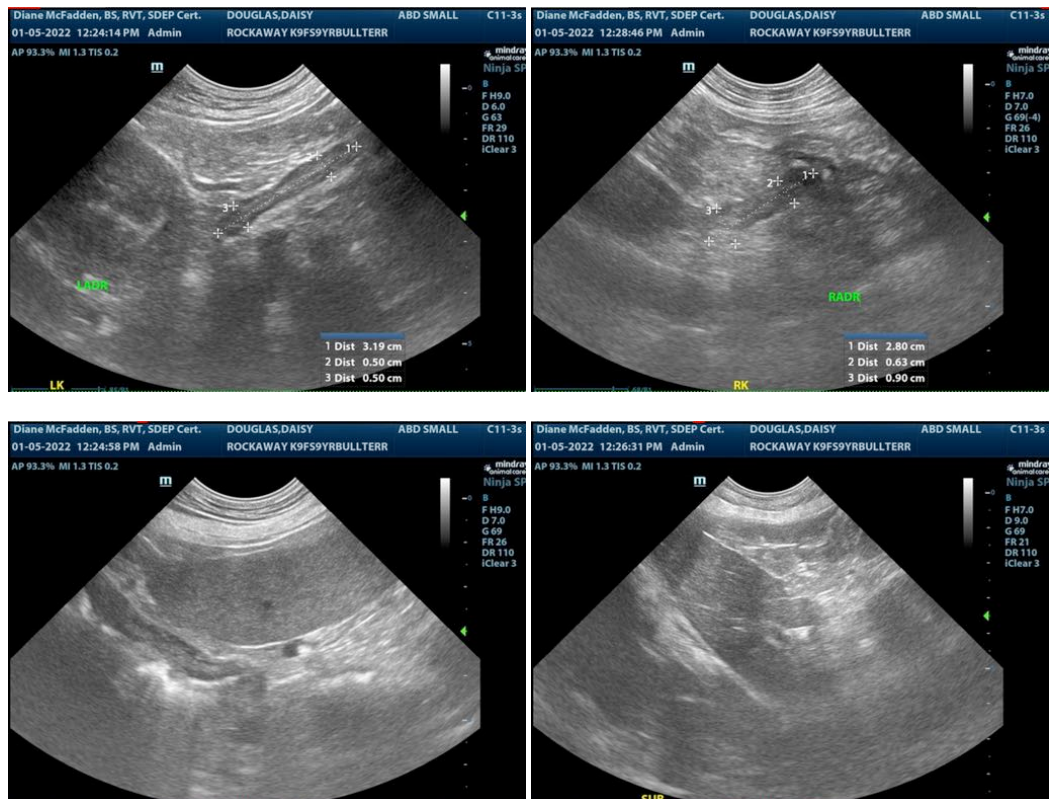
Rockaway

**INVOICE**

95022

**DATE**

1/5/22





**PATIENT**

Daisy Douglas

**SPECIES**

Canine

**BREED**

Bull Terrier

**SEX**

Spayed Female

**AGE**

9 years

**WEIGHT**

33.5 lbs

**INTERPRETED BY**

Eric Lindquist, DMV  
DABVP, Cert. IVUSS

**IMAGING PERFORMED BY**

Diane McFadden, RVT

**HOSPITAL NAME**

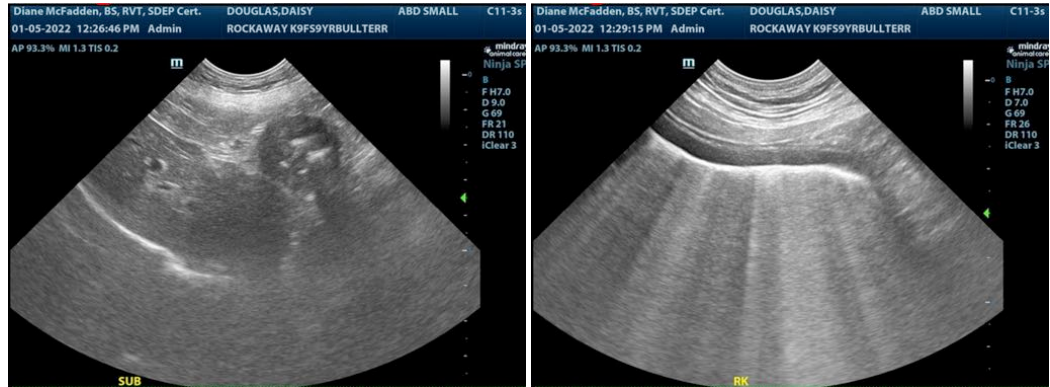
Rockaway

**INVOICE**

95022

**DATE**

1/5/22



The information and recommendations provided are based on the images presented by the referring veterinarian. No evaluation can be communicated regarding pathology that was not visible in the image/video clips provided.

Thank you for this referral. If the clinical or image interpretation does not parallel your findings or if I can be of any further assistance please contact me.

Eric Lindquist, DMV, DABVP, Cert. IVUSS, CEO of SonoPath.com  
Info@SonoPath.com