



**PATIENT**

Bentley Kiernan

**PRESENTING CLINICAL SIGNS**

recheck echo, previously diagnosed unclassified cardiomyopathy, pleural effusion. On pimobendan and clopidogrel

**SPECIES**

Feline

**ULTRASONOGRAPHIC EXAMINATION OF THE HEART**

**BREED**

Cornish Rex

**SEX**

Neutered Male

**AGE**

9 Years

**WEIGHT**

8 Pounds

FELINE CARDIAC PARAMETERS	BODY WEIGHT (kg)	HR (BPM)	IVSd (cm)	LVIDd (cm)	LVWd (cm)	FS (%)	EF (%)
<b>NORMAL PARAMETER</b>	-----	150-240	0.3-0.6	1.0-2.1	0.25-0.6	35-67	80-100
<b>PATIENT</b>		217	0.26	1.72	0.28	33	65
FELINE CARDIAC PARAMETERS	LA/AO (Boon)	LA/AO HEART BASE (Sisson)	LA 2D 4-chamber long axis AS to FW (Sisson) (cm)		LVOT VEL. (m/s)	RVOT VEL. (m/s)	IVRT (m)
<b>NORMAL PARAMETER</b>	<1.5	0.88-1.79	0.7-1.7		<1.6	<1.3	40-60
<b>PATIENT</b>	2.04	2.16				0.6	NM

Adapted from June Boon, Veterinary Echocardiography, 1998  
Sisson D et al. JVIM 1991; 5: 232, Jacobs et al. Am J Vet Res 1985; 46:1705

**INTERPRETED BY**

Eric Lindquist, DMV DABVP, Cert. IVUSS

**Cardiac Presentation**

The cardiac presentation revealed persistent volume overload of the left heart. Tachycardia present. The ventricular septum is mildly irregular. A small ventricular septal defect may be present, yet not playing a significant role. Slight pericardial and pleural effusion noted. Right atrium enlargement is present with tricuspid insufficiency. Hepatic veins were not dilated.

**IMAGING PERFORMED BY**

Diane McFadden

**ULTRASONOGRAPHIC FINDINGS**

- Unclassified cardiomyopathy with persistent volume overload in the left atrium and left ventricle and secondary pericardial effusion

**HOSPITAL NAME**

Rockaway AH

**INTERPRETATION OF THE FINDINGS & FURTHER RECOMMENDATIONS**

Recommend adjusting current medications. In addition to Pimobendan and Plavix, recommend Lasix at 12.5 mg BID, diminishing to minimal effective dose. ACE inhibitor also indicated at 0.5 mg/kg SID progressing to BID if the patient is able to tolerate the medications. Blood pressures and EKG warranted. Prognosis is extremely guarded. The patient is at high risk for sudden death.

**REFERRING VET**

Dr. Gannon

**INVOICE**

33973

**DATE**

1/5/22



**PATIENT**

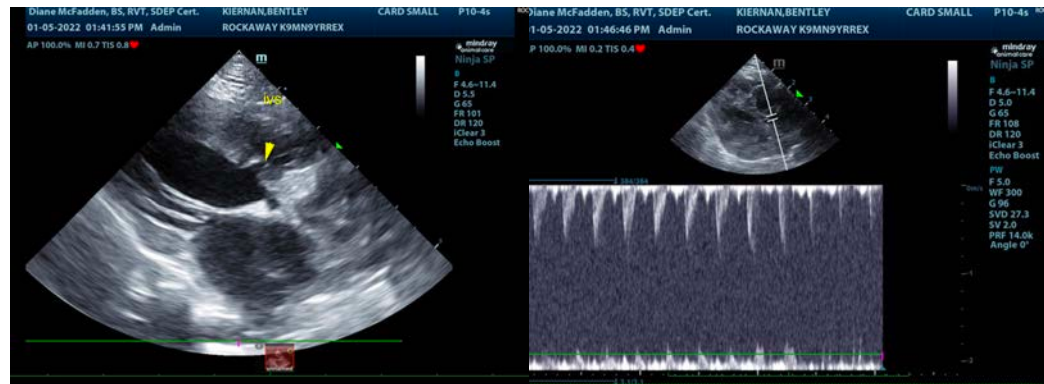
Bentley Kiernan

**SPECIES**

Feline

**BREED**

Cornish Rex



**SEX**

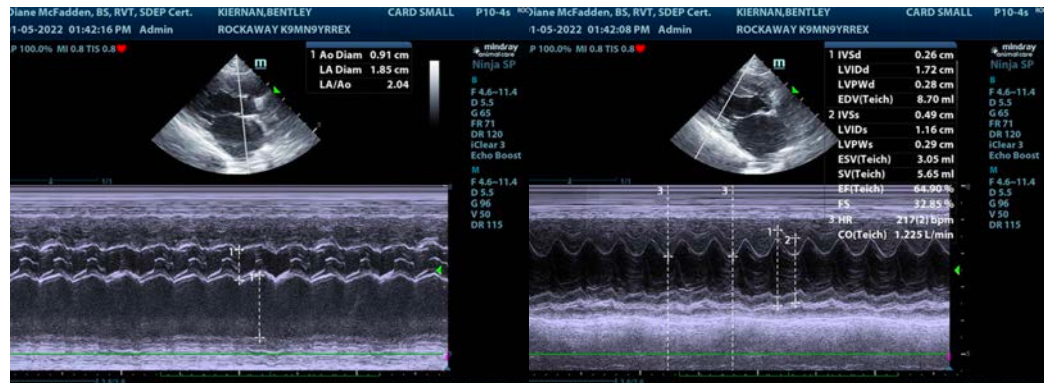
Neutered Male

**AGE**

9 Years

**WEIGHT**

8 Pounds



**INTERPRETED BY**

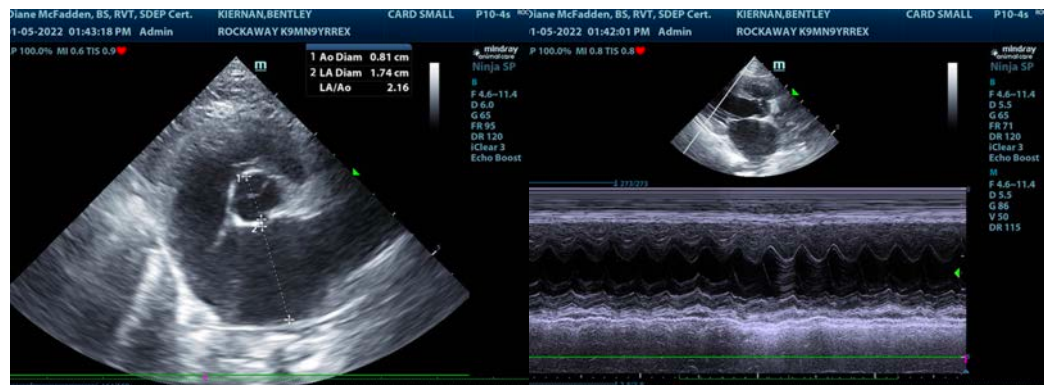
Eric Lindquist, DMV  
DABVP, Cert. IVUSS

**IMAGING PERFORMED BY**

Diane McFadden

**HOSPITAL NAME**

Rockaway AH



**REFERRING VET**

Dr. Gannon

**INVOICE**

33973

**DATE**

1/5/22

The information and recommendations provided are based on the images presented by the referring veterinarian. No evaluation can be communicated regarding pathology that was not visible in the image/video clips provided.

Thank you for this referral. If the clinical or image interpretation does not parallel your findings or if I can be of any further assistance please contact me.

Eric Lindquist, DMV, DABVP, Cert. IVUSS, CEO of SonoPath.com  
[info@SonoPath.com](mailto:info@SonoPath.com)