



PATIENT PRESENTING CLINICAL SIGNS

River Lund Enlarged submandibular lymph nodes. Planning LN biopsy tomorrow. No current meds. Bloods pending.

SPECIES ULTRASONOGRAPHIC EXAMINATION OF THE HEART & ABDOMEN

Canine

BREED

Golden Retriever

SEX

Neutered Male

AGE

7 Years

WEIGHT

79 Pounds

CANINE CARDIAC PARAMETERS	MR VMAX (m/s)	TR VMAX (m/s)	LA/AO (Boon method)	LA/AO (Heart Base; Swe)	FS (%)	EF (%)	EPSS (cm)
NORMAL PARAMETER	4.5-5.5	<2.7	1.3	<1.6	28-40	40-100	<0.6
PATIENT	5.5		1.0	1.2	21	41	0.6
CANINE CARDIAC PARAMETERS	HR (BPM)	AV VMAX (m/s)	PV MAX (m/s)	BODY WEIGHT (kg)	LA 2D short axis Base view (cm)	LVIDd Avg; 2D and m-mode short axis (cm)	LVIDs Avg; 2D and m-mode short axis (cm)
NORMAL PARAMETER	50-100	0.7-1.7	0.7-1.6	BELOW	BELOW	BELOW	BELOW
PATIENT	85	1.06	0.76		3.58	4.06	

Cardiac Presentation

The echocardiogram in this patient demonstrated normal **left atrial** size based on 3 different LA measurement methods. Chamber volumes and echogenicity were normal. The cranial and caudal **mitral** valve leaflets presented vegetative thickening consistent with endocardiosis. Doppler indicated measurable insufficiency. The **left ventricle** presented normal volume and minor hypocontractility. This may be owing to an athletic status or secondary to systemic disease. However, this appears to be well compensated at this time. The **myocardium** presented normal echogenicity without subjective evidence of significant fibrotic or ischemic disease. The **left ventricular outflow** tract demonstrated normal laminar flow and subjective structural integrity. The **right atrium** and auricle revealed normal size, structure and content. No evidence of masses was noted or chamber overload. **Tricuspid** valvular assessment demonstrated adequate linear morphology. The **right ventricle** was of normal size (1/3 diameter of LV), chordae structure, myocardial echogenicity and thickness. **Pulmonic** tract assessment revealed normal valve structure, laminar flow, and diameter (approx. 1:1 pa/ao ratio). No visible **pericardial** or free pleura fluid was noted. No echographically detectable evidence of infiltrative disease was visible. The cranial **mediastinum** and **pericardial** regions were free of masses in the visible window.

Urinary System

The **urinary bladder**, trigone, and pelvic urethra presented normal thicknesses and normal tone. The ureters were not visible which is normal. No uroliths or sediment were visualized and anechoic urine was present. No evidence of inflammatory or neoplastic changes were noted. Ureteral papillae were normal.

INVOICE

43900

DATE

1/4/23

The **kidneys** revealed normal size and structure, corticomedullary definition and ratio for this age. The cortices presented largely uniform texture with normal echogenic relationship to liver and spleen. Medullary structure differed distinctly from the cortex and no evidence of pelvic dilation was present. The capsules were acceptably uniform without significant irregularities. The right kidney measured 5.44 cm. The left kidney measured 6.76 cm.

INTERPRETED BY

Eric Lindquist, DMV

DABVP, Cert. IVUSS

IMAGING PERFORMED BY

Kelly Vazquez

HOSPITAL NAME

Marsh Hospital for Animals

REFERRING VET

Dr. Milwicki



PATIENT

River Lund

SPECIES

Canine

BREED

Golden Retriever

SEX

Neutered Male

AGE

7 Years

WEIGHT

79 Pounds

INTERPRETED BY

Eric Lindquist, DMV

DABVP, Cert. IVUSS

IMAGING PERFORMED BY

Kelly Vazquez

HOSPITAL NAME

Marsh Hospital for
Animals

REFERRING VET

Dr. Milwicki

INVOICE

43900

DATE

1/4/23

Adrenal Glands

Both **adrenal glands** were visualized and recognized as having normal shape, size, position and echogenicity for this breed. The phrenic vasculature, glandular echogenicity and detail were unremarkable. Capsule, cortex, and medullary definition were normal for this age patient. The left adrenal gland measured 3.09 cm x 0.54 cm at the caudal pole and 0.56 cm at the cranial pole. The right adrenal gland measured 2.26 cm x 1.05 cm at the cranial pole and 0.59 cm at the caudal pole.

Spleen

The **spleen** was enlarged with subtle micronodular changes and folded upon itself cranially. No overt masses noted. Reactive spleen versus early round cell neoplasia.

Liver

The **liver** images submitted revealed subjectively normal liver size, contour, and structure. Parenchymal echogenicity was naturally coarse and hypoechoic to the spleen. Vascular and biliary tracts were of normal volume with no evidence of congestion. The gallbladder presented acceptably thin walls with primarily anechoic content. The cystic and common bile ducts were normal. No pathological hepatic lymphadenopathy was evident. No overt structural evidence of inflammatory, infiltrative or regenerative pathology was evident.

Gastrointestinal

Examination of the **gastrointestinal tract** revealed a stomach and intestine free of stasis, of normal wall thickness, acceptable curvilinear mural detail, and peristaltic activity. Small and large intestine demonstrated normal luminal chyme and stool consistency respectively. No obstructive or overt infiltrative disease was noted. No associated abnormal lymphatic activity was noted.

Pancreas

The base and limbs of the **pancreas** were observed to be largely isoechoic to surrounding omental fat. Pancreatic duct and capsular contour were acceptably normal and parenchyma respected normal curvilinear patterns. No overt evidence of active inflammatory or neoplastic disease was noted.

ULTRASONOGRAPHIC FINDINGS

- Stage B1 valvular disease with likely athletic state and secondary hypocontractility/normal variant
- Micronodular spleen – strong potential for early infiltrative/lymphoma.

INTERPRETATION OF THE FINDINGS & FURTHER RECOMMENDATIONS

No cardiac therapy recommended.

Splenic FNA would be ideal. However, if the peripheral lymphadenopathy reveals lymphoma, the spleen is strongly suggestive of an early infiltrative pattern/lymphoma. The remainder of the abdomen was unremarkable. No abdominal lymphadenopathy noted.



PATIENT

River Lund

SPECIES

Canine

BREED

Golden Retriever

SEX

Neutered Male

AGE

7 Years

WEIGHT

79 Pounds

INTERPRETED BY

Eric Lindquist, DMV

DABVP, Cert. IVUSS

IMAGING PERFORMED BY

Kelly Vazquez

HOSPITAL NAME

Marsh Hospital for
Animals

REFERRING VET

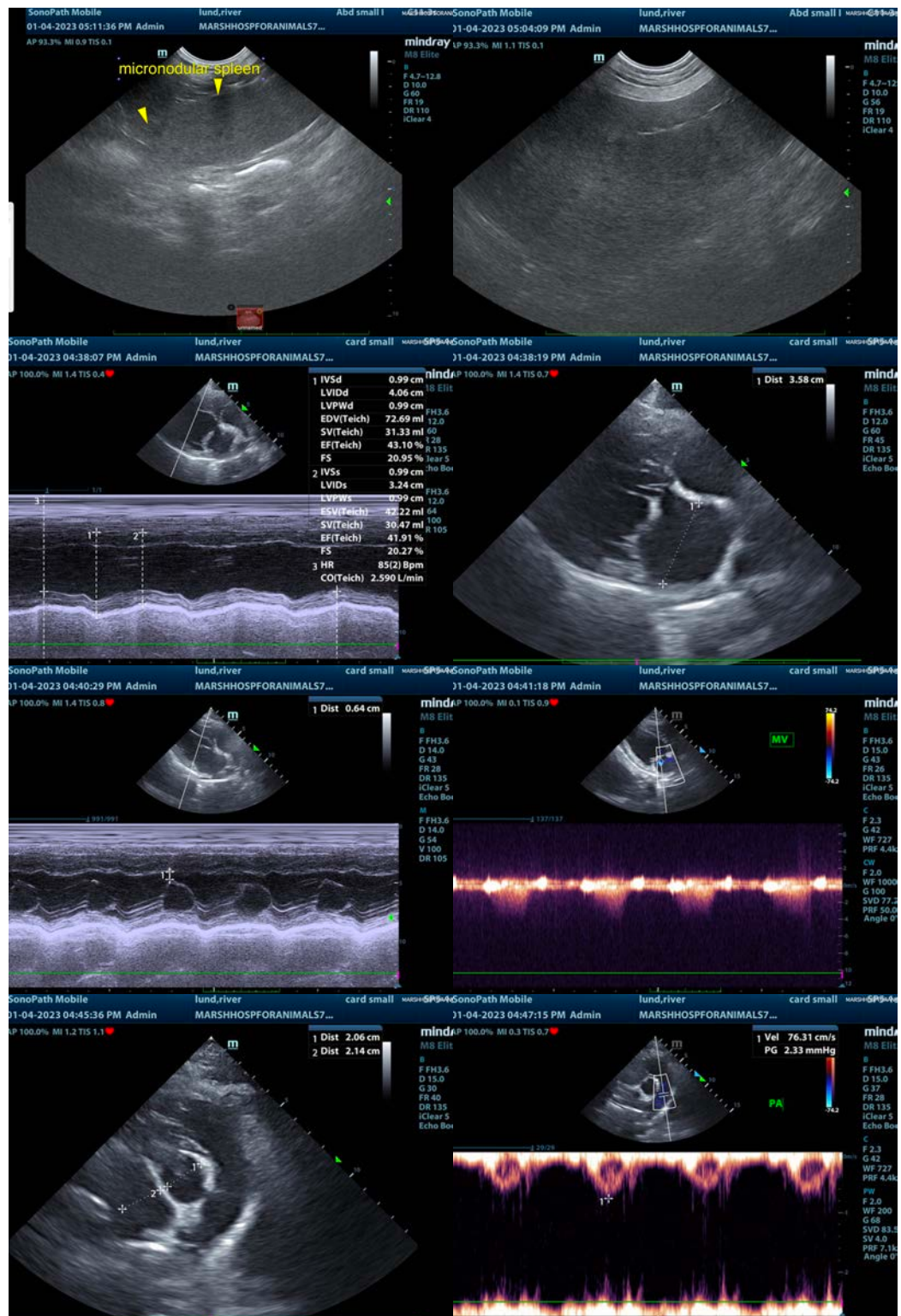
Dr. Milwicki

INVOICE

43900

DATE

1/4/23





PATIENT

River Lund

SPECIES

Canine

BREED

Golden Retriever

SEX

Neutered Male

AGE

7 Years

WEIGHT

79 Pounds

INTERPRETED BY

Eric Lindquist, DMV

DABVP, Cert. IVUSS

IMAGING PERFORMED BY

Kelly Vazquez

HOSPITAL NAME

Marsh Hospital for
Animals

REFERRING VET

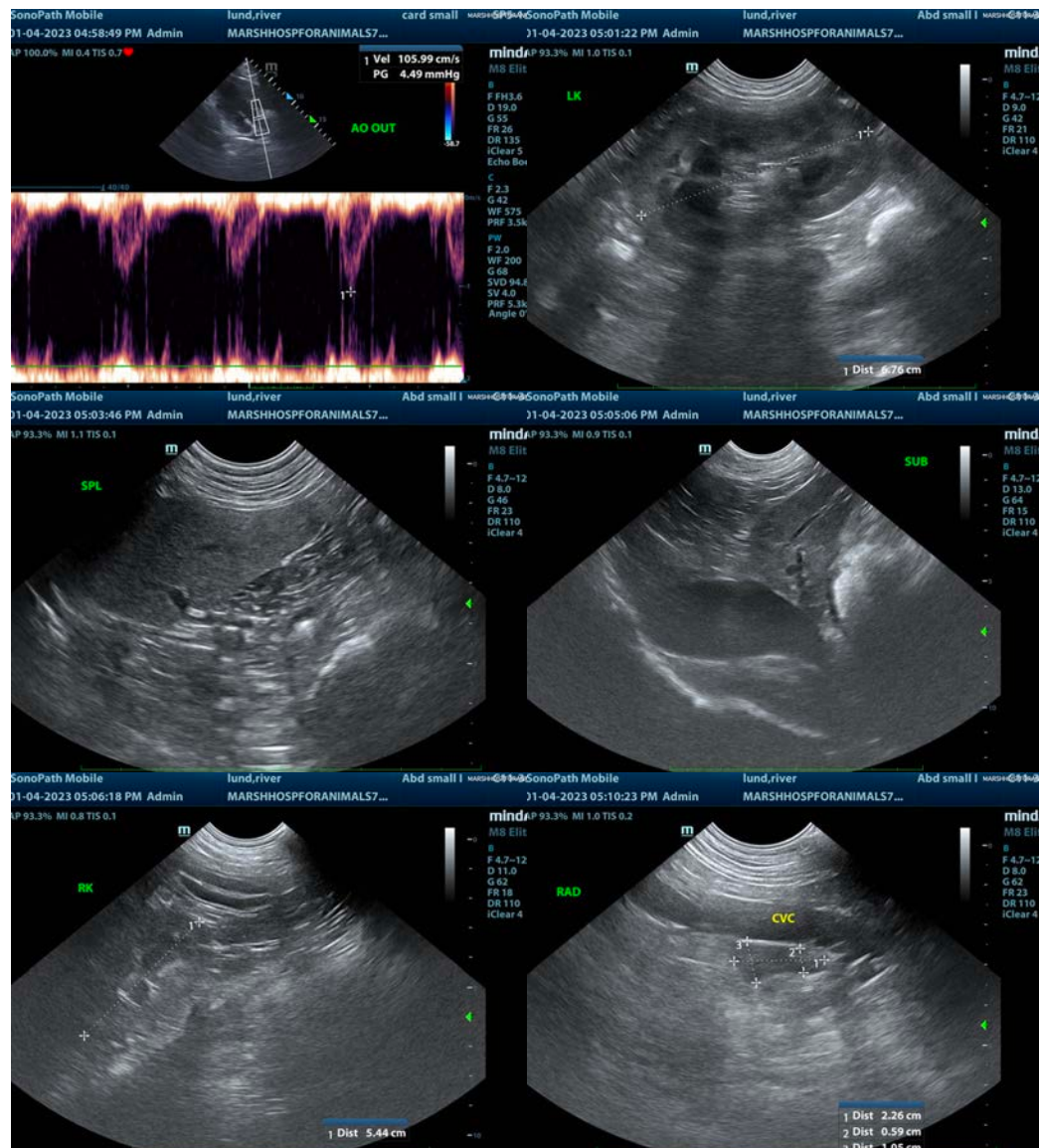
Dr. Milwicki

INVOICE

43900

DATE

1/4/23





PATIENT

River Lund

SPECIES

Canine

BREED

Golden Retriever

SEX

Neutered Male

AGE

7 Years

WEIGHT

79 Pounds

INTERPRETED BY

Eric Lindquist, DMV
DABVP, Cert. IVUSS

IMAGING PERFORMED BY

Kelly Vazquez

HOSPITAL NAME

Marsh Hospital for
Animals

REFERRING VET

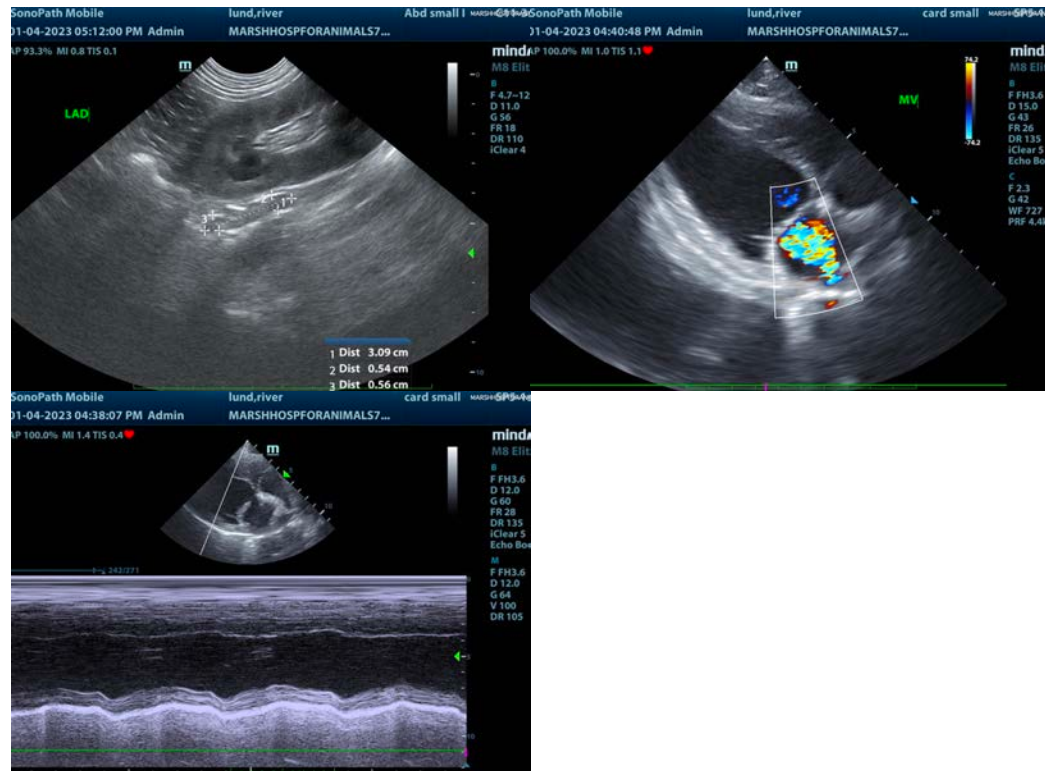
Dr. Milwicki

INVOICE

43900

DATE

1/4/23



The information and recommendations provided are based on the images presented by the referring veterinarian/sonographer. No evaluation can be communicated regarding pathology that was not visible in the image/video clips provided.

Thank you for this referral. If the clinical or image interpretation does not parallel your findings or if I can be of any further assistance please contact me.

Eric Lindquist, DMV, DABVP, Cert. IVUSS, CEO of SonoPath.com

info@SonoPath.com