



PATIENT

Lloyd Maxwell Church

SPECIES

Canine

BREED

Rhodesian Ridgeback

SEX

Neutered male

AGE

7 years

WEIGHT

79 lbs

INTERPRETED BY

Eric Lindquist, DMV
DABVP, Cert. IVUSS

**IMAGING
PERFORMED BY**

Dr. Norman

HOSPITAL NAME

Scanvet

REFERRING VET

Dr. Ebersole

INVOICE

42525

DATE

1/4/23

PRESENTING CLINICAL SIGNS

History: SQ mass noted in L inguinal area. FNA done of L inguinal mass.
Abnormal PE/Chem/CBC/UA Results: PE: firm, mildly irregular mass in L inguinal region, SQ.
Prominent nipples. Empty scrotal sac.

ULTRASONOGRAPHIC EXAMINATION OF THE ABDOMEN

Urinary System

The **urinary bladder**, trigone, and pelvic urethra presented normal thicknesses and normal tone. The ureters were not visible which is normal. No uroliths or sediment were visualized and anechoic urine was present. No evidence of inflammatory or neoplastic changes was noted. Ureteral papillae were normal.

The prostate was slightly enlarged in this patient, yet uniform and measured 3.0 cm. This would suggest an intact male status.

The **kidneys** revealed normal size and structure, corticomedullary definition and ratio for this age. The cortices presented largely uniform texture with normal echogenic relationship to liver and spleen. Medullary structure differed distinctly from the cortex and no evidence of pelvic dilation was present. The capsules were acceptably uniform without significant irregularities. The left kidney measured 7.35 cm. The right kidney measured 7.36 cm.

Adrenal Glands

Both **adrenal glands** were visualized and recognized as having normal shape, size, position and echogenicity for this breed. The phrenic vasculature, glandular echogenicity and detail were unremarkable. Capsule, cortex, and medullary definition were normal for this age patient. The right adrenal gland measured 2.29 x 1.69 cm at the cranial pole and 0.62 cm at the caudal pole. The left adrenal gland measured 0.57 cm at the cranial pole and 0.58 cm at the caudal pole.

Spleen

The **spleen** presented a smooth homogeneous parenchyma hyperechoic to liver and renal cortical parenchyma. The capsule was smooth without noticeable expansion or deviation from within the spleen or adjacent pathology. The splenic vasculature demonstrated normal volume without signs of congestion or thrombosis. No sonographic evidence of acute or chronic inflammatory, neoplastic, or infarctual changes was noted.

Liver

The **liver** images submitted revealed subjectively normal liver size, contour, and structure. Parenchymal echogenicity was naturally coarse and hypoechoic to the spleen. Vascular and biliary tracts were of normal volume with no evidence of congestion. The gallbladder presented acceptably thin walls with primarily anechoic content. The cystic and common bile ducts were normal. No pathological hepatic lymphadenopathy was evident. No overt structural evidence of inflammatory, infiltrative or regenerative pathology was evident.



PATIENT

Gastrointestinal

Lloyd Maxwell Church

Examination of the **gastrointestinal tract** revealed a stomach and intestine free of stasis, of normal wall thickness, acceptable curvilinear mural detail, and peristaltic activity. Small and large intestine demonstrated normal luminal chyme and stool consistency respectively. No obstructive or overt infiltrative disease was noted. No associated abnormal lymphatic activity was noted.

SPECIES

Canine

BREED

Rhodesian Ridgeback

Pancreas

The base and limbs of the **pancreas** were observed to be largely isoechoic to surrounding omental fat. Pancreatic duct and capsular contour were acceptably normal and parenchyma respected normal curvilinear patterns. No overt evidence of active inflammatory or neoplastic disease was noted.

SEX

Neutered male

Free Abdomen

The left inguinal area revealed an undifferentiated, hypoechoic, expansive 5.7 cm mass. The inguinal mass appears to have an epididymis.

AGE

7 years

ULTRASONOGRAPHIC FINDINGS

WEIGHT

79 lbs

Inguinal mass with intact prostate, suggestive for Sertoli cell tumor.

INTERPRETATION OF THE FINDINGS & FURTHER RECOMMENDATIONS

INTERPRETED BY

Eric Lindquist, DMV
DABVP, Cert. IVUSS

FNA can be considered. The mass appears resectable and is outside of the body cavity. Otherwise, unremarkable abdomen.

IMAGING PERFORMED BY

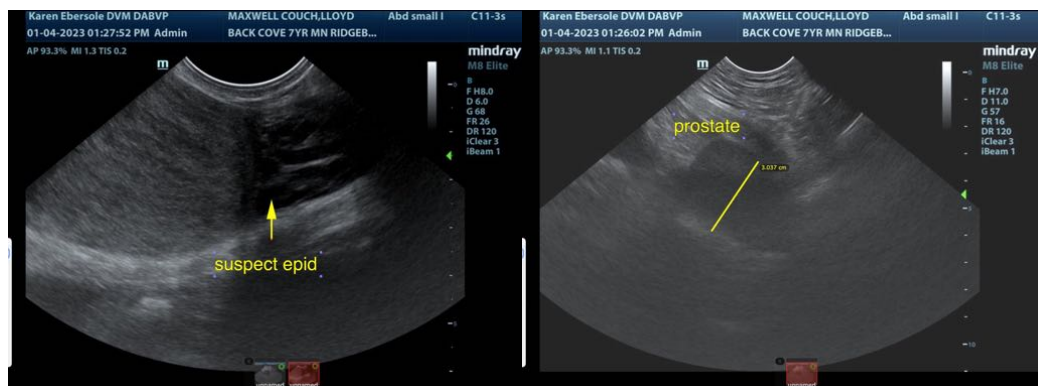
Dr. Norman

HOSPITAL NAME

Scanvet

REFERRING VET

Dr. Ebersole



INVOICE

42525

DATE

1/4/23



PATIENT

Lloyd Maxwell Church

SPECIES

Canine

BREED

Rhodesian Ridgeback

SEX

Neutered male

AGE

7 years

WEIGHT

79 lbs

INTERPRETED BY

Eric Lindquist, DMV
DABVP, Cert. IVUSS

**IMAGING
PERFORMED BY**

Dr. Norman

HOSPITAL NAME

Scanvet

REFERRING VET

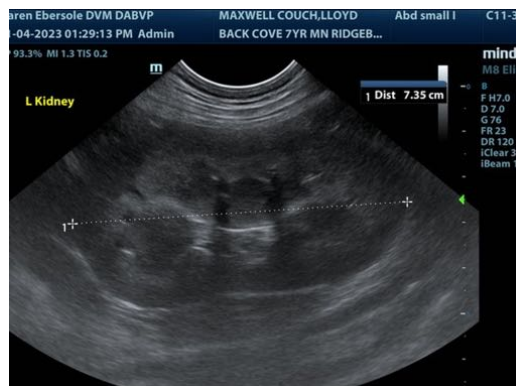
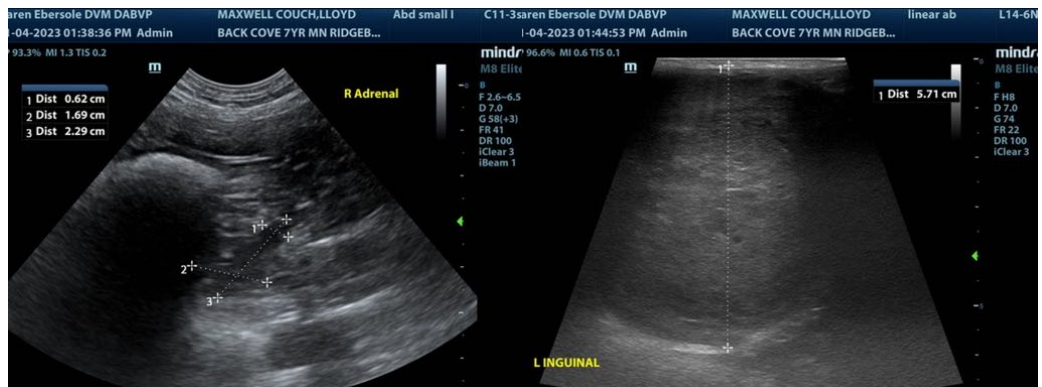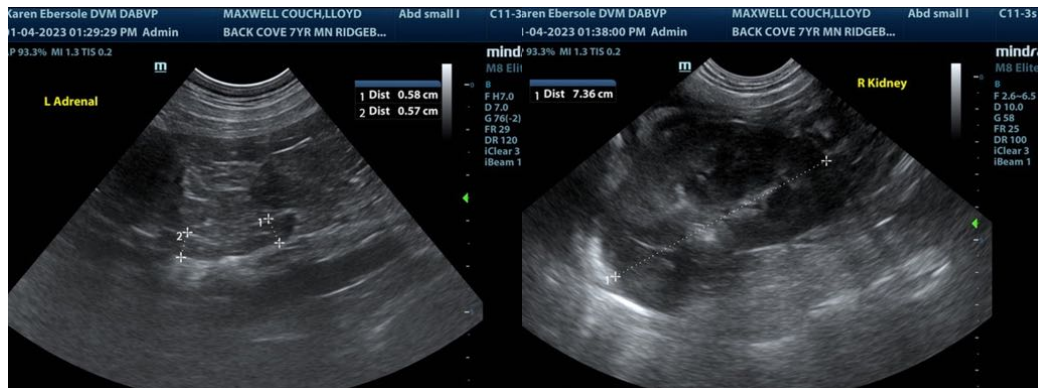
Dr. Ebersole

INVOICE

42525

DATE

1/4/23



The information and recommendations provided are based on the images presented by the referring veterinarian/sonographer. No evaluation can be communicated regarding pathology that was not visible in the image/video clips provided.

Thank you for this referral. If the clinical or image interpretation does not parallel your findings or if I can be of any further assistance please contact me.

Eric Lindquist, DMV, DABVP, Cert. IVUSS, CEO of SonoPath.com
info@SonoPath.com