



**PATIENT**

Dickens Speelman

**SPECIES**

Canine

**BREED**

West Highland Terrier

**SEX**

Neutered male

**AGE**

4 years

**WEIGHT**

9.1 kg

**INTERPRETED BY**

Eric Lindquist, DMV  
DABVP, Cert. IVUSS

**IMAGING  
PERFORMED BY**

Dr. Biederbeck

**HOSPITAL NAME**

Lomsnes VH

**REFERRING VET**

Dr. Biederbeck

**INVOICE**

42515

**DATE**

1/4/23

**PRESENTING CLINICAL SIGNS**

History: Chronically elevating AlkP despite stopping topical mometasone over 2 months ago. Has not ever been on oral steroids, only mometasone on feet prior to this. Allergies, severe, on RC HP, cytopoint, under the care of a DAVD. Chronic vomiting, controlled on metoclopramide, ranitidine for years. Abnormal PE/Chem/CBC/UA Results: AlkP Dec 30-991, Oct 26-932, June 30-772, 2021-512 GGT, Tbili Oct 31-normal LDDST done-normal 1st am USG 1.037, u/a normal -note-Oct 26th: mildly elevated TP/alb/glucose- (TP 81 55-75, Alb 41 27-39, glob normal. Glucose 6.5 3.5-6.3) Stopped mometasone on feet Nov 2nd, no other steroids oral or topical.

**ULTRASONOGRAPHIC EXAMINATION OF THE ABDOMEN**

**Urinary System**

The **urinary bladder**, trigone, and pelvic urethra presented normal thicknesses and normal tone. The ureters were not visible which is normal. No uroliths or sediment were visualized and anechoic urine was present. No evidence of inflammatory or neoplastic changes was noted. Ureteral papillae were normal.

The **kidneys** revealed normal size and structure, corticomedullary definition and ratio for this age. The cortices presented largely uniform texture with normal echogenic relationship to liver and spleen. Medullary structure differed distinctly from the cortex and no evidence of pelvic dilation was present. The capsules were acceptably uniform without significant irregularities. Both kidneys measured 4.0 cm.

**Adrenal Glands**

Both **adrenal glands** were visualized and recognized as having normal shape, size, position and echogenicity for this breed. The phrenic vasculature, glandular echogenicity and detail were unremarkable. Capsule, cortex, and medullary definition were normal for this age patient. The left adrenal gland measured 0.5 cm. The right adrenal gland measured 0.6 cm.

**Spleen**

The **spleen** in this patient was mildly enlarged with uniform parenchyma and was folded upon itself cranially. This is a positional variant and is not pathological. There was no evidence of significant disease.

**Liver**

The **liver** images submitted revealed subjectively normal liver size, contour, and structure. Parenchymal echogenicity was naturally coarse and hypoechoic to the spleen. Vascular and biliary tracts were of normal volume with no evidence of congestion. The gallbladder presented acceptably thin walls with primarily anechoic content. The cystic and common bile ducts were normal. No pathological hepatic lymphadenopathy was evident. No overt structural evidence of inflammatory, infiltrative or regenerative pathology was evident.



**PATIENT**

Dickens Speelman

**SPECIES**

Canine

**BREED**

West Highland Terrier

**SEX**

Neutered male

**AGE**

4 years

**WEIGHT**

9.1 kg

**Gastrointestinal**

Examination of the **gastrointestinal tract** revealed a stomach and intestine free of stasis, of normal wall thickness, acceptable curvilinear mural detail, and peristaltic activity. Small and large intestine demonstrated normal luminal chyme and stool consistency respectively. No obstructive or overt infiltrative disease was noted. No associated abnormal lymphatic activity was noted.

**Pancreas**

The base and limbs of the **pancreas** were observed to be largely isoechoic to surrounding omental fat. Pancreatic duct and capsular contour were acceptably normal and parenchyma respected normal curvilinear patterns. No overt evidence of active inflammatory or neoplastic disease was noted.

**ULTRASONOGRAPHIC FINDINGS**

Structurally normal abdomen.

**INTERPRETATION OF THE FINDINGS & FURTHER RECOMMENDATIONS**

There is no evidence of pathology. The ALKP is likely a benign elevation and likely breed specific or genetically defined benign elevations or steroid induced. However, the liver is structurally unremarkable and benign.

**INTERPRETED BY**

Eric Lindquist, DMV  
DABVP, Cert. IVUSS

**IMAGING PERFORMED BY**

Dr. Biederbeck

**HOSPITAL NAME**

Lomsnes VH

**REFERRING VET**

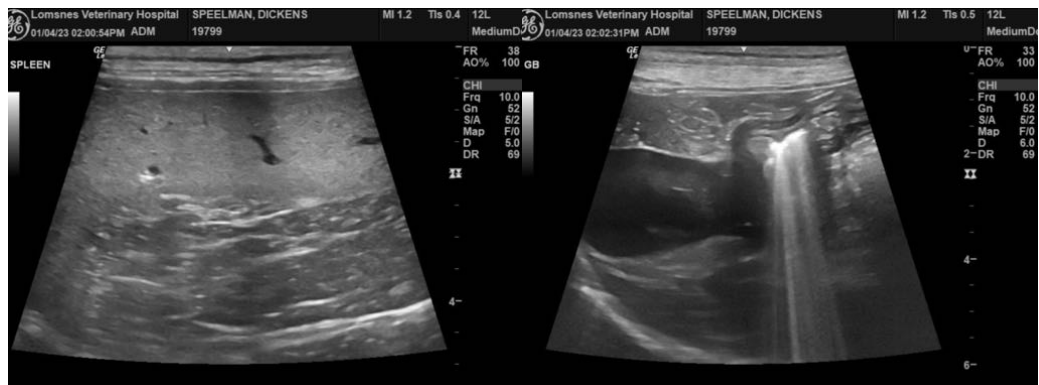
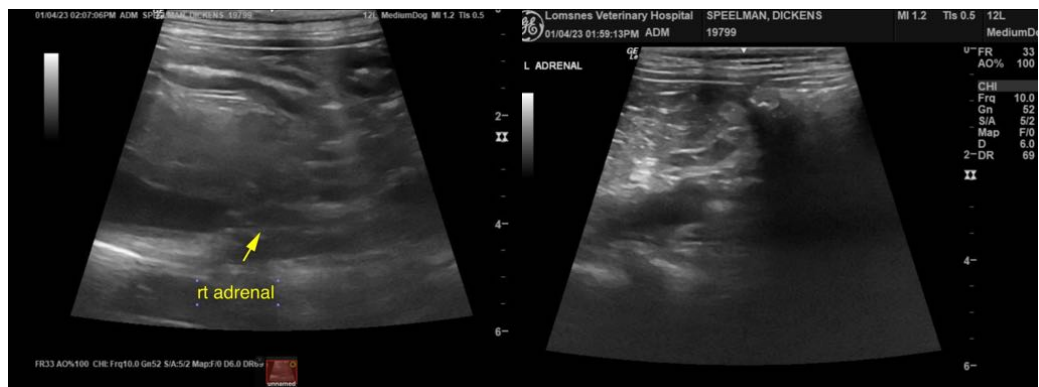
Dr. Biederbeck

**INVOICE**

42515

**DATE**

1/4/23





**PATIENT**

Dickens Speelman

**SPECIES**

Canine

**BREED**

West Highland Terrier

**SEX**

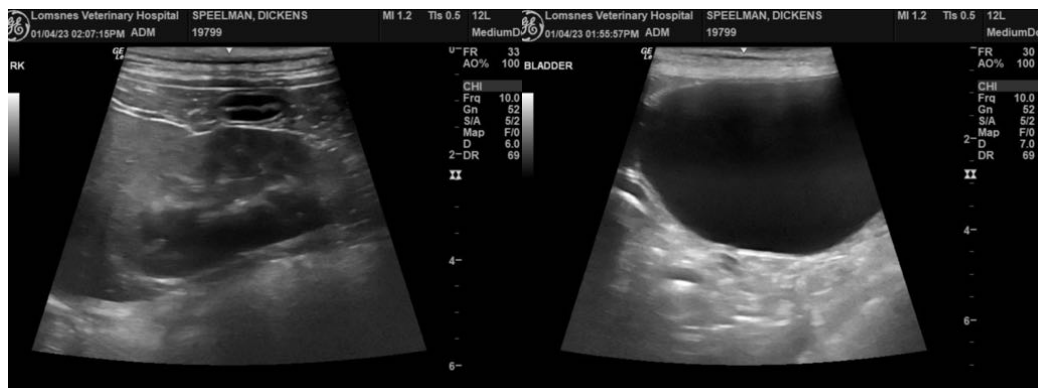
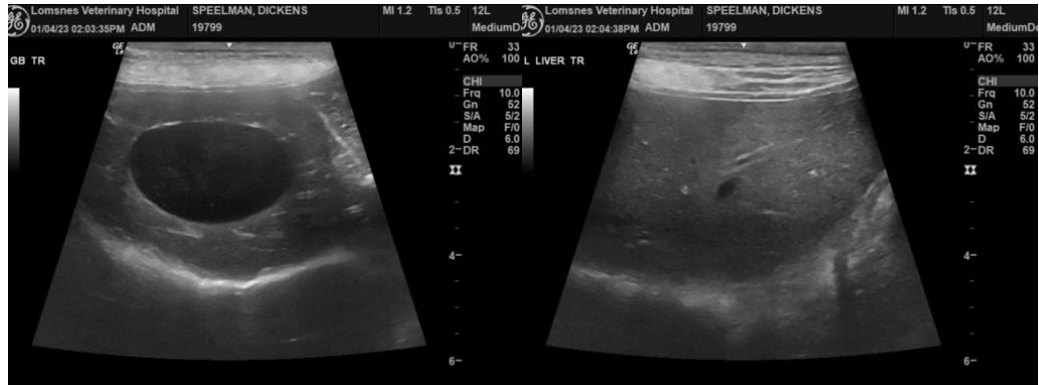
Neutered male

**AGE**

4 years

**WEIGHT**

9.1 kg



**INTERPRETED BY**

Eric Lindquist, DMV  
DABVP, Cert. IVUSS

**IMAGING PERFORMED BY**

Dr. Biederbeck

**HOSPITAL NAME**

Lomsnes VH

**REFERRING VET**

Dr. Biederbeck

**INVOICE**

42515

**DATE**

1/4/23

The information and recommendations provided are based on the images presented by the referring veterinarian/sonographer. No evaluation can be communicated regarding pathology that was not visible in the image/video clips provided.

Thank you for this referral. If the clinical or image interpretation does not parallel your findings or if I can be of any further assistance please contact me.

**Eric Lindquist, DMV, DABVP, Cert. IVUSS, CEO of SonoPath.com**  
info@SonoPath.com