



**PATIENT**

Stella McIntyre

**SPECIES**

Canine

**BREED**

Pomeranian

**SEX**

Spayed Female

**AGE**

10 years

**WEIGHT**

13.8 lbs

**INTERPRETED BY**

Eric Lindquist, DMV  
DABVP, Cert. IVUSS

**IMAGING PERFORMED BY**

Dr. Linscheid

**HOSPITAL NAME**

Family Pet VC

**REFERRING VET**

Dr. Linscheid

**INVOICE**

94973

**DATE**

1/4/22

**PRESENTING CLINICAL SIGNS**

Presented initially 3 weeks ago with bloated abdomen and inappetence. Elected to start on cerenia for nausea and bland diet. Now not eating very well and abdomen uncomfortable. Abnormal PE/Chem/CBC/UA Results: CBC/basic chemistry unremarkable. Abdomen tense and firm during exam with generalized discomfort. Pale mucous membranes with CRT <2 sec. Abdominal rads show loss of serosal detail in enlarged abdominal space.

**ULTRASONOGRAPHIC EXAMINATION OF THE ABDOMEN**

**\*\* 24 JPEG images were provided.**

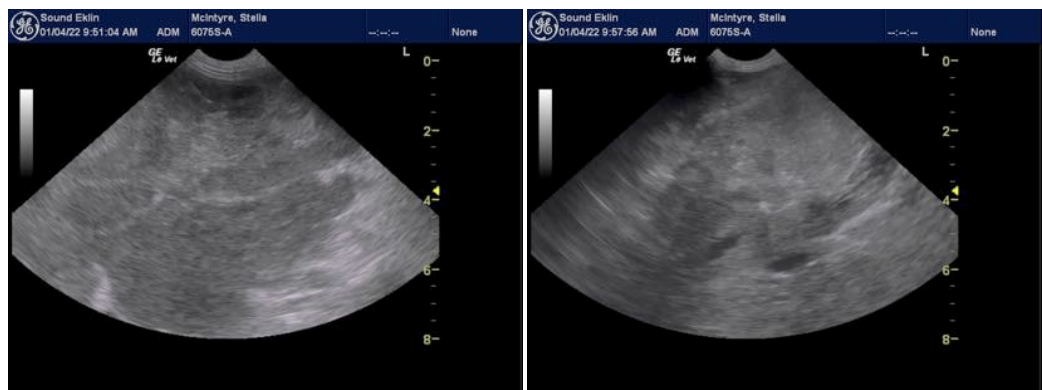
A large undifferentiated mass was noted in the abdomen. There were areas of cavitation noted. However, the mass appeared 90% parenchyma. Regional inflammation was noted. No significant organ structures were noted associated with the mass. The mass is presumed to be deriving from the spleen; however, hepatic involvement is possible. The images provided of the mass were undifferentiated and could not be directly localized to any particular organ. The image performed at 9:51:21 appears to have a kidney in the far field that measured 4.0 cm with mineralization of the mass. It appears to be deviating it.

**ULTRASONOGRAPHIC FINDINGS**

Undifferentiated mass.

**INTERPRETATION OF THE FINDINGS & FURTHER RECOMMENDATIONS**

The pattern of the mass is suggestive of hepatic involvement. However, further imaging is recommended from an intercostal approach and/or CT or exploratory surgery. Sarcoma is suspected.





**PATIENT**

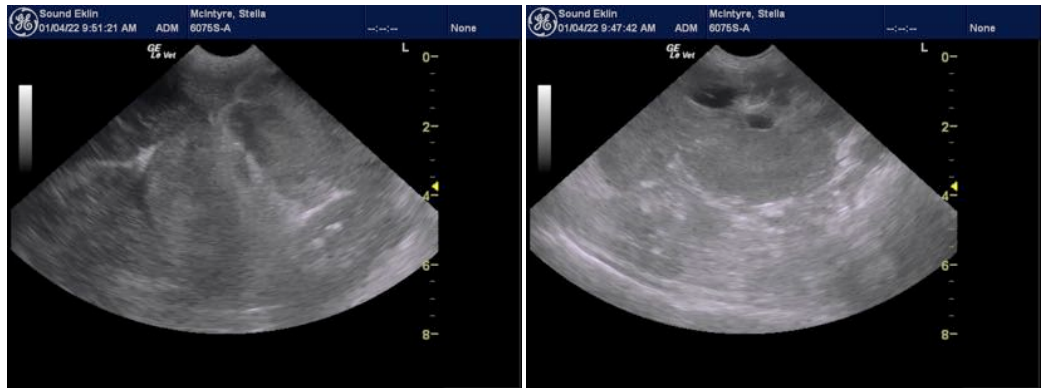
Stella McIntyre

**SPECIES**

Canine

**BREED**

Pomeranian



**SEX**

Spayed Female

The information and recommendations provided are based on the images presented by the referring veterinarian. No evaluation can be communicated regarding pathology that was not visible in the image/video clips provided.

**AGE**

10 years

Thank you for this referral. If the clinical or image interpretation does not parallel your findings or if I can be of any further assistance please contact me.

**WEIGHT**

13.8 lbs

Eric Lindquist, DMV, DABVP, Cert. IVUSS, CEO of SonoPath.com  
info@SonoPath.com

**INTERPRETED BY**

Eric Lindquist, DMV  
DABVP, Cert. IVUSS

**IMAGING PERFORMED BY**

Dr. Linscheid

**HOSPITAL NAME**

Family Pet VC

**REFERRING VET**

Dr. Linscheid

**INVOICE**

94973

**DATE**

1/4/22