



**PATIENT**

Maggie Stebbins

**PRESENTING CLINICAL SIGNS**

Elevated liver values on last senior labwork, higher on recheck labwork  
Abnormal PE/Chem/CBC/UA Results: 12/10/21: ALT = 148 1/4/22: ALT = 191

**SPECIES**

Canine

**ULTRASONOGRAPHIC EXAMINATION OF THE ABDOMEN**

**Urinary System**

**BREED**

Labrador

The **urinary bladder**, trigone, and pelvic urethra presented normal thicknesses and normal tone. The ureters were not visible which is normal. No uroliths or sediment were visualized and anechoic urine was present. No evidence of inflammatory or neoplastic changes was noted. Ureteral papillae were normal.

**SEX**

Female

The **kidneys** revealed largely normal size and structure, corticomedullary definition and ratio (cortex 1/3 of medulla) were essentially maintained with some age-related loss of curvilinear patterns regarding the capsule and C/M junction. The cortices presented largely uniform texture with some increased echogenicity expected for this age patient. Medullary structure differed distinctly from that of the cortex and no evidence of pelvic dilation was present. The left kidney measured 5.8 cm. The right kidney measured 6.89 cm.

**AGE**

13 years

**WEIGHT**

78 lbs

**Adrenal Glands**

Both **adrenal glands** were visualized and recognized as having normal shape, size, position and echogenicity for this breed. The phrenic vasculature, glandular echogenicity and detail were unremarkable. Capsule, cortex, and medullary definition were normal for this age patient. The right adrenal gland measures 0.77 cm at the cranial pole and 0.72 cm at the caudal pole. The left adrenal gland measured 0.72 cm at the cranial pole and 0.73 cm at the caudal pole.

**INTERPRETED BY**

Eric Lindquist, DMV  
DABVP, Cert. IVUSS

**IMAGING PERFORMED BY**

Chaley Hunt LVT

**Spleen**

The **spleen** presented a smooth homogeneous parenchyma hyperechoic to liver and renal cortical parenchyma. The capsule was smooth without noticeable expansion or deviation from within the spleen or adjacent pathology. The splenic vasculature demonstrated normal volume without signs of congestion or thrombosis. No sonographic evidence of acute or chronic inflammatory, neoplastic, or infarctual changes was noted.

**HOSPITAL NAME**

Columbia AC

**REFERRING VET**

Dr. Engel

**Liver**

The **liver** revealed non-specific, coarse architecture with increased portal markings. Heterogenous parenchymal changes were noted. The gallbladder and common bile duct were unremarkable with undulating hepatic contour. There was no evidence of neoplasia.

**INVOICE**

94982

**Gastrointestinal**

**DATE**

1/4/22

Examination of the **gastrointestinal tract** revealed a stomach and intestine free of stasis, of normal wall thickness, acceptable curvilinear mural detail, and peristaltic activity. Small and large intestine



**PATIENT**

Maggie Stebbins

demonstrated normal luminal chyme and stool consistency respectively. No obstructive or overt infiltrative disease was noted. No associated abnormal lymphatic activity was noted.

**SPECIES**

Canine

**Pancreas**

The base and limbs of the **pancreas** were observed to be largely isoechoic to surrounding omental fat. Pancreatic duct and capsular contour were acceptably normal and parenchyma respected normal curvilinear patterns. No overt evidence of active inflammatory or neoplastic disease was noted.

**BREED**

Labrador

**ULTRASONOGRAPHIC FINDINGS**

**SEX**

Female

Chronic inflammatory hepatopathy with nodular changes. I suspect emerging cirrhosis.

**AGE**

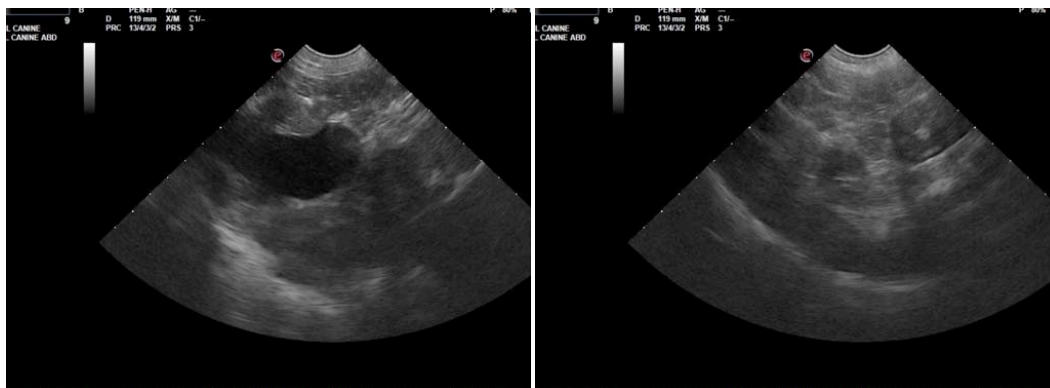
13 years

**INTERPRETATION OF THE FINDINGS & FURTHER RECOMMENDATIONS**

Bile acid profile is warranted. If the bile acids are elevated then core liver biopsy would be ideal. There is no suspicion of neoplasia. Leptospirosis titers are warranted to rule out chronic infection.

**WEIGHT**

78 lbs



**INTERPRETED BY**

Eric Lindquist, DMV  
DABVP, Cert. IVUSS

**IMAGING PERFORMED BY**

Chaley Hunt LVT

**HOSPITAL NAME**

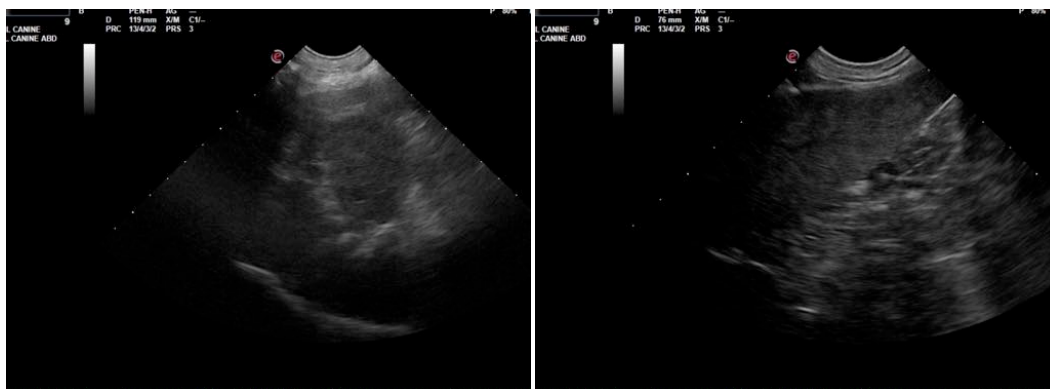Columbia AC

**REFERRING VET**

Dr. Engel

**INVOICE**

94982



**DATE**

1/4/22



**PATIENT**

Maggie Stebbins

**SPECIES**

Canine

**BREED**

Labrador

**SEX**

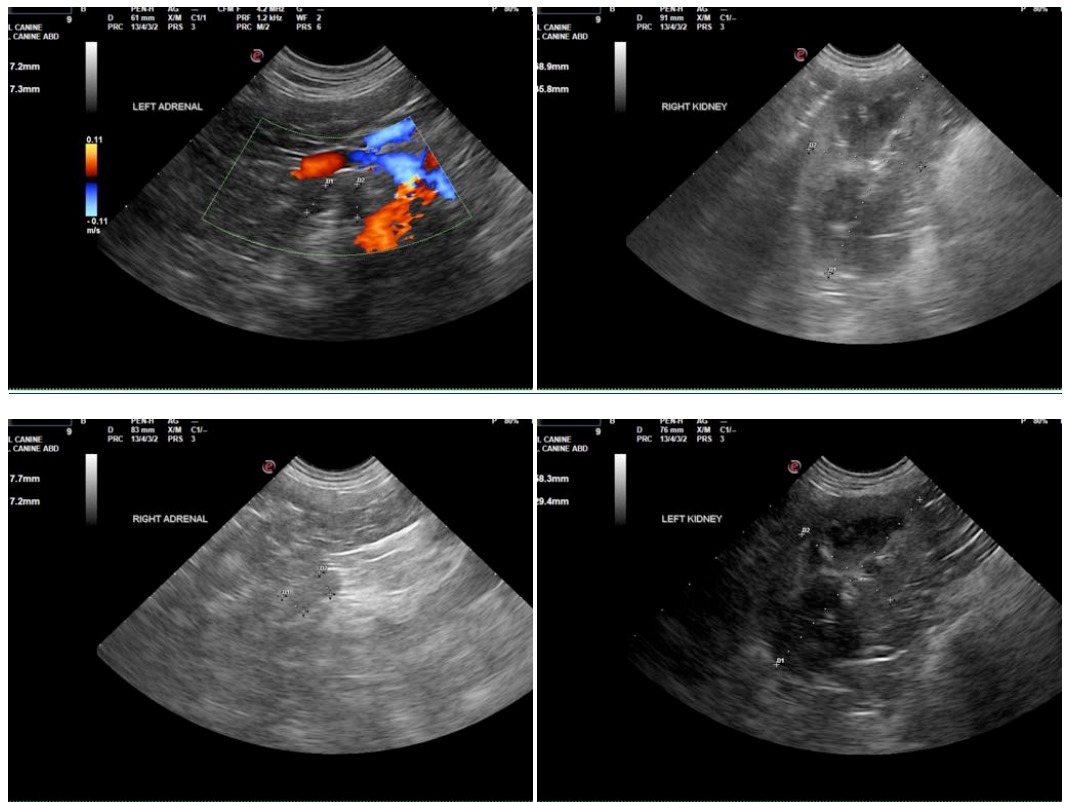
Female

**AGE**

13 years

**WEIGHT**

78 lbs



**INTERPRETED BY**

Eric Lindquist, DMV  
DABVP, Cert. IVUSS

**IMAGING PERFORMED BY**

Chaley Hunt LVT

**HOSPITAL NAME**

Columbia AC

**REFERRING VET**

Dr. Engel

**INVOICE**

94982

**DATE**

1/4/22

The information and recommendations provided are based on the images presented by the referring veterinarian. No evaluation can be communicated regarding pathology that was not visible in the image/video clips provided.

Thank you for this referral. If the clinical or image interpretation does not parallel your findings or if I can be of any further assistance please contact me.

Eric Lindquist, DMV, DABVP, Cert. IVUSS, CEO of SonoPath.com  
info@SonoPath.com