



PATIENT

Little Bo Bernardo

SPECIES

Feline

BREED

Domestic Shorthair

SEX

Spayed Female

AGE

15 years

WEIGHT

5.6 lbs

INTERPRETED BY

Eric Lindquist, DMV
DABVP, Cert. IVUSS

IMAGING PERFORMED BY

Dr. Bartus

HOSPITAL NAME

Valley VS

REFERRING VET

Dr. Bartus

INVOICE

94930

DATE

1/3/22

PRESENTING CLINICAL SIGNS

Indoor cat. Not eating & vomiting for 5 days. Losing weight recently. Last time cat was examined by a veterinarian was in 2008, so we don't know a previous adult weight.
Abnormal PE/Chem/CBC/UA Results: BUN 71 (16-36), ALT 170 (12-130), Na 149 (150-165), K 2.4 (3.5-5.8), Cl 100 (112-129) U/A: Sp. Gr. 1.030, Pro 30 mg/dl, WBC 3/hpf, RBC 4/hpf

ULTRASONOGRAPHIC EXAMINATION OF THE ABDOMEN

Urinary System

The **urinary bladder**, trigone, and pelvic urethra presented normal thicknesses and normal tone. The ureters were not visible which is normal. No uroliths or sediment were visualized and anechoic urine was present. No evidence of inflammatory or neoplastic changes was noted. Ureteral papillae were normal.

The **kidneys** revealed largely normal size and structure, corticomedullary definition and ratio (cortex 1/3 of medulla) were essentially maintained with some age-related loss of curvilinear patterns regarding the capsule and C/M junction. The cortices presented largely uniform texture with some increased echogenicity expected for this age patient. Medullary structure differed distinctly from that of the cortex and no evidence of pelvic dilation was present. The right kidney measured 3.83 cm. The left kidney measured 3.27 cm.

Adrenal Glands

Both **adrenal glands** were visualized and recognized as having normal shape, size, position and echogenicity for this breed. The phrenic vasculature, glandular echogenicity and detail were unremarkable. Capsule, cortex, and medullary definition were normal for this age patient. The right adrenal gland measured 0.2 cm. The left adrenal gland measured 0.26 cm.

Spleen

The **spleen** presented a smooth homogeneous parenchyma hyperechoic to liver and renal cortical parenchyma. The capsule was smooth without noticeable expansion or deviation from within the spleen or adjacent pathology. The splenic vasculature demonstrated normal volume without signs of congestion or thrombosis. No sonographic evidence of acute or chronic inflammatory, neoplastic, or infarctual changes was noted.

Liver

The **liver** images submitted revealed subjectively normal liver size, contour, and structure. Parenchymal echogenicity was naturally coarse and hypoechoic to the spleen. Vascular and biliary tracts were of normal volume with no evidence of congestion. The gallbladder presented acceptably thin walls with primarily anechoic content. The cystic and common bile ducts were normal. No pathological hepatic lymphadenopathy was evident. No overt structural evidence of inflammatory, infiltrative or regenerative pathology was evident.



PATIENT

Gastrointestinal

Little Bo Bernardo

The **gastrointestinal tract** revealed minor variable thickening and echogenic submucosal changes most consistent with low grade end result of chronic GI disease such as IBD and may be related to malassimilation of nutrients if any weight loss is present. No obvious neoplastic patterns were noted and luminal content as unremarkable.

SPECIES

Feline

BREED

Domestic Shorthair

Pancreas

The **pancreas** was largely unremarkable with minor, heterogenous changes noted at the right base. Low-grade inflammation is possible.

SEX

Spayed Female

ULTRASONOGRAPHIC FINDINGS

Minor intestinal thickening.

AGE

15 years

Geriatric abdomen.

Minor, heterogenous right pancreatic changes.

WEIGHT

5.6 lbs

INTERPRETATION OF THE FINDINGS & FURTHER RECOMMENDATIONS

Subxiphoid palpation is recommended to assess for pain-solicited response. If pain is noted low grade pancreatitis is suspected. There was no evidence of neoplasia. A clinical trial of the following may prove effective.

INTERPRETED BY

Eric Lindquist, DMV
DABVP, Cert. IVUSS

Triaditis/Pancreatitis protocol

Part or all of this protocol may be considered based on your clinical impression of the patient:

IMAGING PERFORMED BY

Dr. Bartus

Recommend pain management when anorexic with **Buprenorphine** (0.01-0.02 mg/kg IM or SC), clinical trial of **Zithromax** (50 mg sid/cat x 10 days, 3 weeks if bartonella +), **Prednisolone** (0.5-2 mg/kg tapering over 1 week to minimal effective dose), and **B12 injections** if weight loss (Cyanobalamine 250 mcg sub-q once-weekly x six weeks, then every other week for six weeks and then once-monthly, long-term if necessary), **novel-protein or hydrolyzed diet** (*Hydrolyzed diets have been shown to be more effective in dietary intolerance case management compared to hypoallergenic diets*) or the **magical Purina DM** (changing protein source is crucial and may need rotation every 6 months if clinical signs recur) Diet trials is a whatever works phenomenon. If vomiting becomes a persistent issue then endoscopy would be warranted and/or recheck sonogram to assess more emerging disease. One diet does not work for all patients so different trials may be necessary or protein source rotation every 6 months as new sensitivities develop.

HOSPITAL NAME

Valley VS

REFERRING VET

Dr. Bartus

INVOICE

94930

DATE

1/3/22



PATIENT

Little Bo Bernardo

SPECIES

Feline

BREED

Domestic Shorthair

SEX

Spayed Female

AGE

15 years

WEIGHT

5.6 lbs

INTERPRETED BY

Eric Lindquist, DMV
DABVP, Cert. IVUSS

IMAGING PERFORMED BY

Dr. Bartus

HOSPITAL NAME

Valley VS

REFERRING VET

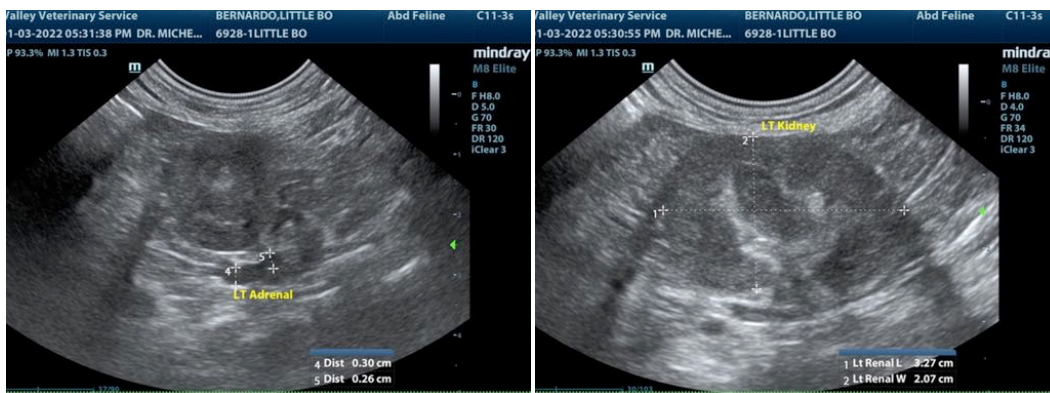
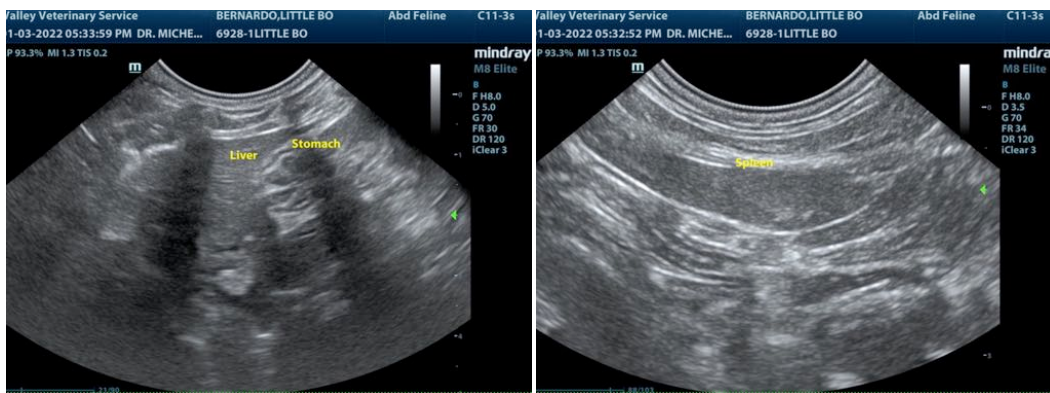
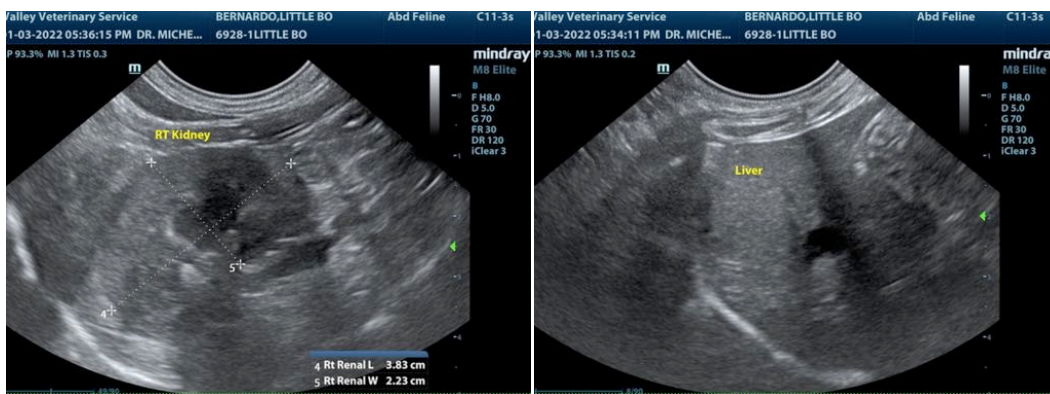
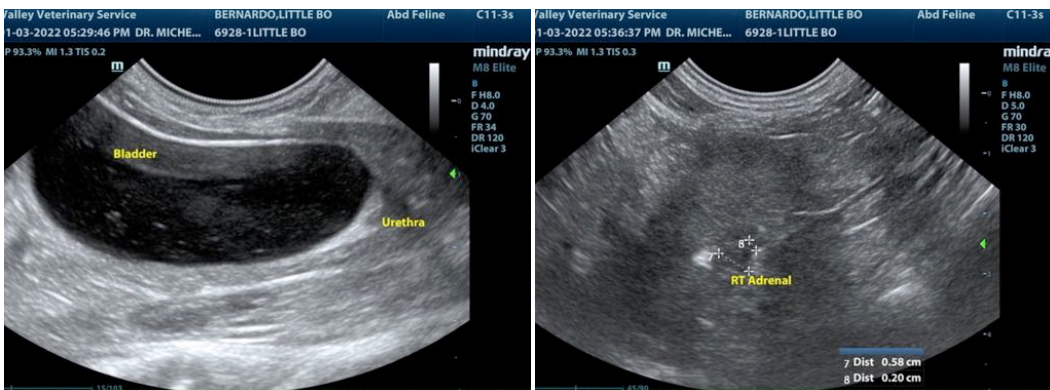
Dr. Bartus

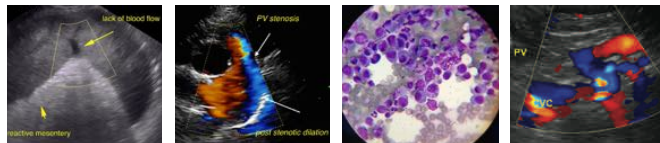
INVOICE

94930

DATE

1/3/22





PATIENT

Little Bo Bernardo

SPECIES

Feline

BREED

Domestic Shorthair

SEX

Spayed Female

AGE

15 years

WEIGHT

5.6 lbs

INTERPRETED BY

Eric Lindquist, DMV
DABVP, Cert. IVUSS

IMAGING PERFORMED BY

Dr. Bartus

HOSPITAL NAME

Valley VS

REFERRING VET

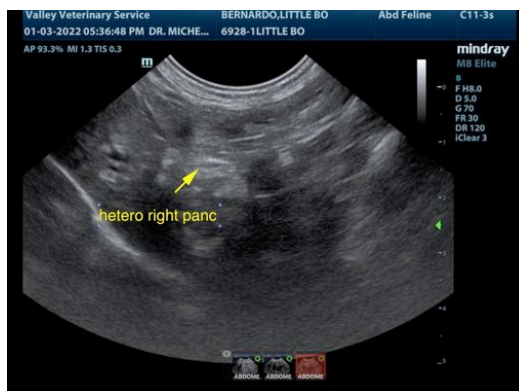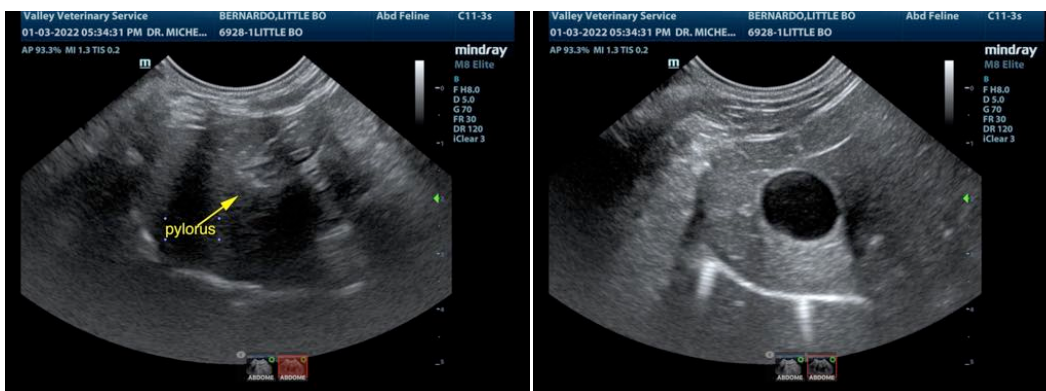
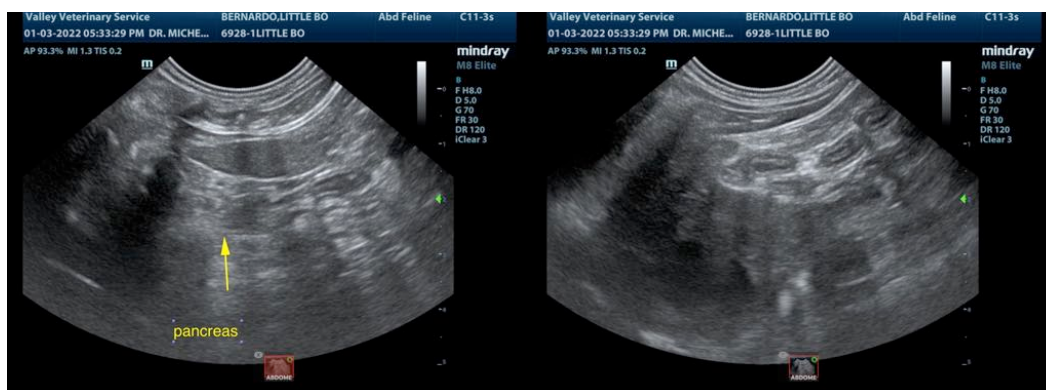
Dr. Bartus

INVOICE

94930

DATE

1/3/22



The information and recommendations provided are based on the images presented by the referring veterinarian. No evaluation can be communicated regarding pathology that was not visible in the image/video clips provided.

Thank you for this referral. If the clinical or image interpretation does not parallel your findings or if I can be of any further assistance please contact me.

Eric Lindquist, DMV, DABVP, Cert. IVUSS, CEO of SonoPath.com
info@SonoPath.com