

**PATIENT PRESENTING CLINICAL SIGNS**

Abby Davenport

Laryngeal thickening. Neck Larynx possible mass - Thickening of the laryngeal area noted, possible mass like effect, stertor worsens with palpation of this area. Discussed empirical therapy with abx and NSAIDs for 2 weeks, if no improvement or clinical signs are getting worse, recommend diagnostic,

**SPECIES**

Canine

Client elects to try empirical therapy and pursue diagnostics if no improvement.  
Rx Clindamycin 150mg PO BID x 14 days  
Rx Rovera 100mg 1/2 tab PO SID x 14 days

**BREED**

Beagle

**ULTRASONOGRAPHIC EXAMINATION**

**SEX**

Spayed Female

This exam is to report everything but the trachea and supplement the prior report. The thyroid lobes were imaged. The parathyroids measured up to 0.3 cm and were normal. There was no evidence of capsular deviation. The left thyroid lobe measured 0.7 x 1.5 cm. The right parathyroids were unremarkable. The right thyroid lobe measured 0.48 x 1.8 cm.

**AGE**

11 years

The right cervical area revealed an enlarged 2.23 x 0.9 cm lymph node enlargement. The salivary glands were unremarkable and uniform measuring 2.9 x 1.2 cm on the right. Regional subcutaneous and lymphatic tissues appeared uniform with no evidence of pathology.

**WEIGHT**

26.8 Pounds

**ULTRASONOGRAPHIC FINDINGS**

Normal thyroid and parathyroid glands with normal salivary glands and slight lymphadenopathy.

No evidence of significant extratracheal pathology.

Subcutaneous and cutaneous tissues were normal.

Normal vascular structures.

**INTERPRETED BY**

Eric Lindquist, DMV  
DABVP, Cert. IVUSS

**INTERPRETATION OF THE FINDINGS & FURTHER RECOMMENDATIONS**

No specific therapy is recommended.

**IMAGING PERFORMED BY**

Loetitia Saint-Jacques, RVT

**HOSPITAL NAME**

VCA Lakeside AH

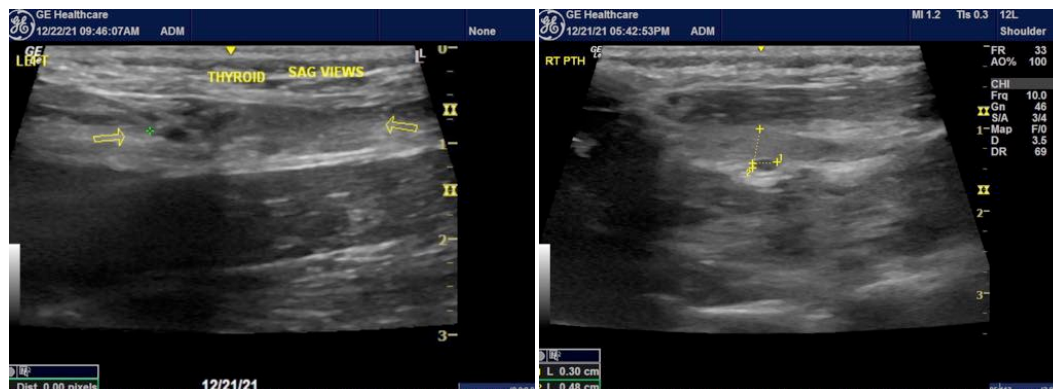
**REFERRING VET**

**INVOICE**

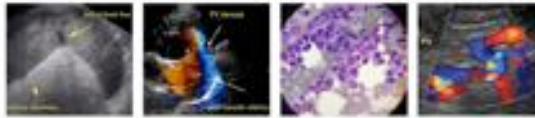
1156

**DATE**

1/4/22



The information and recommendations provided are based on the images presented by the referring veterinarian. No evaluation can be communicated regarding pathology that was not visible in the image/video clips provided.



**PATIENT**

Abby Davenport

Thank you for this referral. If the clinical or image interpretation does not parallel your findings or if I can be of any further assistance please contact me.

**SPECIES**

Canine

**Eric Lindquist**, DMV, DABVP, Cert. IVUSS, CEO of SonoPath.com  
[info@SonoPath.com](mailto:info@SonoPath.com)

**BREED**

Beagle

**SEX**

Spayed Female

**AGE**

11 years

**WEIGHT**

26.8 Pounds

**INTERPRETED BY**

Eric Lindquist, DMV  
DABVP, Cert. IVUSS

**IMAGING PERFORMED  
BY**

Loetitia Saint-Jacques, RVT

**HOSPITAL NAME**

VCA Lakeside AH

**REFERRING VET**

**INVOICE**

1156

**DATE**

1/4/22