



PATIENT

Loki Kennely

SPECIES

Canine

BREED

Labrador Collie Mix

SEX

Neutered male

AGE

6 years

WEIGHT

4 kg

INTERPRETED BY

Eric Lindquist, DMV
DABVP, Cert. IVUSS

IMAGING PERFORMED BY

Dr. Barnes

HOSPITAL NAME

Westview VH

REFERRING VET

Dr. Barnes

INVOICE

42451

DATE

1/31/23

PRESENTING CLINICAL SIGNS

History: Swollen ventral neck with enlarged LN, Suspect LSA but cannot R/O F/B puncture. Scan of cervical area, and other LN

Abnormal PE/Chem/CBC/UA Results: Normal temperature, No obvious fluctuant swelling, Tonsils are enlarged. The pre scaps and popliteal LN are slightly enlarged

ULTRASONOGRAPHIC EXAMINATION

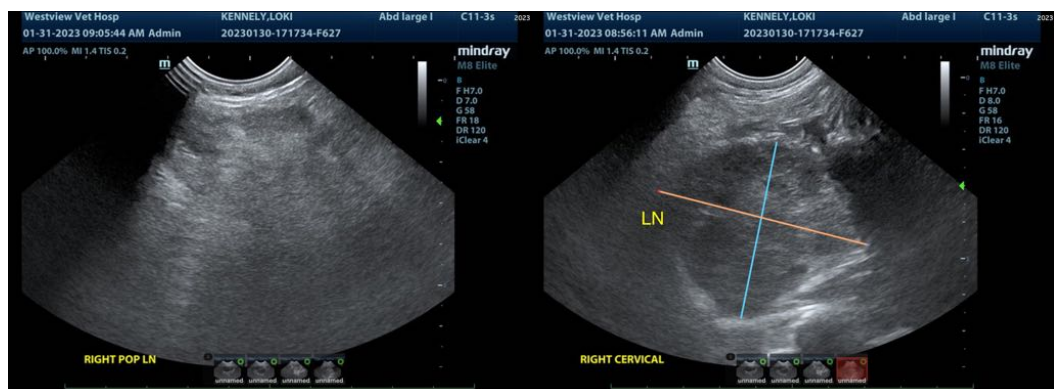
The cervical region revealed multi-focal, hypoechoic, rounded lymph nodes. Regional, hyperechoic inflammation was noted. Adjacent salivary glands appeared unremarkable. However, significant inflammation is noted in the region. The visible thyroid lobes were impinged upon, yet did not appear overtly involved. A larger, primary lymph node measured 5.0 x 6.0 cm with a cluster of adjacent lymph nodes. The grouping of which measured 4.0 x 3.0 cm with regional inflammation.

ULTRASONOGRAPHIC FINDINGS

Multi-centric cervical lymphadenopathy with significant inflammation.

INTERPRETATION OF THE FINDINGS & FURTHER RECOMMENDATIONS

I cannot absolutely rule out thyroid involvement as disruption of architecture was a theme throughout the visible image plain; however, this would be most consistent with multi-centric lymphadenopathy. Popliteal lymph nodes were also enlarged with a grouping measuring 2.5 cm. An abdominal sonogram is recommended if not already performed to assess for comorbidities, metastatic lesions as well as chest radiographs and cranial mediastinal imaging. The prognosis is guarded depending on responsiveness to lymphadenopathy. The lymph nodes were rounded, hypoechoic and distorted when peripherally inflamed throughout the image sets.





PATIENT

Loki Kennely

SPECIES

Canine

BREED

Labrador Collie Mix

SEX

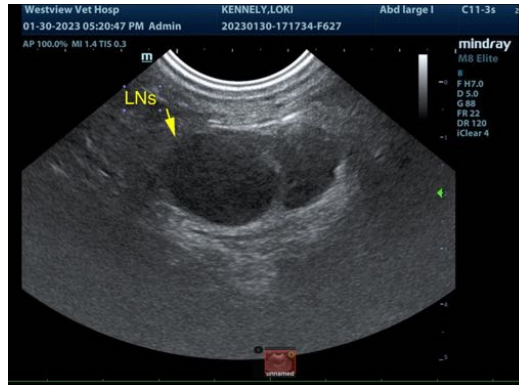
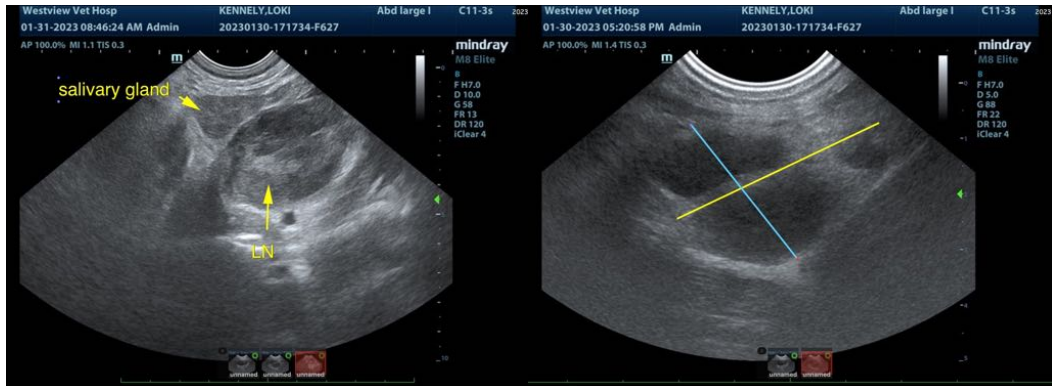
Neutered male

AGE

6 years

WEIGHT

4 kg



INTERPRETED BY

Eric Lindquist, DMV
DABVP, Cert. IVUSS

IMAGING PERFORMED BY

Dr. Barnes

HOSPITAL NAME

Westview VH

REFERRING VET

Dr. Barnes

INVOICE

42451

DATE

1/31/23

The information and recommendations provided are based on the images presented by the referring veterinarian/sonographer. No evaluation can be communicated regarding pathology that was not visible in the image/video clips provided.

Thank you for this referral. If the clinical or image interpretation does not parallel your findings or if I can be of any further assistance please contact me.

Eric Lindquist, DMV, DABVP, Cert. IVUSS, CEO of SonoPath.com
info@SonoPath.com