



**PATIENT**

Rocco Caldwell

**PRESENTING CLINICAL SIGNS**

new diabetic poss ethylene glycol consumption

**SPECIES**

Feline

**ULTRASONOGRAPHIC EXAMINATION OF THE ABDOMEN**

**Urinary System**

The **urinary bladder**, trigone, and pelvic urethra presented normal thicknesses and normal tone. The ureters were not visible which is normal. No uroliths or sediment were visualized and anechoic urine was present. No evidence of inflammatory or neoplastic changes were noted. Ureteral papillae were normal.

**BREED**

DSH

The **kidneys** were swollen and hypoechoic with thickened cortices. Pericapsular inflammatory pattern noted with trace amounts of fluid. The right kidney measured 4.68 cm. The left kidney measured 3.65 cm.

**SEX**

Neutered Male

**Adrenal Glands**

The regions of the **adrenal glands** were unremarkable.

**AGE**

7 Years

**Spleen**

The **spleen** in this patient was uniform, yet volume contracted. Hydration status should be assessed.

**WEIGHT**

7 Pounds

**Liver**

The **liver** was diffusely hyperechoic and swollen, consistent with metabolic hepatopathy. The gallbladder and common bile duct were unremarkable.

**INTERPRETED BY**

Eric Lindquist, DMV

DABVP, Cert. IVUSS

**Gastrointestinal**

Examination of the **gastrointestinal tract** revealed a stomach and intestine free of stasis, of normal wall thickness, acceptable curvilinear mural detail, and peristaltic activity. Small and large intestine demonstrated normal luminal chyme and stool consistency respectively. No obstructive or overt infiltrative disease was noted. No associated abnormal lymphatic activity was noted.

**IMAGING PERFORMED BY**

Jenn

**Pancreas**

The **pancreas** was hypoechoic and irregular with undulating contour. Suspect inflammation.

**HOSPITAL NAME**

Rockaway AH

**ULTRASONOGRAPHIC FINDINGS**

- Nephritis pattern
- Possible pancreatitis
- Metabolic hepatopathy

**REFERRING VET**

Dr. Maniar

**INTERPRETATION OF THE FINDINGS & FURTHER RECOMMENDATIONS**

Urinalysis warranted to assess for changes consistent with ethylene glycol or other forms of nephritis. Eventual bile acid profile warranted.

**INVOICE**

35336

**DATE**

1/31/22



**PATIENT**

Rocco Caldwell

**SPECIES**

Feline

**BREED**

DSH

**SEX**

Neutered Male

**AGE**

7 Years

**WEIGHT**

7 Pounds

**INTERPRETED BY**

Eric Lindquist, DMV  
DABVP, Cert. IVUSS

**IMAGING PERFORMED BY**

Jenn

**HOSPITAL NAME**

Rockaway AH

**REFERRING VET**

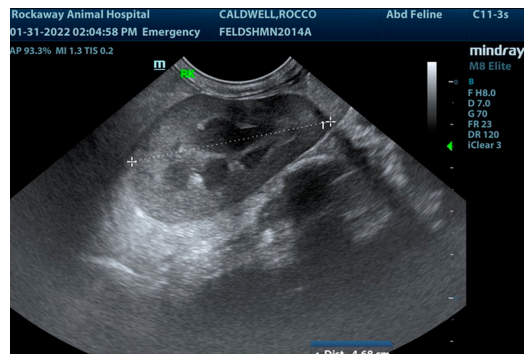
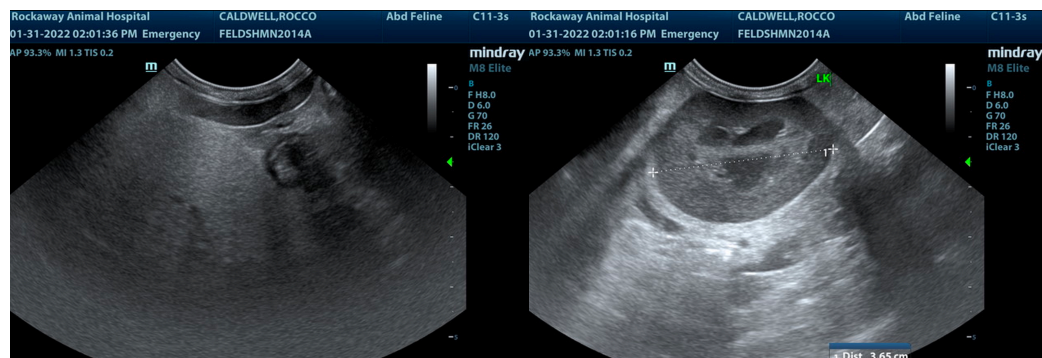
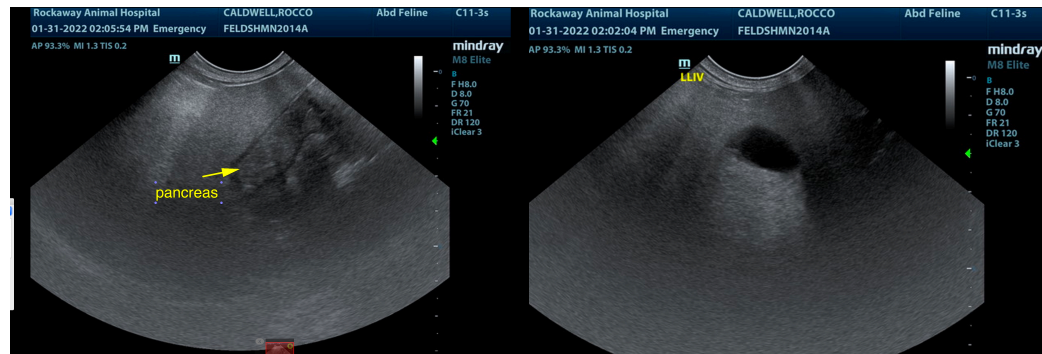
Dr. Maniar

**INVOICE**

35336

**DATE**

1/31/22



The information and recommendations provided are based on the images presented by the referring veterinarian/sonographer. No evaluation can be communicated regarding pathology that was not visible in the image/video clips provided.

Thank you for this referral. If the clinical or image interpretation does not parallel your findings or if I can be of any further assistance please contact me.

**Eric Lindquist, DMV, DABVP, Cert. IVUSS, CEO of SonoPath.com**

[info@SonoPath.com](mailto:info@SonoPath.com)