



PATIENT

Lucy Husni

PRESENTING CLINICAL SIGNS

increased intermittent RR open mouth breathes then resolves Abnormal Pro BNP

SPECIES

Feline

ULTRASONOGRAPHIC EXAMINATION OF THE HEART

BREED

DSH

SEX

Spayed Female

AGE

8 Years

WEIGHT

11 Pounds

FELINE CARDIAC PARAMETERS	BODY WEIGHT (kg)	HR (BPM)	IVSd (cm)	LVIDd (cm)	LVWd (cm)	FS (%)	EF (%)
NORMAL PARAMETER	-----	150-240	0.3-0.6	1.0-2.1	0.25-0.6	35-67	80-100
PATIENT		NM	0.5	2.0	0.5	30	
FELINE CARDIAC PARAMETERS	LA/AO (Boon)	LA/AO HEART BASE (Sisson)	LA 2D 4-chamber long axis AS to FW (Sisson) (cm)		LVOT VEL. (m/s)	RVOT VEL. (m/s)	IVRT (m/)
NORMAL PARAMETER	<1.5	0.88-1.79	0.7-1.7		<1.6	<1.3	40-60
PATIENT	2.0		1.68			0.46	NM

Adapted from June Boon, Veterinary Echocardiography, 1998
Sisson D et al. JVIM 1991; 5: 232, Jacobs et al. Am J Vet Res 1985; 46:1705

Cardiac Presentation

The cardiac presentation revealed bilateral atrial enlargement. Septal and free wall thicknesses were normal, yet contractility was subnormal. Left- and right-sided hear failure present with valvular insufficiency of the mitral and tricuspid valve. Hepatic vein dilation was present. B-lines noted in the peripheral lung fields, consistent with pulmonary edema and/or consolidation.

ULTRASONOGRAPHIC FINDINGS

- Unclassified cardiomyopathy with left- and right-sided heart failure

INTERPRETATION OF THE FINDINGS & FURTHER RECOMMENDATIONS

Triple therapy warranted in this patient – Lasix 12.5 mg BID progressing to SID depending upon basal respiratory rate. ACE inhibitor 0.5 mg/kg SID, Pimobendan off-label 0.3 mg/kg BID, and Plavix therapy. Recheck echo in one week. Guarded prognosis. This patient is at risk for sudden death.

INTERPRETED BY

Eric Lindquist, DMV

DABVP, Cert. IVUSS

IMAGING PERFORMED BY

Jenn

HOSPITAL NAME

Rockaway AH

REFERRING VET

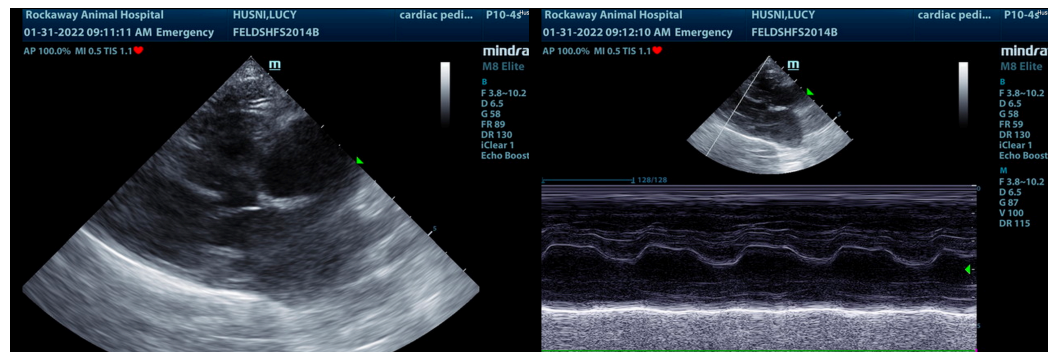
Dr. Maniar

INVOICE

35201

DATE

1/30/22





PATIENT

Lucy Husni

SPECIES

Feline

BREED

DSH

SEX

Spayed Female

AGE

8 Years

WEIGHT

11 Pounds

INTERPRETED BY

Eric Lindquist, DMV

DABVP, Cert. IVUSS

IMAGING PERFORMED BY

Jenn

HOSPITAL NAME

Rockaway AH

REFERRING VET

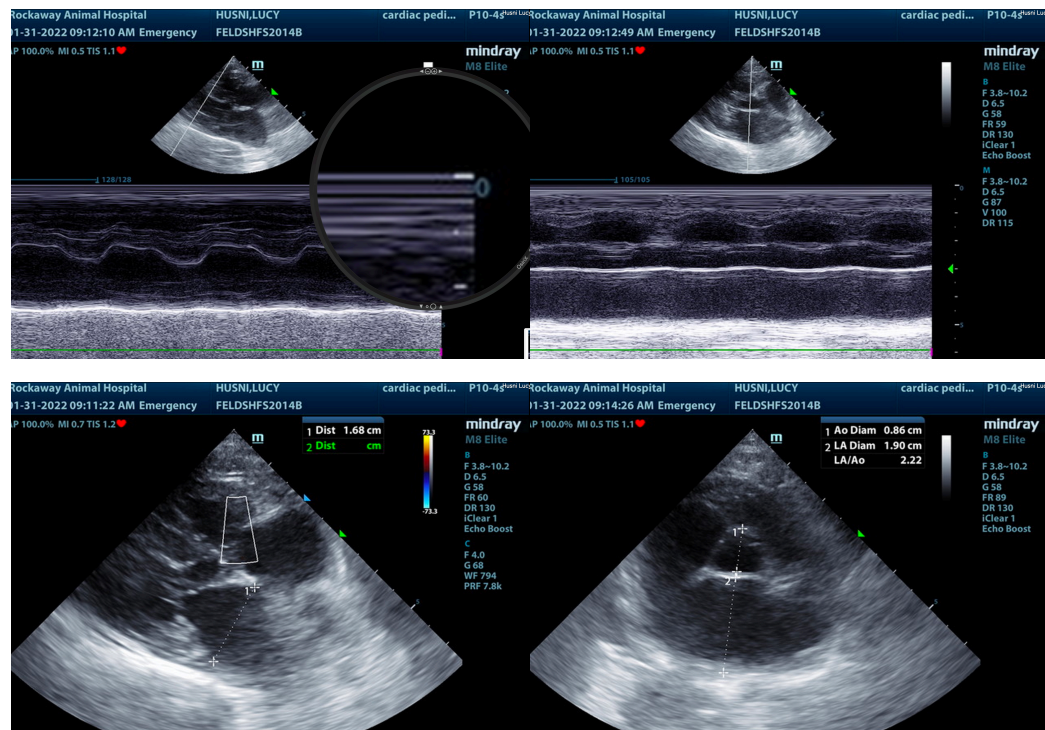
Dr. Maniar

INVOICE

35201

DATE

1/30/22



The information and recommendations provided are based on the images presented by the referring veterinarian/sonographer. No evaluation can be communicated regarding pathology that was not visible in the image/video clips provided.

Thank you for this referral. If the clinical or image interpretation does not parallel your findings or if I can be of any further assistance please contact me.

Eric Lindquist, DMV, DABVP, Cert. IVUSS, CEO of SonoPath.com

info@SonoPath.com