



PATIENT PRESENTING CLINICAL SIGNS

Jojo Ahmed Pre-sx cardiac workup of dental, grade IV/VI murmur. No current meds.
Abnormal PE/Chem/CBC/UA Results: USG 1.038

SPECIES BREED **ULTRASONOGRAPHIC EXAMINATION OF THE HEART**

Canine

BREED

Maltese

SEX

Neutered male

AGE

11 years

WEIGHT

The echocardiogram in this patient demonstrated normal **left atrial** size based on 3 different LA measurement methods. Chamber volumes and echogenicity were normal. The cranial and caudal **mitral** valve leaflets presented vegetative thickening consistent with endocardiosis. Prolapse of the anterior mitral valve leaflet was present, yet volumes are compensated. Doppler indicated measurable insufficiency. The **left ventricle** presented thicknesses with linear contour and was not dilated nor restricted. The **myocardium** presented normal echogenicity without subjective evidence of significant fibrotic or ischemic disease. **Contractility** of the ventricular walls was adequate and in normal range for this patient evidenced by the fractional shortening measurement and subjective evaluation of the different regions of the myocardium. The **left ventricular outflow** tract demonstrated normal laminar flow and subjective structural integrity. The **right atrium** and auricle revealed normal size, structure and content. No evidence of masses was noted or chamber overload. **Tricuspid** valvular assessment demonstrated adequate linear morphology. The **right ventricle** was of normal size (1/3 diameter of LV), chordae structure, myocardial echogenicity and thickness. **Pulmonic** tract assessment revealed normal valve structure, laminar flow, and diameter (approx. 1:1 pa/ao ratio). No visible **pericardial** or free pleura fluid was noted. No echographically detectable evidence of infiltrative disease was visible. The cranial **mediastinum and pericardial regions** were free of masses in the visible window.

INTERPRETED BY

Eric Lindquist, DMV
DABVP, Cert. IVUSS

IMAGING PERFORMED BY

Shari Reffi, CVT

HOSPITAL NAME

BPH Bridgewater

REFERRING VET

Dr. Baker

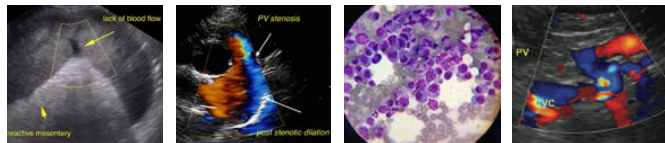
CANINE CARDIAC PARAMETERS	MR VMAX (m/s)	TR VMAX (m/s)	LA/AO (Boon method)	LA/AO (Heart Base; Swe)	FS (%)	EF (%)	EPSS (cm)
NORMAL PARAMETER	4.5-5.5	<2.7	1.3	<1.6	28-40	40-100	<0.6
PATIENT	6.0	2.18	1.36	1.36	37	68	0.1
CANINE CARDIAC PARAMETERS	HR (BPM)	AV VMAX (m/s)	PV MAX (m/s)	BODY WEIGHT	LA (2D short axis Base view) (cm)	LVIDd (Avg; 2D and m-mode short axis) (cm)	LVIDs (Avg; 2D and m-mode short axis) (cm)
NORMAL PARAMETER	50-100	0.7-1.7	0.7-1.6				
PATIENT	100	1.16	0.71		2.95 max	3.2	

INVOICE ULTRASONOGRAPHIC FINDINGS

95649 Stage B1 valvular disease, compensated.

DATE

1/31/22



PATIENT

Jojo Ahmed

SPECIES

Canine

BREED

Maltese

SEX

Neutered male

AGE

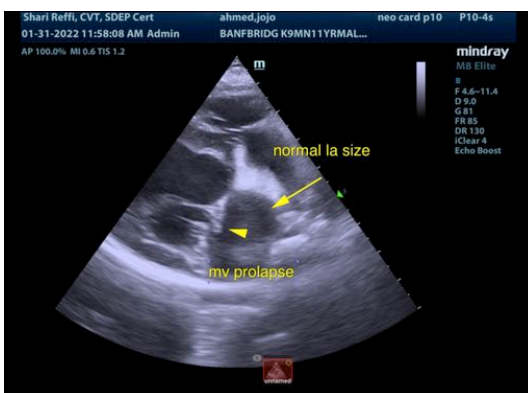
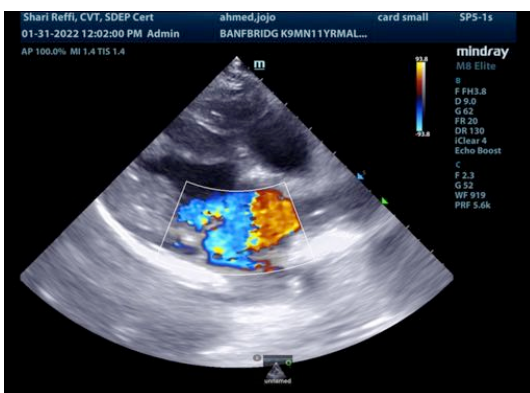
11 years

WEIGHT

INTERPRETATION OF THE FINDINGS & FURTHER RECOMMENDATIONS

The only concern in this patient is mitral valve prolapse. No treatment is recommended at this time as there is no significant volume overload; however, this murmur grade should be monitored carefully and minimal time under anesthesia should be targeted.

B1: The heart is stable without clinical disease. No overt contraindication for anesthesia of brief to moderate duration. I suggest Torbutrol premed, Propofol induction, Isoflurane maintenance or similar protocol if anesthesia is desired. Blood pressure recommended if not already performed and target white coat negative systolic pressure of < 160 mmHg. If higher than this ACE-inhibitor is suggested to reach this level. Recheck echocardiogram is recommended in 6 months, earlier if murmur grade increases or clinical signs initiate.



INTERPRETED BY

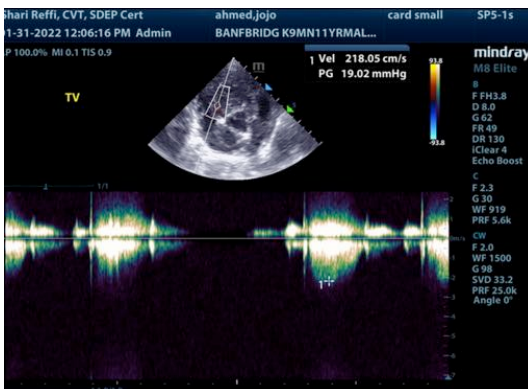
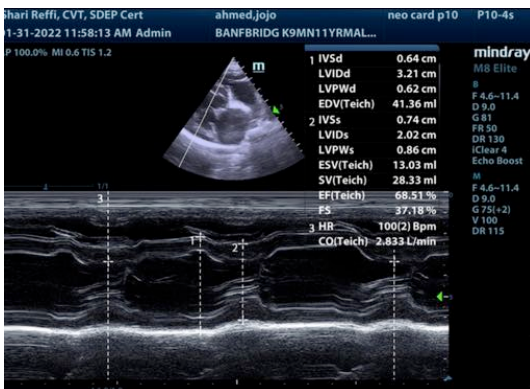
Eric Lindquist, DMV
DABVP, Cert. IVUSS

IMAGING PERFORMED BY

Shari Reffi, CVT

HOSPITAL NAME

BPH Bridgewater



REFERRING VET

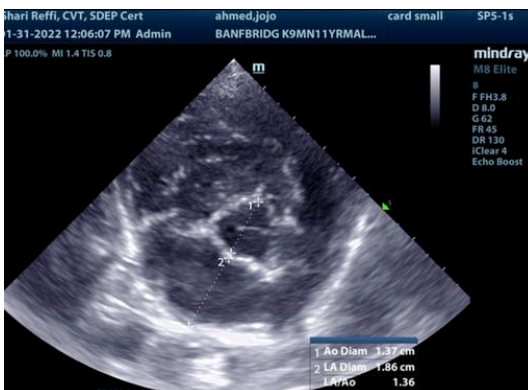
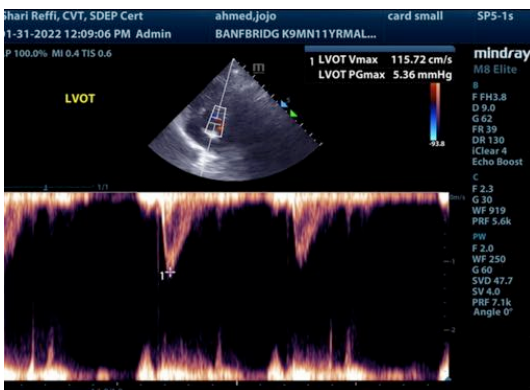
Dr. Baker

INVOICE

95649

DATE

1/31/22





PATIENT

Jojo Ahmed

SPECIES

Canine

BREED

Maltese

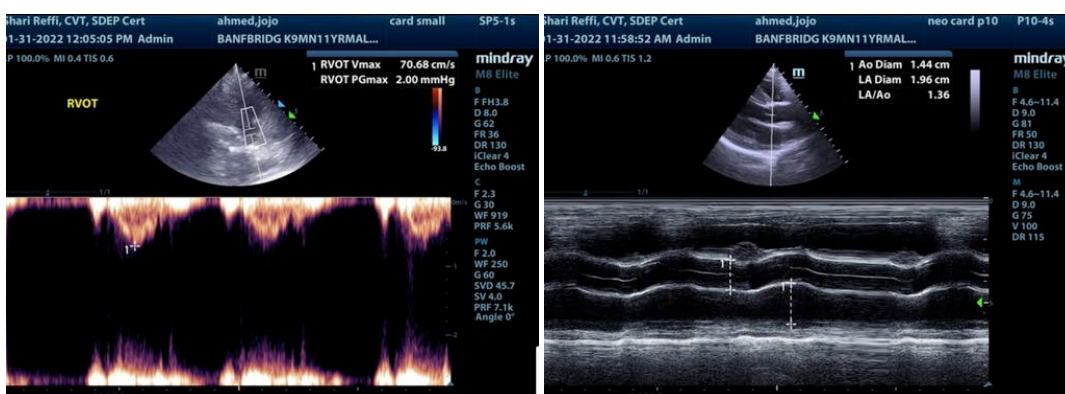
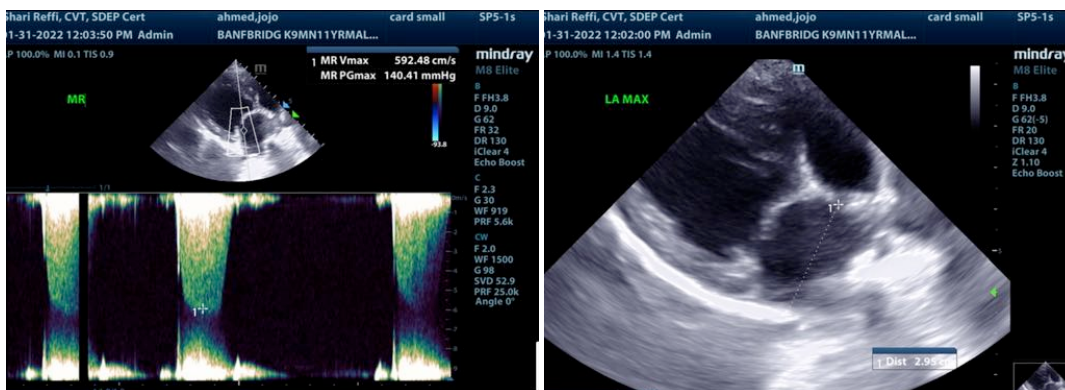
SEX

Neutered male

AGE

11 years

WEIGHT



INTERPRETED BY

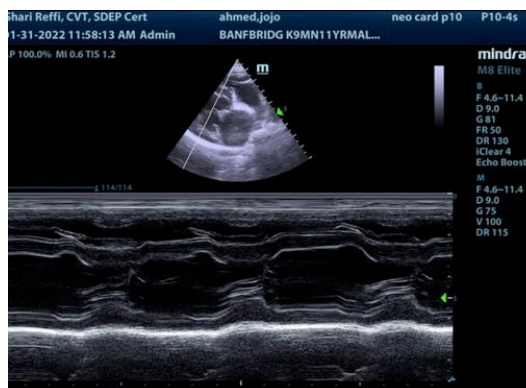
Eric Lindquist, DMV
DABVP, Cert. IVUSS

IMAGING PERFORMED BY

Shari Reffi, CVT

HOSPITAL NAME

BPH Bridgewater



REFERRING VET

Dr. Baker

INVOICE

95649

DATE

1/31/22

The information and recommendations provided are based on the images presented by the referring veterinarian/sonographer. No evaluation can be communicated regarding pathology that was not visible in the image/video clips provided.

Thank you for this referral. If the clinical or image interpretation does not parallel your findings or if I can be of any further assistance please contact me.

Eric Lindquist, DMV, DABVP, Cert. IVUSS, CEO of SonoPath.com
Info@SonoPath.com