


**PATIENT**

Hope Meudt

**PRESENTING CLINICAL SIGNS**

lethargic, not drinking as much seems to be doing a little better lately

**SPECIES**

Canine

**ULTRASONOGRAPHIC EXAMINATION OF THE HEART & ABDOMEN**
**BREED**

Chihuahua

CANINE CARDIAC PARAMETERS	MR VMAX (m/s)	TR VMAX (m/s)	LA/AO (Boon method)	LA/AO (Heart Base; Swe)	FS (%)	EF (%)	EPSS (cm)
NORMAL PARAMETER	4.5-5.5	<2.7	1.3	<1.6	28-40	40-100	<0.6
PATIENT			1.2	1.0	61	92	0.1
CANINE CARDIAC PARAMETERS	HR (BPM)	AV VMAX (m/s)	PV MAX (m/s)	BODY WEIGHT (kg)	LA 2D short axis Base view (cm)	LVIDd Avg; 2D and m-mode short axis (cm)	LVIDs Avg; 2D and m-mode short axis (cm)
NORMAL PARAMETER	50-100	0.7-1.7	0.7-1.6				
PATIENT		1.5	1.1			2.07	

**SEX**

Spayed Female

**AGE**

11 Years

**WEIGHT**

8.8 Pounds

**Cardiac Presentation**

The echocardiogram in this patient demonstrated normal **left atrial** size based on 3 separate methods of LA evaluation. The cranial and caudal **mitral** valve leaflets presented normal linear structure, extension in systole, and union in diastole with normal kinesis. The **left ventricle** presented thicknesses with linear contour and was not dilated nor restricted. The **myocardium** presented normal echogenicity without subjective evidence of significant fibrotic or ischemic disease. **Contractility** of the ventricular walls was adequate and in normal range for this patient evidenced by the fractional shortening measurement and subjective evaluation of the different regions of the myocardium. The **left ventricular outflow** tract demonstrated normal laminar flow and subjective structural integrity. The **right atrium** and auricle revealed normal size, structure and content. No evidence of masses was noted. **Tricuspid** valvular assessment demonstrated adequate linear morphology and kinesis. The **right ventricle** was of normal size (1/3 diameter of LV), chordae structure, myocardial echogenicity and thickness. **Pulmonary outflow** tract assessment revealed normal valve structure, laminar flow, and diameter (approx. 1:1 pa/ao ratio). No visible **pericardial** or free pleura fluid was noted. The cranial **mediastinum and pericardial and extra-cardiac regions** were free of masses in the visible window.

**INTERPRETED BY**

Eric Lindquist, DMV

DABVP, Cert. IVUSS

**IMAGING PERFORMED BY**

Jenn

**HOSPITAL NAME**

Rockaway AH

**REFERRING VET**

Dr. Maniar

**Urinary System**

The **urinary bladder**, trigone, and pelvic urethra presented normal thicknesses and normal tone. The ureters were not visible which is normal. No uroliths or sediment were visualized and anechoic urine was present. No evidence of inflammatory or neoplastic changes were noted. Ureteral papillae were normal.

**INVOICE**

35209

**DATE**

1/31/22

The **kidneys** revealed normal size and structure, corticomedullary definition and ratio for this age. The cortices presented largely uniform texture with normal echogenic relationship to liver and spleen. Medullary structure differed distinctly from the cortex and no evidence of pelvic dilation was present.



**PATIENT**

Hope Meudt

The capsules were acceptably uniform without significant irregularities. The right kidney measured 4.2 cm. The left kidney measured 3.42 cm.

**Adrenal Glands**

**SPECIES**

Canine

The regions of the **adrenal glands** were unremarkable.

**Spleen**

**BREED**

Chihuahua

The **spleen** presented a smooth homogeneous parenchyma hyperechoic to liver and renal cortical parenchyma. The capsule was smooth without noticeable expansion or deviation from within the spleen or adjacent pathology. The splenic vasculature demonstrated normal volume without signs of congestion or thrombosis. No sonographic evidence of acute or chronic inflammatory, neoplastic, or infarctual changes were noted.

**SEX**

Spayed Female

**Liver**

**AGE**

11 Years

The **liver** images submitted revealed subjectively normal liver size, contour, and structure. Parenchymal echogenicity was naturally coarse and hypoechoic to the spleen. Vascular and biliary tracts were of normal volume with no evidence of congestion. The gallbladder presented acceptably thin walls with primarily anechoic content. The cystic and common bile ducts were normal. No pathological hepatic lymphadenopathy was evident. No overt structural evidence of inflammatory, infiltrative or regenerative pathology was evident.

**WEIGHT**

8.8 Pounds

**Gastrointestinal**

Some retention of ingesta was noted in the **stomach**. Some of the material in the stomach appeared to be shadowing, yet most consistent with post-prandial kibble. The small intestine and colon were unremarkable.

**INTERPRETED BY**

Eric Lindquist, DMV

**Pancreas**

DABVP, Cert. IVUSS

The base and limbs of the **pancreas** were observed to be largely isoechoic to surrounding omental fat. Pancreatic duct and capsular contour were acceptably normal and parenchyma respected normal curvilinear patterns. No overt evidence of active inflammatory or neoplastic disease was noted.

**IMAGING PERFORMED BY**

Jenn

**ULTRASONOGRAPHIC FINDINGS**

- Normal echocardiogram
- Gastric retention of ingesta

**HOSPITAL NAME**

Rockaway AH

**INTERPRETATION OF THE FINDINGS & FURTHER RECOMMENDATIONS**

No evidence of cardiac disease influencing the clinical signs.

**REFERRING VET**

Dr. Maniar

No evidence of abdominal visceral disease responsible for the clinical signs. CNS, orthopedic or thoracic disease should all be considered.

**INVOICE**

35209

**DATE**

1/31/22



**PATIENT**

Hope Meudt

**SPECIES**

Canine

**BREED**

Chihuahua

**SEX**

Spayed Female

**AGE**

11 Years

**WEIGHT**

8.8 Pounds

**INTERPRETED BY**

Eric Lindquist, DMV

DABVP, Cert. IVUSS

**IMAGING PERFORMED BY**

Jenn

**HOSPITAL NAME**

Rockway AH

**REFERRING VET**

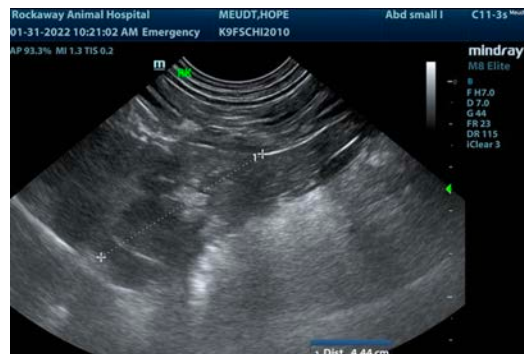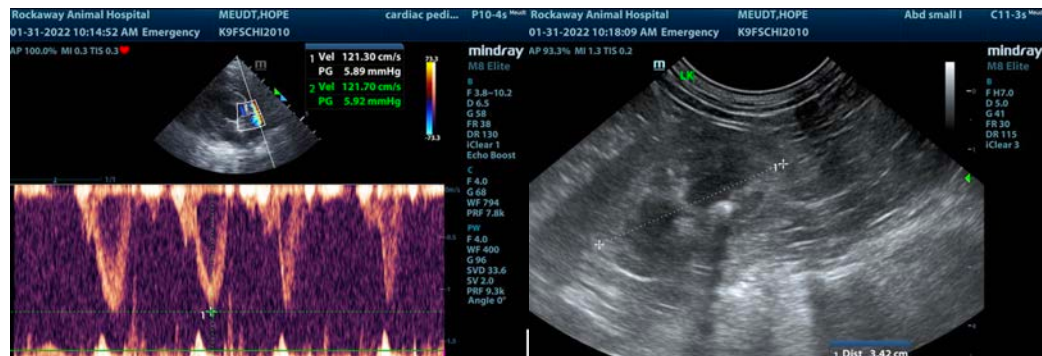
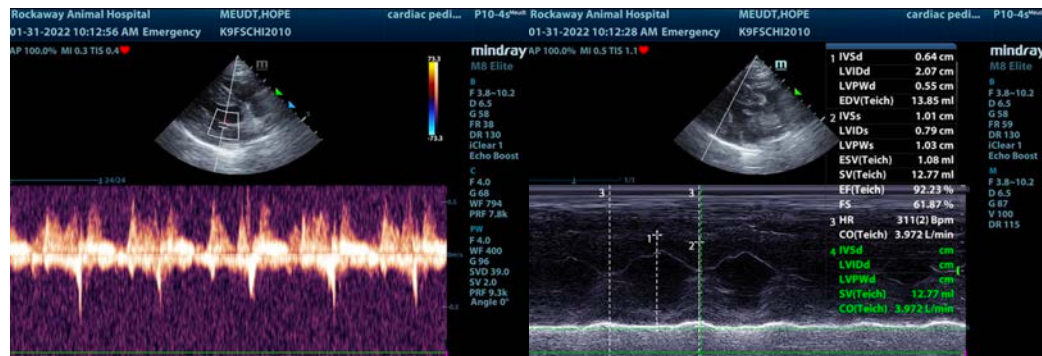
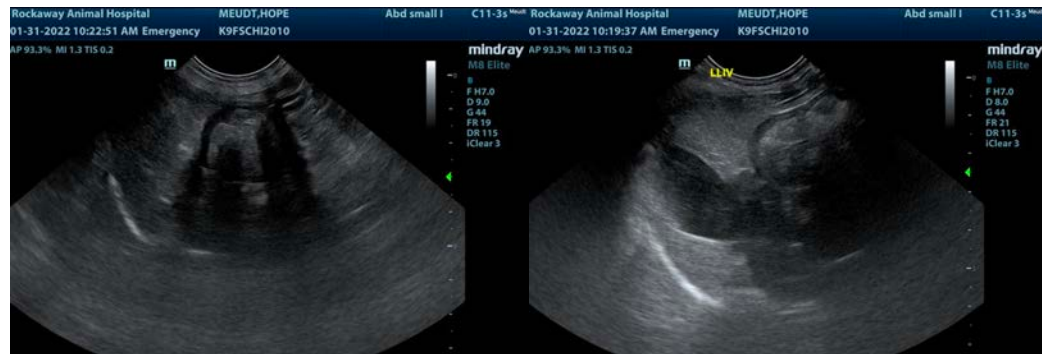
Dr. Maniar

**INVOICE**

35209

**DATE**

1/31/22





**PATIENT**

Hope Meudt

The information and recommendations provided are based on the images presented by the referring veterinarian/sonographer. No evaluation can be communicated regarding pathology that was not visible in the image/video clips provided.

**SPECIES**

Canine

Thank you for this referral. If the clinical or image interpretation does not parallel your findings or if I can be of any further assistance please contact me.

**Eric Lindquist**, DMV, DABVP, Cert. IVUSS, CEO of SonoPath.com

[info@SonoPath.com](mailto:info@SonoPath.com)

**BREED**

Chihuahua

**SEX**

Spayed Female

**AGE**

11 Years

**WEIGHT**

8.8 Pounds

**INTERPRETED BY**

Eric Lindquist, DMV

DABVP, Cert. IVUSS

**IMAGING PERFORMED BY**

Jenn

**HOSPITAL NAME**

Rockaway AH

**REFERRING VET**

Dr. Maniar

**INVOICE**

35209

**DATE**

1/31/22