



**DATE PRESENTING CLINICAL SIGNS**

01/30/26 Patient History: Routine annual - performed BW to reveal continued ALP elevation, USG 1.022, +1 proteinuria, occasional fine granular casts

**PATIENT**

Steffie Durishin Current Medications: Hydroxyzine 25mg 1 BID, Heartgard + monthly  
Labwork Results: Labwork attached, reported as: ALP 484 (prev 200 in March 2025), USG 1.022, +1 proteinuria, occasional fine granular casts  
Date of Previous IntraPet Ultrasound: No previous.

**SPECIES**

Canine Sedation: Not required to complete full diagnostic ultrasound.  
Stat Report: Not requested.  
Imaging Performed by: Rachel Brillhart, RDMS.

**BREED**

**ULTRASONOGRAPHIC EXAMINATION OF THE ABDOMEN**

Jack Russell Mix

**Urinary System**

**SEX**

Spayed Female The **urinary bladder**, trigone, and pelvic urethra presented normal thicknesses and normal tone. The ureters were not visible which is normal. No uroliths or sediment were visualized, and anechoic urine was present. No evidence of inflammatory or neoplastic changes were noted. Ureteral papillae were normal.

**AGE**

9/7/2013 The **kidneys** revealed largely normal size and structure, corticomedullary definition and ratio (cortex 1/3 of medulla) were essentially maintained with some moderate age-related loss of curvilinear patterns regarding the capsule and C/M junction. The cortices presented largely uniform texture with some increased echogenicity expected for his age patient. Medullary structure differed distinctly from that of the cortex. Hyperechoic mineralized medullary rim was noted. The left kidney measured 4.3 cm in length. The right kidney measured 4.62 cm in length.

**WEIGHT**

21.4 pounds

**Adrenal Glands**

**INTERPRETED BY**

Eric Lindquist, DMV, DABVP(CFM), Cert. IVUSS The **left adrenal gland** was visualized and recognized as having normal shape, size, position and echogenicity for this breed. The phrenic vasculature, glandular echogenicity and detail were unremarkable. Capsule, cortex, and medullary definition were normal for this age patient. The left adrenal gland measured 2.37 cm x 0.60 cm width at the caudal pole and 0.59 cm width at the cranial pole.

**HOSPITAL NAME**

Chadwell Animal Hospital The **right adrenal gland** presented with a hyperechoic nodule measuring 0.90 cm x 0.877 cm in the cranial pole. The right adrenal gland measured 1.87 cm x 0.73 cm width at the cranial pole and 0.54 cm width at the caudal pole.

**Spleen**

**REFERRING VET**

Dr. Oliveri The **spleen** presented a smooth homogeneous parenchyma hyperechoic to liver and renal cortical parenchyma. The capsule was smooth without noticeable expansion or deviation from within the spleen or adjacent pathology. The splenic vasculature demonstrated normal volume without signs of congestion or thrombosis. No sonographic evidence of acute or chronic inflammatory, neoplastic, or infarctual changes were noted.

**INVOICE**

13488

**Liver**

The **liver** images from right and left intercostal as well as subcostal views revealed subjectively normal liver size, contour, and structure. Some moderate age-related parenchymal remodeling was noted but likely not

clinically significant at this time. Vascular and biliary tracts were of normal volume and no evidence of congestion was noted. The gallbladder presented some dependent debris with essentially normal contour. The cystic and common bile ducts were normal. No overt evidence of active inflammatory, infiltrative or regenerative pathology was noted but should be paired with current or past LE elevations regarding any clinical significance to this presentation. The hepatic lymph nodes were unremarkable.

### **Gastrointestinal**

Examination of the **gastrointestinal tract** revealed a stomach and intestine free of stasis, of normal wall thickness, acceptable curvilinear mural detail, and peristaltic activity. Small and large intestine demonstrated normal luminal chyme and stool consistency respectively. No obstructive or overt infiltrative disease was noted. No associated abnormal lymphatic activity was noted.

### **Pancreas**

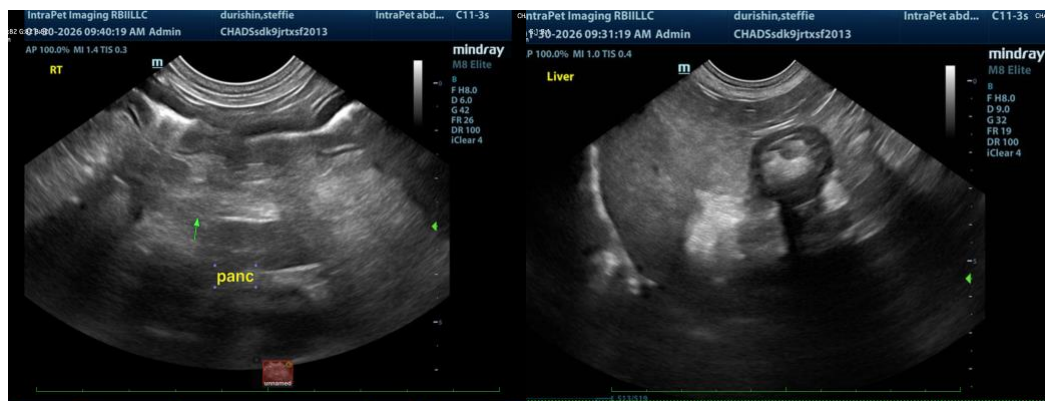
The base and limbs of the **pancreas** were observed to be largely isoechoic to surrounding omental fat. Pancreatic duct and capsular contour were acceptably normal and parenchyma respected normal curvilinear patterns. No overt evidence of active inflammatory or neoplastic disease was noted.

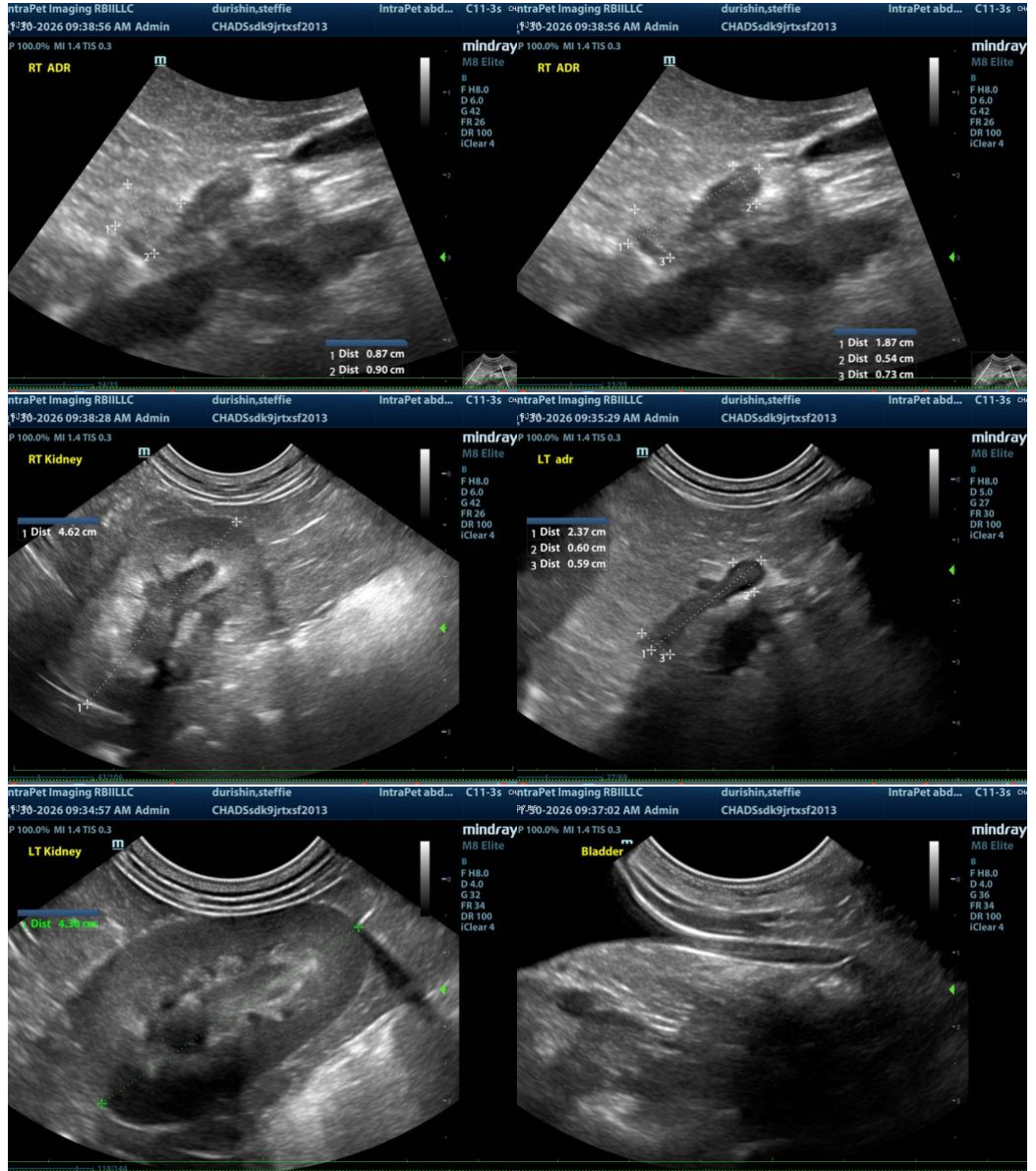
### **ULTRASONOGRAPHIC FINDINGS**

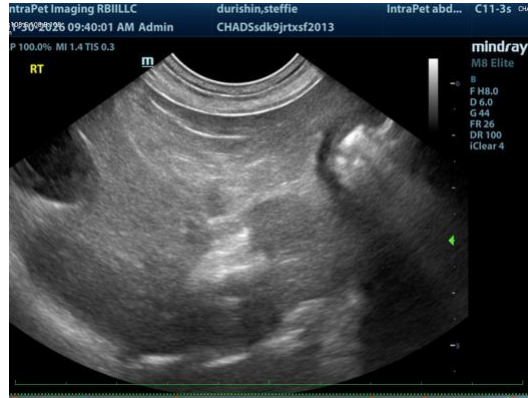- Medullary rim mineralization in both kidneys- degenerative change.
- Benign hepatopathy.
- Right adrenal nodule- likely hyperplasia.

### **INTERPRETATION OF THE FINDINGS & FURTHER RECOMMENDATIONS**

Recheck sonogram in 4-6 weeks or earlier if any clinical signs of Cushing's disease or hypertension are present. Urinalysis is warranted if not already performed to assess for any significant proteinuria that may be related to the medullary rim sign, however, the abdomen all in all appears to be largely geriatric and common for this patient's breed and age.







The information and recommendations provided are based on the images presented by the referring veterinarian/sonographer. No evaluation can be communicated regarding pathology that was not visible in the image/video clips provided.

Thank you for this referral. If the clinical or image interpretation does not parallel your findings or if I can be of any further assistance, please contact me.

**Eric Lindquist, DMV, DABVP(CFM), Cert. IVUSS,**

CEO, Owner, Founder -- SonoPath.com

[info@SonoPath.com](mailto:info@SonoPath.com)