



**PATIENT**

Nala Todaro

**SPECIES**

Canine

**BREED**

Cavalier King Charles  
Spaniel

**SEX**

Spayed Female

**AGE**

10 Years 6 Months

**WEIGHT**

19.8 lbs

**PRESENTING CLINICAL SIGNS**

Cardiac Workup. ECG: Sinus Rhythm and Sinus Arrhythmia consistent with 2nd Degree AV Block

**ULTRASONOGRAPHIC EXAMINATION OF THE HEART**

<b>CANINE CARDIAC PARAMETERS</b>	<b>MR VMAX (m/s)</b>	<b>TR VMAX (m/s)</b>	<b>LA/AO (M-Mode)</b>	<b>LA/AO (Heart Base; Swe)</b>	<b>FS (%)</b>	<b>EF (%)</b>	<b>EPSS (cm)</b>
<b>NORMAL PARAMETER</b>	4.5-5.5	<2.7	1.3	Up to 1.6	28-40	40-100	<0.6
<b>PATIENT</b>	6.3	2.8	1.3	1.4	45	85	0.1
<b>CANINE CARDIAC PARAMETERS</b>	<b>HR (BPM)</b>	<b>AV VMAX (m/s)</b>	<b>PV MAX (m/s)</b>	<b>BODY WEIGHT (lbs)</b>	<b>LAD LA MAX 4 Chamber</b>	<b>LVIDd Avg; 2D and m-mode short axis (cm)</b>	<b>LVIDs Avg; 2D and m-mode short axis (cm)</b>
<b>NORMAL PARAMETER</b>	50-100	0.7-1.7	0.7-1.6				
<b>PATIENT</b>	90	1.3	0.9	19.8	3.0	2.5	--

**INTERPRETED BY**

Eric Lindquist, DMV,  
DABVP (CFM), Cert.  
IVUS

**IMAGING PERFORMED BY**

Vincent Ravancho, CVT

**HOSPITAL NAME**

Brenda King, VMD

**REFERRING VET**

Brenda King, VMD

**INVOICE**

72652

**DATE**

1/30/26

**Cardiac Presentation**

The echocardiogram in this patient demonstrated normal **left atrial** size based on 3 different LA measurement methods. Chamber volumes and echogenicity were normal. The cranial and caudal **mitral** valve leaflets presented vegetative thickening consistent with endocardiosis. Doppler indicated measurable insufficiency. The **left ventricle** presented thicknesses with linear contour and was not dilated nor restricted. The **myocardium** presented normal echogenicity without subjective evidence of significant fibrotic or ischemic disease. **Contractility** of the ventricular walls was adequate and in normal range for this patient evidenced by the fractional shortening measurement and subjective evaluation of the different regions of the myocardium. The **left ventricular outflow** tract demonstrated normal laminar flow and subjective structural integrity. The **right atrium** and auricle revealed normal size, structure and content. No evidence of masses was noted or chamber overload. **Tricuspid** insufficiency also noted. The **right ventricle** was of normal size (1/3 diameter of LV), chordae structure, myocardial echogenicity and thickness. **Pulmonic** tract assessment revealed normal valve structure, laminar flow, and diameter (approx. 1:1 pa/ao ratio). No visible **pericardial** or free pleura fluid was noted. No echographically detectable evidence of infiltrative disease was visible. The cranial **mediastinum and pericardial regions** were free of masses in the visible window.

**ULTRASONOGRAPHIC FINDINGS**

- Stage B1 valvular disease.

**INTERPRETATION OF THE FINDINGS & FURTHER RECOMMENDATIONS**

The heart is stable without clinical disease. No arrhythmogenic activity noted during the exam. No overt contraindication for anesthesia of brief to moderate duration. I suggest Torbutrol premed, Propofol induction, Isoflo maintenance or similar protocol if anesthesia is desired. Blood pressure, EKG and chest



**PATIENT**

Nala Todaro

**SPECIES**

Canine

**BREED**

Cavalier King Charles  
 Spaniel

**SEX**

Spayed Female

**AGE**

10 Years 6 Months

**WEIGHT**

19.8 lbs

**INTERPRETED BY**

Eric Lindquist, DMV,  
 DABVP (CFM), Cert.  
 IVUSS

**IMAGING  
 PERFORMED BY**

Vincent Ravancho, CVT

**HOSPITAL NAME**

Brenda King, VMD

**REFERRING VET**

Brenda King, VMD

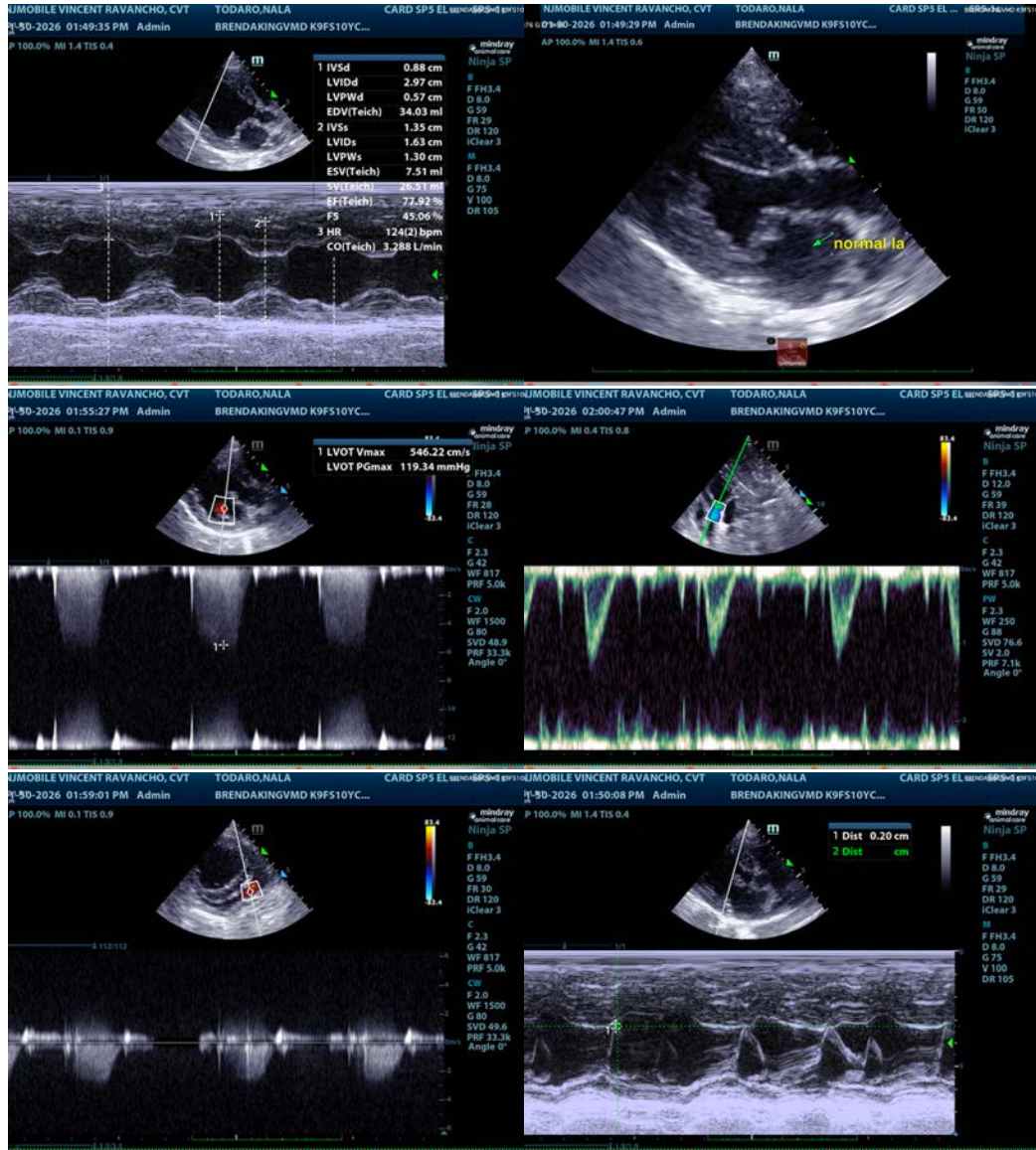
**INVOICE**

72652

**DATE**

1/30/26

radiographs are recommended if not already performed. Target white coat negative systolic pressure of < 160 mmHg. If higher than this ACE-inhibitor is suggested to reach this level. Recheck echocardiogram is recommended in 6 months, earlier if murmur grade increases or clinical signs initiate.





**PATIENT**

Nala Todaro

**SPECIES**

Canine

**BREED**

Cavalier King Charles  
Spaniel

**SEX**

Spayed Female

**AGE**

10 Years 6 Months

**WEIGHT**

19.8 lbs

**INTERPRETED BY**

Eric Lindquist, DMV,  
DABVP (CFM), Cert.  
IVUSS

**IMAGING  
PERFORMED BY**

Vincent Ravancho, CVT

**HOSPITAL NAME**

Brenda King, VMD

**REFERRING VET**

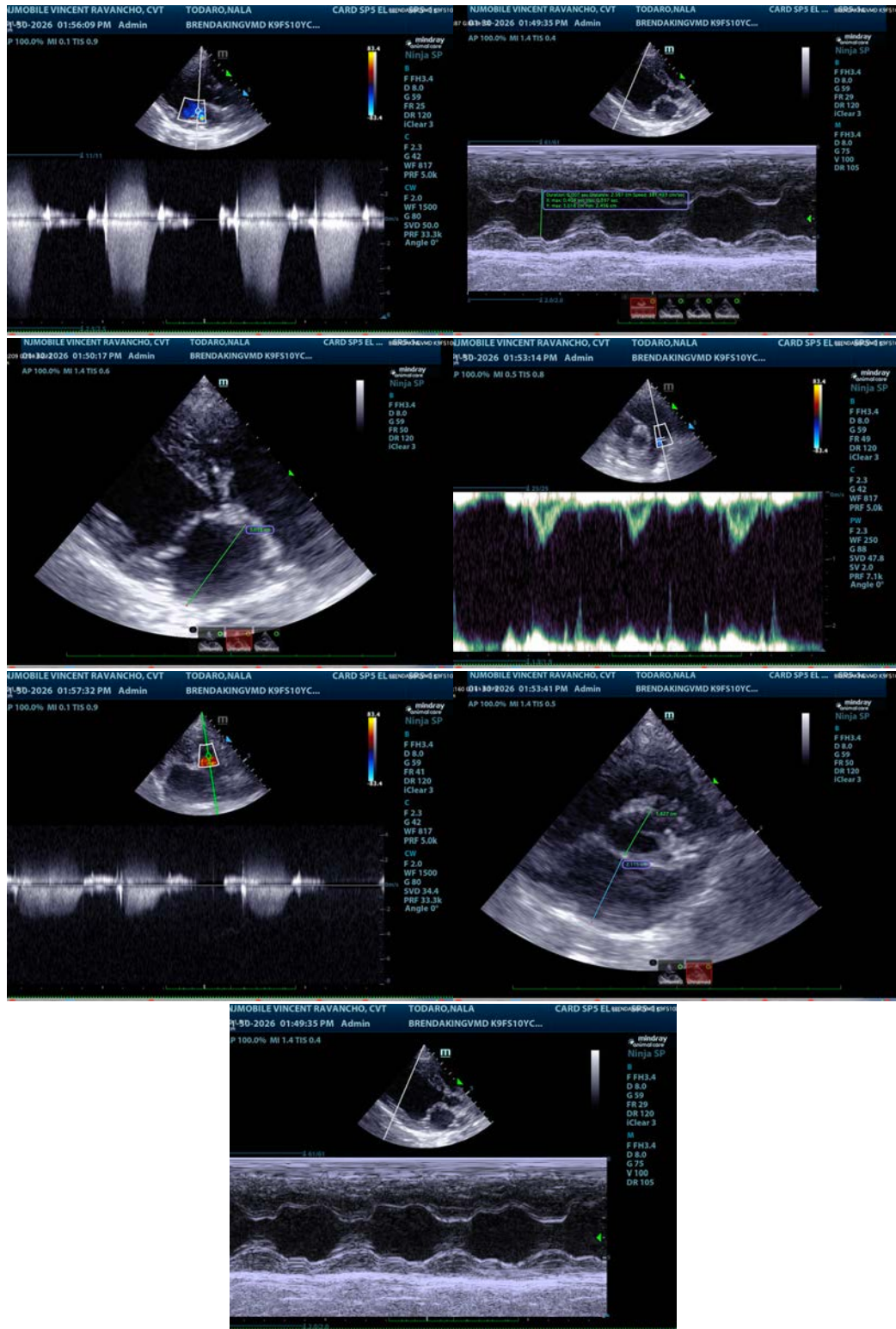
Brenda King, VMD

**INVOICE**

72652

**DATE**

1/30/26





**PATIENT**

Nala Todaro

**SPECIES**

Canine

**BREED**

Cavalier King Charles  
Spaniel

**SEX**

Spayed Female

**AGE**

10 Years 6 Months

**WEIGHT**

19.8 lbs

**INTERPRETED BY**

Eric Lindquist, DMV,  
DABVP (CFM), Cert.  
IVUSS

**IMAGING  
PERFORMED BY**

Vincent Ravancho, CVT

**HOSPITAL NAME**

Brenda King, VMD

**REFERRING VET**

Brenda King, VMD

**INVOICE**

72652

**DATE**

1/30/26

The information and recommendations provided are based on the images presented by the referring veterinarian/sonographer. No evaluation can be communicated regarding pathology that was not visible in the image/video clips provided.

Thank you for this referral. If the clinical or image interpretation does not parallel your findings or if I can be of any further assistance please contact me.

**Eric Lindquist**, DMV, DABVP(CFM), Cert. IVUSS,  
CEO, Owner, Founder -- SonoPath.com  
[info@SonoPath.com](mailto:info@SonoPath.com)