



PATIENT

Logan Williams

SPECIES

Canine

BREED

Maltese

SEX

Neutered Male

AGE

4

WEIGHT

11 lbs

INTERPRETED BY

Eric Lindquist, DMV,
DABVP (CFM), Cert.
IVUSS

IMAGING PERFORMED BY

Kevin Moon, DVM

HOSPITAL NAME

Shiloh Veterinary
Hospital

REFERRING VET

Colleen Andrews, DVM

INVOICE

72637

DATE

1/30/26

PRESENTING CLINICAL SIGNS

Vomiting multiple times a week for 1 month with 4 lbs of weight loss. Vomiting has stopped with Cerenia.

Hyporexic for 1 month- anorexic for 3 days.

ULTRASONOGRAPHIC EXAMINATION OF THE ABDOMEN

Urinary System

The **urinary bladder**, trigone, and pelvic urethra presented normal thicknesses and normal tone. The ureters were not visible which is normal. No uroliths or sediment were visualized and anechoic urine was present. No evidence of inflammatory or neoplastic changes were noted. Ureteral papillae were normal. The pelvic urethra was imaged 1.0 cm beyond the cystourethral junction.

The **kidneys** revealed normal size and structure, corticomedullary definition and ratio for this age. The cortices presented largely uniform texture with normal echogenic relationship to liver and spleen. Medullary structure differed distinctly from the cortex and no evidence of pelvic dilation was present. The capsules were acceptably uniform without significant irregularities. Left kidney measured 4.0 cm. Right kidney measured 3.5 cm with slight pinpoint mineralizations noted.

Adrenal Glands

The **left adrenal gland** was visualized and recognized as having normal shape, size, position and echogenicity for this breed. The phrenic vasculature, glandular echogenicity and detail were unremarkable. Capsule, cortex, and medullary definition were normal for this age patient. Left measured 0.36 cm.

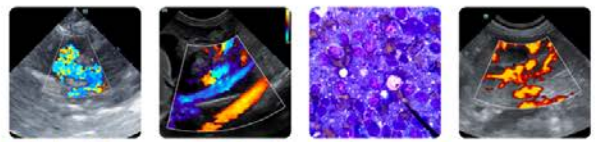
The **right adrenal gland** presented slight areas of mineralization and remodeling, measuring at the upper limits of normal for size at 1.0 cm at the cranial pole and 0.63 cm at the caudal pole.

Spleen

The **spleen** presented a smooth homogeneous parenchyma hyperechoic to liver and renal cortical parenchyma. The capsule was smooth without noticeable expansion or deviation from within the spleen or adjacent pathology. The splenic vasculature demonstrated normal volume without signs of congestion or thrombosis. No sonographic evidence of acute or chronic inflammatory, neoplastic, or infarctual changes were noted.

Liver

The **liver** images submitted revealed subjectively normal liver size, contour, and structure. Parenchymal echogenicity was naturally coarse and hypoechoic to the spleen. Vascular and biliary tracts were of normal volume with no evidence of congestion. The gallbladder presented acceptably thin walls with primarily anechoic content. The cystic and common bile ducts were normal. No pathological hepatic lymphadenopathy was evident. No overt structural evidence of inflammatory, infiltrative or regenerative pathology was evident.



PATIENT

Logan Williams

SPECIES

Canine

BREED

Maltese

SEX

Neutered Male

AGE

4

WEIGHT

11 lbs

INTERPRETED BY

Eric Lindquist, DMV,
DABVP (CFM), Cert.
IVUS

IMAGING PERFORMED BY

Kevin Moon, DVM

HOSPITAL NAME

Shiloh Veterinary
Hospital

REFERRING VET

Colleen Andrews, DVM

INVOICE

72637

DATE

1/30/26

Gastrointestinal

The **stomach** revealed concentric mural thickening with hyperechoic mucosal inclusions, strongly consistent with ulcerative gastritis. Minor amount of anechoic fluid noted in the stomach. The small intestine and colon were unremarkable. Curvilinear patterns were maintained.

Pancreas

The base and limbs of the **pancreas** were observed to be largely isoechoic to surrounding omental fat. Pancreatic duct and capsular contour were acceptably normal and parenchyma respected normal curvilinear patterns. No overt evidence of active inflammatory or neoplastic disease was noted.

ULTRASONOGRAPHIC FINDINGS

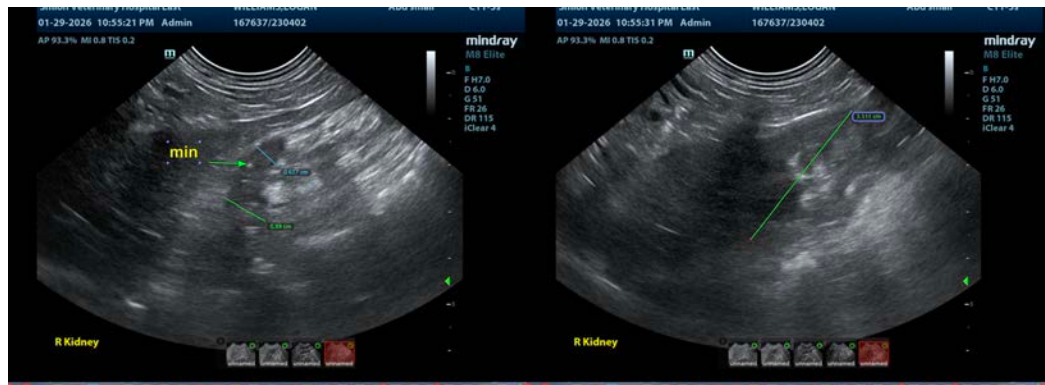
- Gastritis, likely ulcerative in nature.
- Slight dystrophic mineralization of the right adrenal gland.

INTERPRETATION OF THE FINDINGS & FURTHER RECOMMENDATIONS

GI protectant protocol such as the following recommended.

Helicobacter/Gastritis protocol

A clinical trial of **Zithromax** (Dogs: 5-10 mg/kg p.o. q24h. May increase dosing interval to q48h after 3-5 days of treatment), **Metronidazole** (10-20 mg/kg p.o. b.i.d.), **Pepcid** (0.5-1 mg/kg s.i.d.) and **Sucralfate** (0.5-2 g/dog PO) or **Omeprazole** (1 mg/kg p.o. s.i.d.) over the next 3 weeks along with a **novel-protein or hydrolyzed diet** with slurry feeding b.i.d./t.i.d. over the next 2-4 days and then increase to canned diet bid. Dry food should be avoided over the next 4 weeks. A recheck sonogram to assess GI improvement or progression would be ideal in 4 weeks.





PATIENT

Logan Williams

SPECIES

Canine

BREED

Maltese

SEX

Neutered Male

AGE

4

WEIGHT

11 lbs

INTERPRETED BY

Eric Lindquist, DMV,
DABVP (CFM), Cert.
IVUSS

**IMAGING
PERFORMED BY**

Kevin Moon, DVM

HOSPITAL NAME

Shiloh Veterinary
Hospital

REFERRING VET

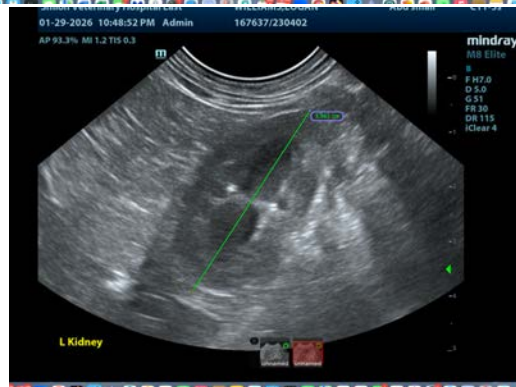
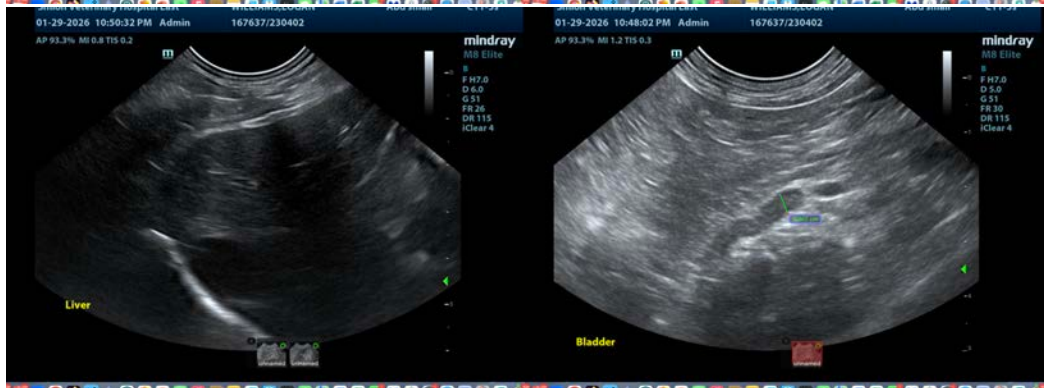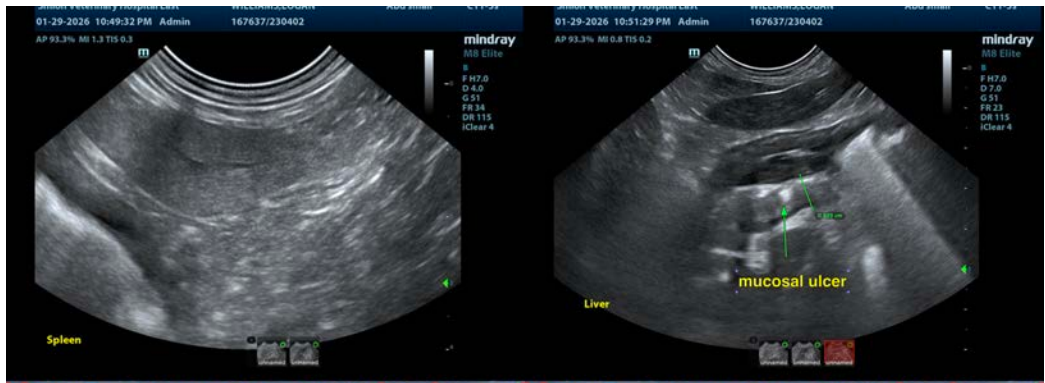
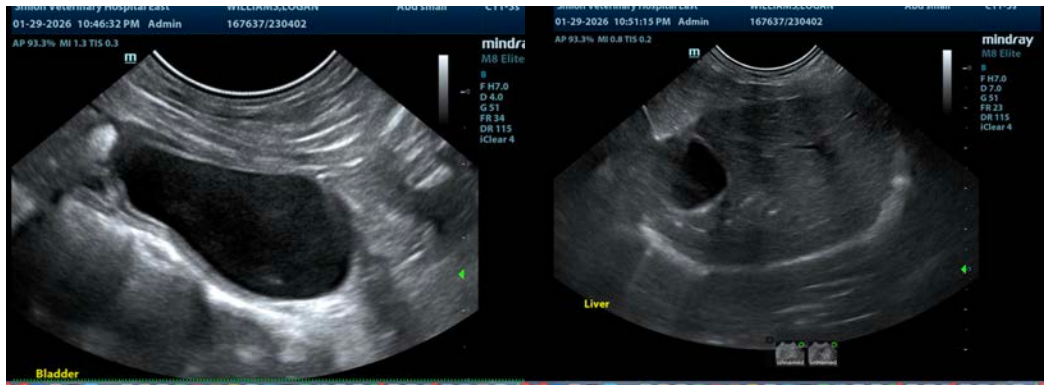Colleen Andrews, DVM

INVOICE

72637

DATE

1/30/26





PATIENT

Logan Williams

SPECIES

Canine

BREED

Maltese

SEX

Neutered Male

AGE

4

WEIGHT

11 lbs

INTERPRETED BY

Eric Lindquist, DMV,
DABVP (CFM), Cert.
IVUSS

IMAGING PERFORMED BY

Kevin Moon, DVM

HOSPITAL NAME

Shiloh Veterinary
Hospital

REFERRING VET

Colleen Andrews, DVM

INVOICE

72637

DATE

1/30/26

The information and recommendations provided are based on the images presented by the referring veterinarian/sonographer. No evaluation can be communicated regarding pathology that was not visible in the image/video clips provided.

Thank you for this referral. If the clinical or image interpretation does not parallel your findings or if I can be of any further assistance please contact me.

Eric Lindquist, DMV, DABVP(CFM), Cert. IVUSS,
CEO, Owner, Founder -- SonoPath.com
info@SonoPath.com