



PATIENT

Ellie Pagano

SPECIES

Canine

BREED

Bernedoodle

SEX

Spayed female

AGE

3 years

WEIGHT

49.9 lbs

INTERPRETED BY

Eric Lindquist, DMV
DABVP, Cert. IVUSS

IMAGING PERFORMED BY

Dr. Scott

HOSPITAL NAME

Wyckoff VH

REFERRING VET

Dr. Scott

INVOICE

71076

DATE

1/30/26

PRESENTING CLINICAL SIGNS

- ADR- was chewing on a basketball about 1 week ago, decreased app last 36 hours- did eat a few treats this morning
- hx of multiple enterotomies- last one was in November (see previous ultrasound)- had R&A with ometectomy and splenectomy at that time- recovered well
- PE WNL overall 2 view abd- concern for foreign matter seen

ULTRASONOGRAPHIC EXAMINATION OF THE ABDOMEN

Urinary System

The **urinary bladder**, trigone, and pelvic urethra presented normal thicknesses and normal tone. The pelvic urethra was imaged 2.0 cm beyond the cystourethral junction and appeared normal. The ureters were not visible which is normal. No uroliths or sediment were visualized and anechoic urine was present. No evidence of inflammatory or neoplastic changes was noted. Ureteral papillae were normal.

The **kidneys** revealed normal size and structure, corticomedullary definition and ratio for this age. The cortices presented largely uniform texture with normal echogenic relationship to liver and spleen. Medullary structure differed distinctly from the cortex and no evidence of pelvic dilation was present. The capsules were acceptably uniform without significant irregularities. The left kidney measured 6.0 cm. The right kidney measured 5.5 cm.

Adrenal Glands

Both **adrenal glands** were visualized and recognized as having normal shape, size, position and echogenicity for this breed. The phrenic vasculature, glandular echogenicity and detail were unremarkable. Capsule, cortex, and medullary definition were normal for this age patient. The left adrenal gland measured 0.5 cm. The right adrenal gland measured 0.85 cm at the cranial pole and 0.5 cm at the caudal pole.

Spleen

The **spleen** presented a smooth homogeneous parenchyma hyperechoic to liver and renal cortical parenchyma. The capsule was smooth without noticeable expansion or deviation from within the spleen or adjacent pathology. The splenic vasculature demonstrated normal volume without signs of congestion or thrombosis. No sonographic evidence of acute or chronic inflammatory, neoplastic, or infarctual changes was noted.

Liver

The **liver** images submitted revealed subjectively normal liver size, contour, and structure. Parenchymal echogenicity was naturally coarse and hypoechoic to the spleen. Vascular and biliary tracts were of



PATIENT

Ellie Pagano

SPECIES

Canine

BREED

Bernedoodle

SEX

Spayed female

AGE

3 years

WEIGHT

49.9 lbs

INTERPRETED BY

Eric Lindquist, DMV
DABVP, Cert. IVUSS

IMAGING PERFORMED BY

Dr. Scott

HOSPITAL NAME

Wyckoff VH

REFERRING VET

Dr. Scott

INVOICE

71076

DATE

1/30/26

normal volume with no evidence of congestion. The gallbladder presented acceptably thin walls with primarily anechoic content. The cystic and common bile ducts were normal. No pathological hepatic lymphadenopathy was evident. No overt structural evidence of inflammatory, infiltrative or regenerative pathology was evident.

Gastrointestinal

The **stomach** was over distended with shadowing material. The upper gastrointestinal tract was dilated with shadowing material and stasis followed by empty small intestine.

Pancreas

The base and limbs of the **pancreas** were observed to be largely isoechoic to surrounding omental fat. Pancreatic duct and capsular contour were acceptably normal and parenchyma respected normal curvilinear patterns. No overt evidence of active inflammatory or neoplastic disease was noted.

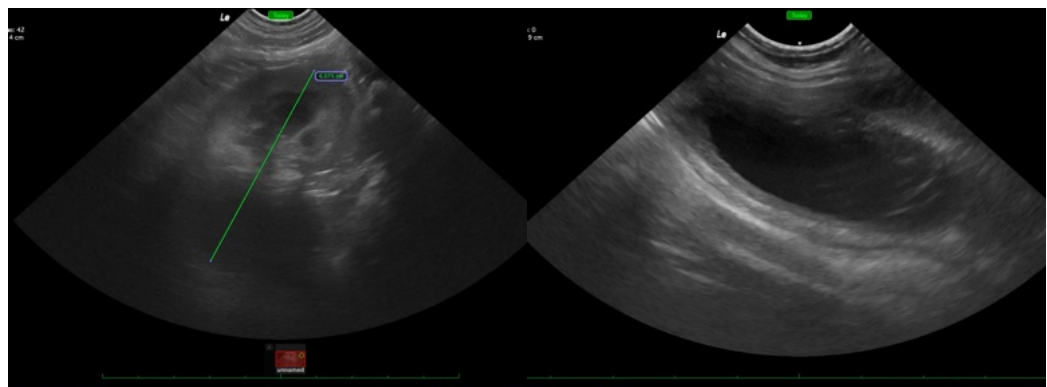
ULTRASONOGRAPHIC FINDINGS

Gastric and intestinal foreign bodies with obstructive pattern.

INTERPRETATION OF THE FINDINGS & FURTHER RECOMMENDATIONS

Immediate exploratory surgery is indicated. There was no evidence of peritonitis, however, this is a potential development in the near future if surgery is not performed. GI biopsies are indicated at the time of surgery to rule out underlying disease.

According to SonoPath research presented at ECVIM 2016 (Stockholm, Sweden), Advances in Small Animal Medicine and Surgery (May 2017), and EVDI 2017 (Verona, Italy), concurrent underlying chronic inflammatory neoplastic intestinal disease can often reside in PICA patients. Therefore, surgical biopsies are essential in this case regardless of the exploratory findings.





PATIENT

Ellie Pagano

SPECIES

Canine

BREED

Bernedoodle

SEX

Spayed female

AGE

3 years

WEIGHT

49.9 lbs

INTERPRETED BY

Eric Lindquist, DMV
DABVP, Cert. IVUSS

IMAGING PERFORMED BY

Dr. Scott

HOSPITAL NAME

Wyckoff VH

REFERRING VET

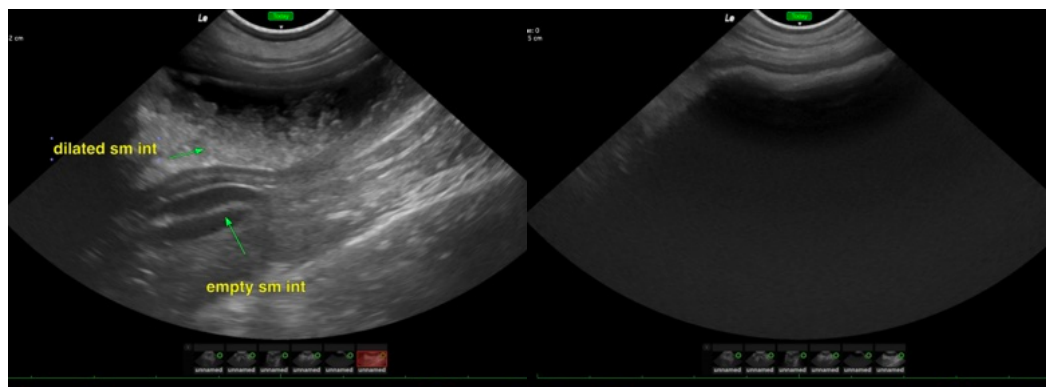
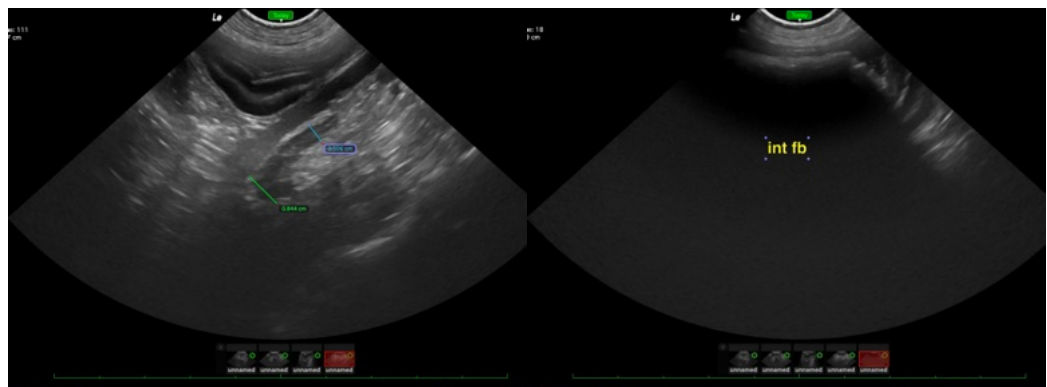
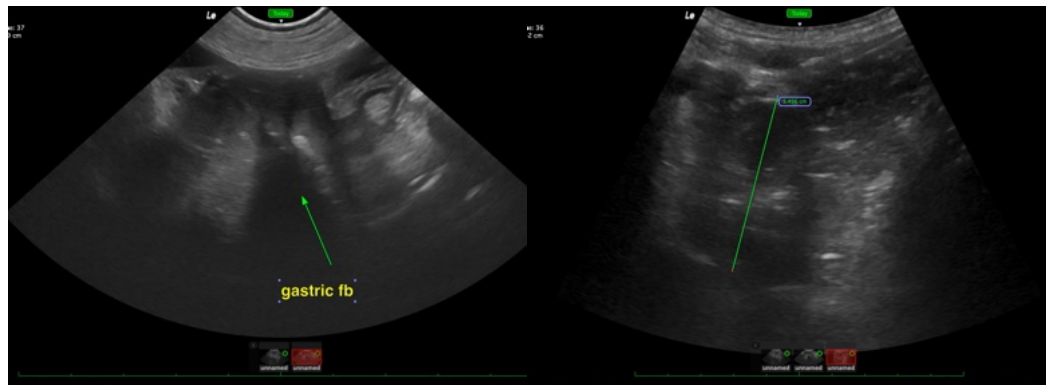
Dr. Scott

INVOICE

71076

DATE

1/30/26





PATIENT

Ellie Pagano

SPECIES

Canine

BREED

Bernedoodle

SEX

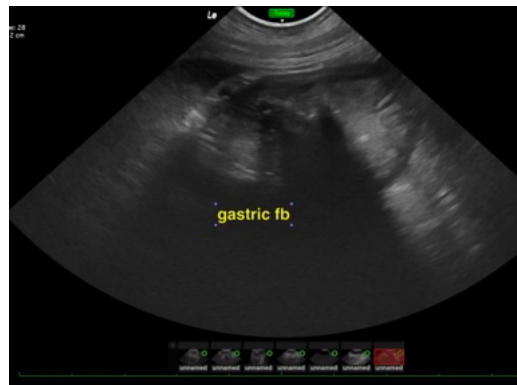Spayed female

AGE

3 years

WEIGHT

49.9 lbs



The information and recommendations provided are based on the images presented by the referring veterinarian/sonographer. No evaluation can be communicated regarding pathology that was not visible in the image/video clips provided.

Thank you for this referral. If the clinical or image interpretation does not parallel your findings or if I can be of any further assistance please contact me.

Eric Lindquist, DMV, DABVP (CFM), Cert. IVUSS, CEO of SonoPath.com

info@SonoPath.com

INTERPRETED BY

Eric Lindquist, DMV
DABVP, Cert. IVUSS

IMAGING PERFORMED BY

Dr. Scott

HOSPITAL NAME

Wyckoff VH

REFERRING VET

Dr. Scott

INVOICE

71076

DATE

1/30/26