



PATIENT

Cooper Hillman

SPECIES

Canine

BREED

Mixed

SEX

Castrated Male

AGE

13 Years 9 Months

WEIGHT

19.1 kg

INTERPRETED BY

Eric Lindquist, DMV,
DABVP (CFM), Cert.
IVUSS

IMAGING PERFORMED BY

Nicole Goldstein

HOSPITAL NAME

Hudson Animal
Hospital

REFERRING VET

Dr. Jacqueline Tatro

INVOICE

72633

DATE

1/30/26

PRESENTING CLINICAL SIGNS

Evaluation of elevated liver values (marked ALP, mild ALT). Historic mild ALP elevation (297) 1 year prior. Asymptomatic.

Abnormal PE/Chem/CBC/UA Results: Chem: TG 700, ALP 1126, PSL 198, ALT 124, remainder WNL T4 1.6 (normal) CBC: PLT 412 (mild mature thrombocytosis), remainder WNL UA: USG 1.044, pH 5, 2+ proteinuria, inactive sediment. UPC not run. Exam: suspect OA, SQ/cutaneous masses, grade 3-4/4 periodontal disease

ULTRASONOGRAPHIC EXAMINATION OF THE ABDOMEN

Urinary System

The **urinary bladder**, trigone, and pelvic urethra presented normal thicknesses and normal tone. The ureters were not visible which is normal. No uroliths or sediment were visualized and anechoic urine was present. No evidence of inflammatory or neoplastic changes were noted. Ureteral papillae were normal. The pelvic urethra was imaged 3.0 cm beyond the cystourethral junction.

The residual prostate was uniform at 1.7 cm.

The **kidneys** revealed largely normal size and structure, corticomedullary definition and ratio (cortex 1/3 of medulla) were essentially maintained with some age-related loss of curvilinear patterns regarding the capsule and C/M junction. The cortices presented largely uniform texture with some increased echogenicity expected for his age patient. Medullary structure differed distinctly from that of the cortex and no evidence of pelvic dilation was present. Left kidney measured 6.12 cm. Right kidney measured 6.7 cm.

Adrenal Glands

The **adrenal glands** appeared slightly enlarged and swollen. No evidence of focal capsular expansion or invasion into the phrenic veins were noted. No overt suspicion of neoplasia was noted. This is considered likely a hyperplastic change associated with stress or adrenal endocrinopathy (PDH). If isosthenuria is persistently present and the patient morphologically suggests Cushing's disease then ACTH testing would be indicated. Left adrenal gland measured 0.90 cm at the caudal pole and 0.42 cm at the cranial pole. Right adrenal gland measured 1.12 cm at the cranial pole and 1.02 cm at the caudal pole.

Spleen

The **spleen** presented a smooth homogeneous parenchyma hyperechoic to liver and renal cortical parenchyma. The capsule was smooth without noticeable expansion or deviation from within the spleen or adjacent pathology. The splenic vasculature demonstrated normal volume without signs of congestion or thrombosis. No sonographic evidence of acute or chronic inflammatory, neoplastic, or infarctual changes were noted.

Liver

The **liver** revealed multifocal hypoechoic nodular changes with diffuse coarse hyperechoic architecture otherwise. Ultrasound guided FNA indicated, as disrupted architecture is noted. The gallbladder and common bile duct were unremarkable.



PATIENT

Cooper Hillman

SPECIES

Canine

BREED

Mixed

SEX

Castrated Male

AGE

13 Years 9 Months

WEIGHT

19.1 kg

INTERPRETED BY

Eric Lindquist, DMV,
DABVP (CFM), Cert.
IVUSS

IMAGING PERFORMED BY

Nicole Goldstein

HOSPITAL NAME

Hudson Animal
Hospital

REFERRING VET

Dr. Jacqueline Tatro

INVOICE

72633

DATE

1/30/26

Gastrointestinal

Examination of the **gastrointestinal tract** revealed a stomach and intestine free of stasis, of normal wall thickness, acceptable curvilinear mural detail, and peristaltic activity. Small and large intestine demonstrated normal luminal chyme and stool consistency respectively. No obstructive or overt infiltrative disease was noted. No associated abnormal lymphatic activity was noted.

Pancreas

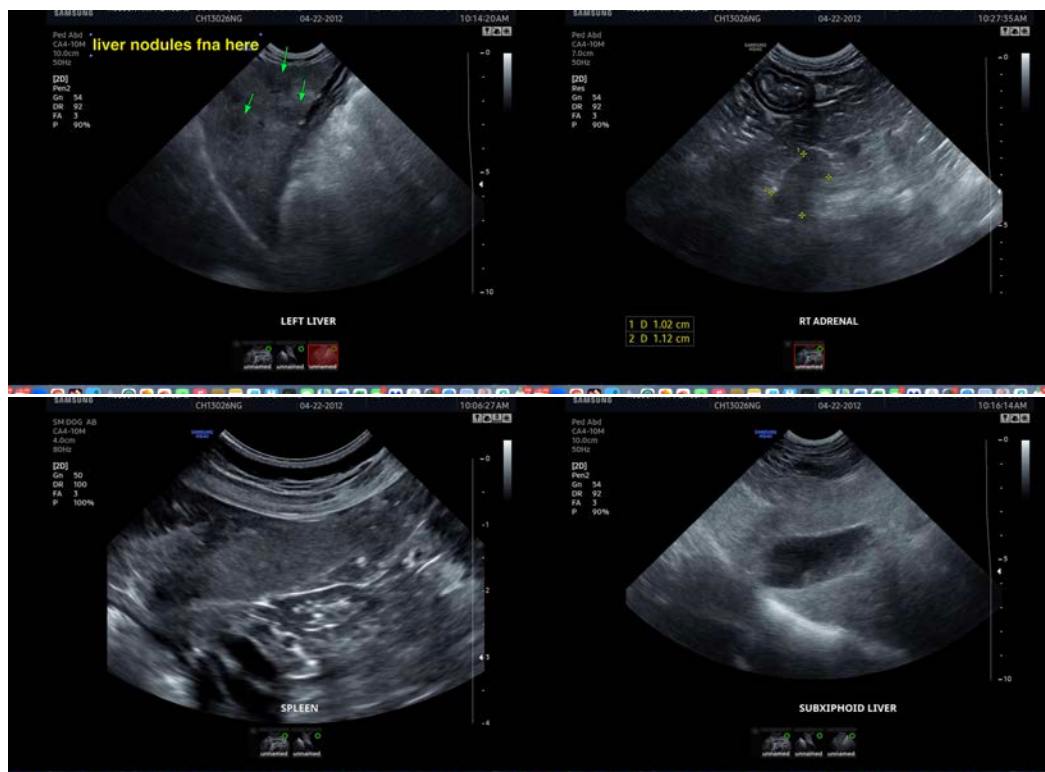
The base and limbs of the **pancreas** were observed to be largely isoechoic to surrounding omental fat. Pancreatic duct and capsular contour were acceptably normal and parenchyma respected normal curvilinear patterns. No overt evidence of active inflammatory or neoplastic disease was noted.

ULTRASONOGRAPHIC FINDINGS

- Bilateral adrenal hypertrophy, non-specific – hyperplasia likely. Given that USG is well concentrated, typical Cushing's is not likely at this point, however, may be emerging.
- Mildly disruptive hepatic nodular changes – nodular hyperplasia versus neoplastic process. Suppurative hepatitis less likely but possible.
- Age related renal changes.

INTERPRETATION OF THE FINDINGS & FURTHER RECOMMENDATIONS

25-gauge FNA of the liver nodules recommended for further definition. Bile acid profile could also be justified.





PATIENT

Cooper Hillman

SPECIES

Canine

BREED

Mixed

SEX

Castrated Male

AGE

13 Years 9 Months

WEIGHT

19.1 kg

INTERPRETED BY

Eric Lindquist, DMV,
DABVP (CFM), Cert.
IVUSS

IMAGING PERFORMED BY

Nicole Goldstein

HOSPITAL NAME

Hudson Animal
Hospital

REFERRING VET

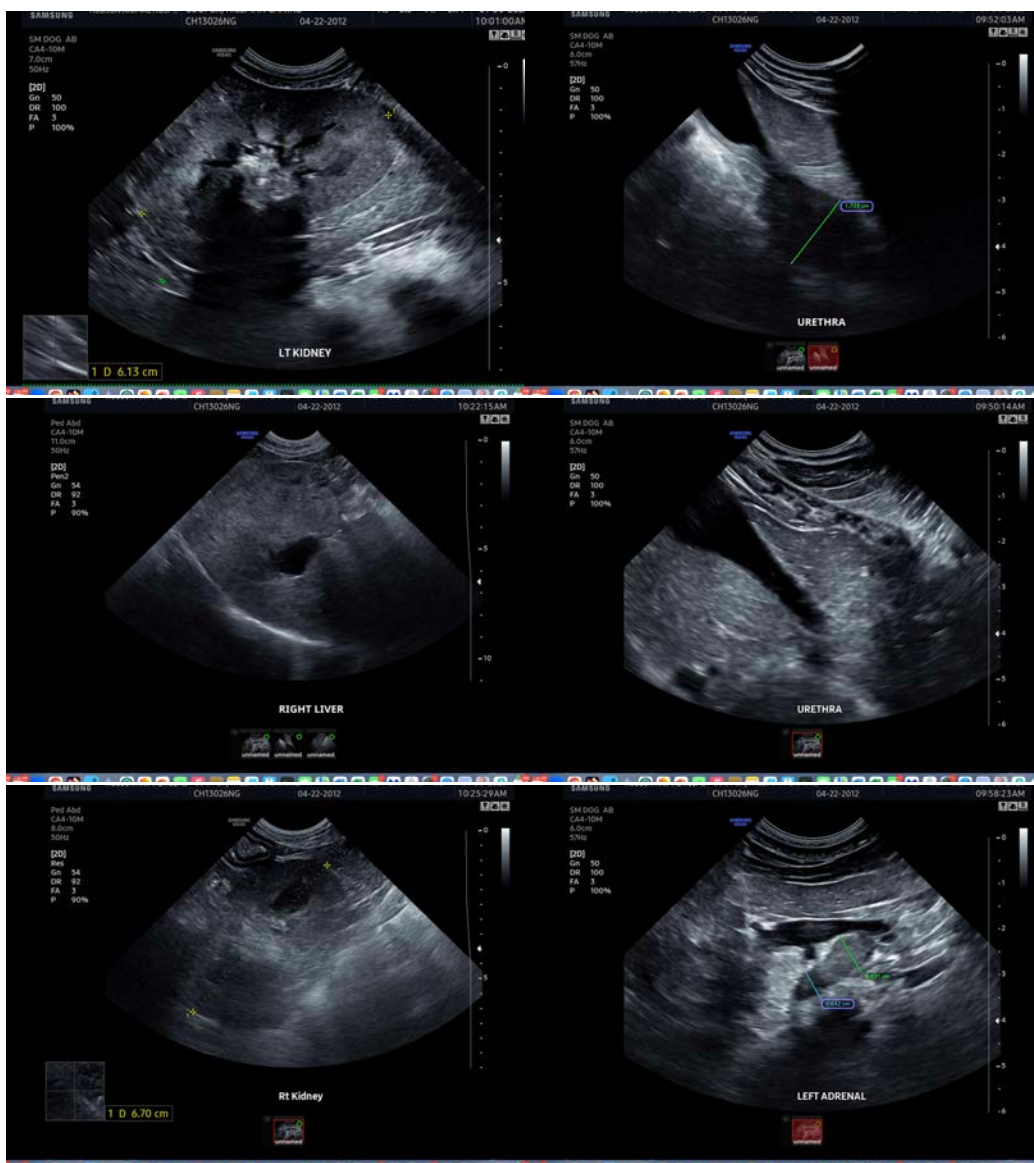
Dr. Jacqueline Tatro

INVOICE

72633

DATE

1/30/26



The information and recommendations provided are based on the images presented by the referring veterinarian/sonographer. No evaluation can be communicated regarding pathology that was not visible in the image/video clips provided.

Thank you for this referral. If the clinical or image interpretation does not parallel your findings or if I can be of any further assistance please contact me.

Eric Lindquist, DMV, DABVP(CFM), Cert. IVUSS,
CEO, Owner, Founder -- SonoPath.com
info@SonoPath.com