



DATE PRESENTING CLINICAL SIGNS

01/30/26 Patient History: Presented 12/31/25 for possible trouble eating- palpable mass 6 inches cranial to vent

PATIENT

Citrus Meadowside Nature Center

Current Medications: None listed.
Labwork Results: No labwork attached.
Date of Previous IntraPet Ultrasound: No previous.
Sedation: Not required to complete full diagnostic ultrasound.
Stat Report: Not requested.

SPECIES

Reptile

Imaging Performed by: Rachel Brillhart, RDMS.

ULTRASONOGRAPHIC EXAMINATION

BREED

Corn Snake

Gastrointestinal

SEX

Intact Male

Multiple images of a concentric hypoechoic intestinal mass was noted in this patient measuring 4.1 cm x 1.6 cm with a stricturing contour and entrapped chyme. Slight areas of free fluid were noted which may indicate early metastasis to regional tissues and early metastasis to lymphatics. The normal intestine was identified with a serosal layer and clearly encompassing the mass in a continuous fashion with the normal intestine. The mass appears derived from the intestinal wall, particularly that of the mucosa layer. The mineralization of the mass would suggest carcinoma. This mass does appear to be potentially resectable.

AGE

04/23/07

ULTRASONOGRAPHIC FINDINGS

WEIGHT

654 grams

- Small intestinal mass with free fluid.

INTERPRETATION OF THE FINDINGS & FURTHER RECOMMENDATIONS

INTERPRETED BY

Eric Lindquist, DMV, DABVP(CFM), Cert. IVUSS

I recommend attempt at surgical resection.

HOSPITAL NAME

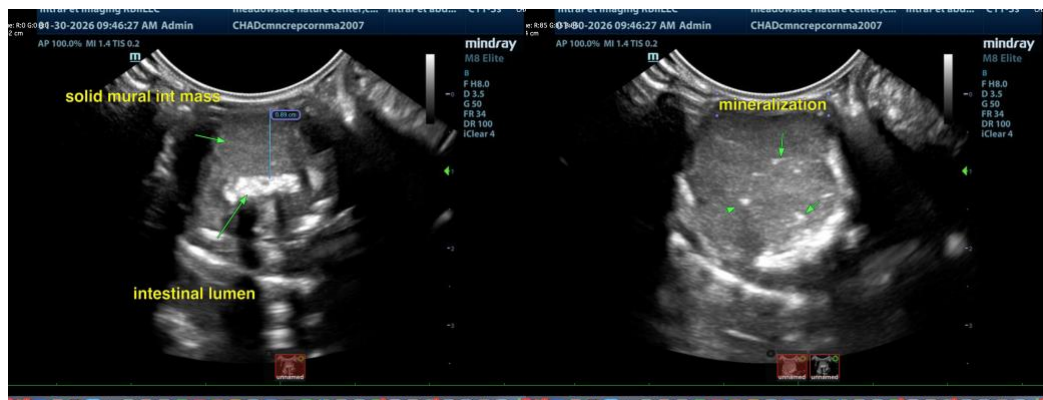Chadwell Animal Hospital

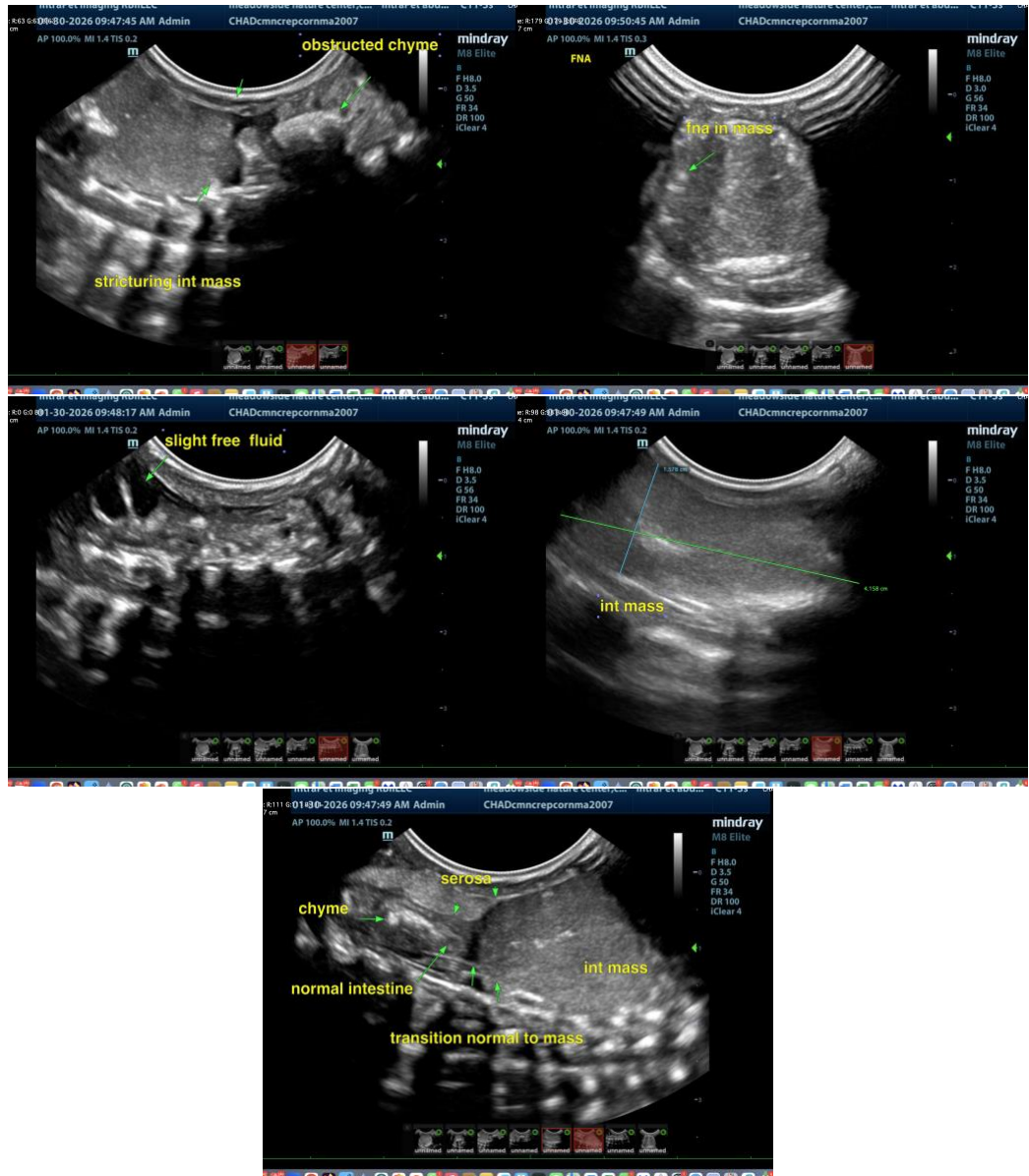
REFERRING VET

Dr. Gold

INVOICE

13487





The information and recommendations provided are based on the images presented by the referring veterinarian/sonographer. No evaluation can be communicated regarding pathology that was not visible in the image/video clips provided.

Thank you for this referral. If the clinical or image interpretation does not parallel your findings or if I can be of any further assistance, please contact me.

Eric Lindquist, DMV, DABVP(CFM), Cert. IVUSS,

CEO, Owner, Founder -- SonoPath.com

info@SonoPath.com