



**PATIENT PRESENTING CLINICAL SIGNS**

Georgia Deery Newly diagnosed elevated liver enzymes.

**SPECIES ULTRASONOGRAPHIC EXAMINATION OF THE HEART & ABDOMEN**

Canine

**BREED**

Mix

**SEX**

Spayed Female

**AGE**

9.5 Years

**WEIGHT**

33 Pounds

CANINE CARDIAC PARAMETERS	MR VMAX (m/s)	TR VMAX (m/s)	LA/AO (Boon method)	LA/AO (Heart Base; Swe)	FS (%)	EF (%)	EPSS (cm)
NORMAL PARAMETER	4.5-5.5	<2.7	1.3	<1.6	28-40	40-100	<0.6
PATIENT	4.8	1.29	1.0	0.93	42	74	0.7
CANINE CARDIAC PARAMETERS	HR (BPM)	AV VMAX (m/s)	PV MAX (m/s)	BODY WEIGHT (kg)	LA 2D short axis Base view (cm)	LVIDd Avg; 2D and m-mode short axis (cm)	LVIDs Avg; 2D and m-mode short axis (cm)
NORMAL PARAMETER	50-100	0.7-1.7	0.7-1.6	BELOW	BELOW	BELOW	BELOW
PATIENT			0.64		3.2	3.8	

**INTERPRETED BY**

Eric Lindquist, DMV

DABVP, Cert. IVUSS

**IMAGING PERFORMED BY**

SDEP Lab

**HOSPITAL NAME**

SDEP Lab

**REFERRING VET**

N/A

**INVOICE**

44618

**DATE**

1/28/23

**Cardiac Presentation**

The echocardiogram in this patient demonstrated normal **left atrial** size based on 3 separate methods of LA evaluation. Trivial **mitral** insufficiency noted. The **left ventricle** presented thicknesses with linear contour and was not dilated nor restricted. The **myocardium** presented normal echogenicity without subjective evidence of significant fibrotic or ischemic disease. **Contractility** of the ventricular walls was adequate and in normal range for this patient evidenced by the fractional shortening measurement and subjective evaluation of the different regions of the myocardium. The **left ventricular outflow** tract demonstrated normal laminar flow and subjective structural integrity. The **right atrium** and auricle revealed normal size, structure and content. No evidence of masses was noted. Trivial **tricuspid** insufficiency noted. The **right ventricle** was of normal size (1/3 diameter of LV), chordae structure, myocardial echogenicity and thickness. **Pulmonary outflow** tract assessment revealed normal valve structure, laminar flow, and diameter (approx. 1:1 pa/ao ratio). No visible **pericardial** or free pleura fluid was noted. The cranial **mediastinum** and **pericardial** and **extra-cardiac** regions were free of masses in the visible window.

This patient was seated at the time of the sonogram.

**Urinary System**

The **urinary bladder** revealed a polypoid change at the cystourethral junction measuring 2.5 cm x 1.1 cm. It does not appear to be obstructing the ureters. However, it is in the region of the ureteral papillae and at the cystourethral junction and is moderately vascular. The urethra appeared unremarkable. Iliac trifurcation was unremarkable. The pelvic urethra was imaged 3.0 cm beyond the cystourethral junction.

The **kidneys** revealed largely normal size and structure, corticomedullary definition and ratio (cortex 1/3 of medulla) were essentially maintained with some age-related loss of curvilinear patterns regarding the capsule and C/M junction. The cortices presented largely uniform texture with some increased



**PATIENT**

Georgia Deery

echogenicity expected for his age patient. Medullary structure differed distinctly from that of the cortex and no evidence of pelvic dilation was present. Slight pinpoint mineralizations noted. The right kidney measured 6.33 cm.

**SPECIES**

Canine

**Adrenal Glands**

The **right adrenal gland** was visualized and recognized as having normal shape, size, position and echogenicity for this breed. The phrenic vasculature, glandular echogenicity and detail were unremarkable. Capsule, cortex, and medullary definition were normal for this age patient. The right adrenal gland measured 1.95 cm x 1.14 cm at the cranial pole and 0.59 cm at the caudal pole.

**BREED**

Mix

The **left adrenal gland** was slightly heterogeneous and mildly enlarged at the cranial pole, measuring 2.31 cm x 0.66 cm at the caudal pole and 1.0 cm at the cranial pole.

**SEX**

Spayed Female

**Spleen**

The **spleen** presented a smooth homogeneous parenchyma hyperechoic to liver and renal cortical parenchyma. The capsule was smooth without noticeable expansion or deviation from within the spleen or adjacent pathology. The splenic vasculature demonstrated normal volume without signs of congestion or thrombosis. No sonographic evidence of acute or chronic inflammatory, neoplastic, or infarctual changes were noted.

**AGE**

9.5 Years

**WEIGHT**

33 Pounds

**Liver**

The **liver** images from right and left intercostal as well as subcostal views revealed subjectively normal liver size, contour, and structure. Some age-related parenchymal remodeling was noted but likely not clinically significant at this time. Vascular and biliary tracts were of normal volume and no evidence of congestion was noted. The gallbladder presented some dependent debris with essentially normal contour. The cystic and common bile ducts were normal. No overt evidence of active inflammatory, infiltrative or regenerative pathology was noted but should be paired with current or past LE elevations regarding any clinical significance to this presentation. The hepatic lymph nodes were unremarkable.

**INTERPRETED BY**

Eric Lindquist, DMV

DABVP, Cert. IVUSS

**IMAGING PERFORMED BY**

SDEP Lab

**HOSPITAL NAME**

SDEP Lab

**Gastrointestinal**

Examination of the **gastrointestinal tract** revealed a stomach and intestine free of stasis, of normal wall thickness, acceptable curvilinear mural detail, and peristaltic activity. Small and large intestine demonstrated normal luminal chyme and stool consistency respectively. No obstructive or overt infiltrative disease was noted. No associated abnormal lymphatic activity was noted.

**REFERRING VET**

N/A

**Pancreas**

The base and limbs of the **pancreas** were observed to be largely isoechoic to surrounding omental fat. Pancreatic duct and capsular contour were acceptably normal and parenchyma respected normal curvilinear patterns. No overt evidence of active inflammatory or neoplastic disease was noted.

**INVOICE**

44618

**ULTRASONOGRAPHIC FINDINGS**

**DATE**

1/28/23

- Early Stage B1 valvular disease, not clinically significant
- Heterogeneous adrenal glands, slightly enlarged left adrenal gland
- Age related renal changes with mineralization
- Polypoid bladder lesion at the trigone/cystourethral junction
- Benign hepatopathy



**PATIENT**

Georgia Deery

**SPECIES**

Canine

**BREED**

Mix

**SEX**

Spayed Female

**AGE**

9.5 Years

**WEIGHT**

33 Pounds

**INTERPRETED BY**

Eric Lindquist, DMV

DABVP, Cert. IVUSS

**IMAGING PERFORMED BY**

SDEP Lab

**HOSPITAL NAME**

SDEP Lab

**REFERRING VET**

N/A

**INVOICE**

44618

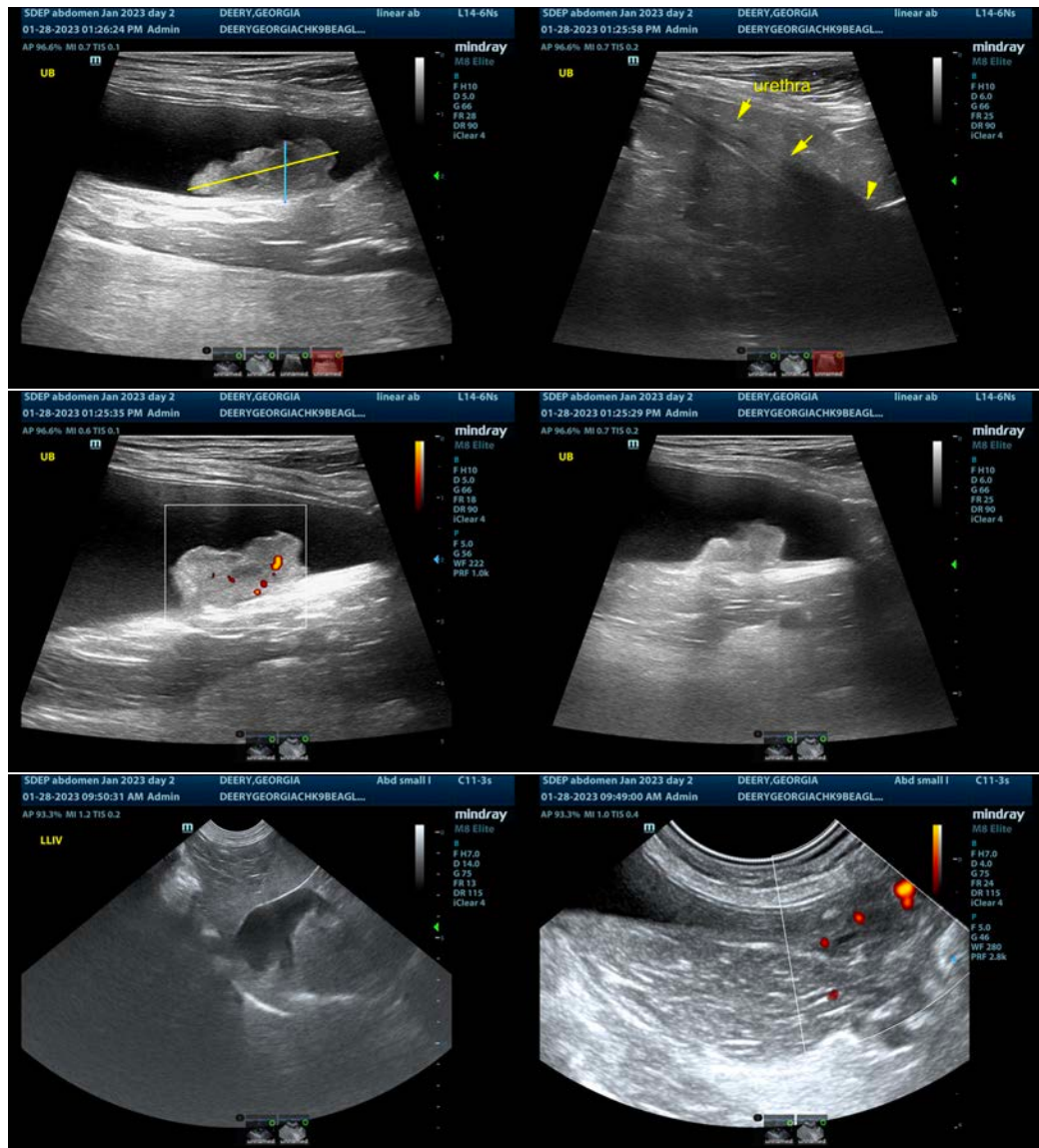
**DATE**

1/28/23

**INTERPRETATION OF THE FINDINGS & FURTHER RECOMMENDATIONS**

The heart is stable without clinical disease. No overt contraindication for anesthesia of brief to moderate duration. I suggest Torbutrol premed, Propofol induction, Isoflor maintenance or similar protocol if anesthesia is desired. Blood pressure recommended if not already performed and target white coat negative systolic pressure of < 160 mmHg. If higher than this ACE-inhibitor is suggested to reach this level. Recheck echocardiogram is recommended in 6 months, earlier if murmur grade increases or clinical signs initiate.

Cystoscopy and polyp biopsies indicated. Blood pressure warranted. If patient appears Cushingoid, then workup for pituitary dependent Cushing's would be indicated. Strong concern for early transitional cell carcinoma. Polypoid hyperplasia possible yet less likely.





**PATIENT**

Georgia Deery

**SPECIES**

Canine

**BREED**

Mix

**SEX**

Spayed Female

**AGE**

9.5 Years

**WEIGHT**

33 Pounds

**INTERPRETED BY**

Eric Lindquist, DMV

DABVP, Cert. IVUSS

**IMAGING PERFORMED BY**

SDEP Lab

**HOSPITAL NAME**

SDEP Lab

**REFERRING VET**

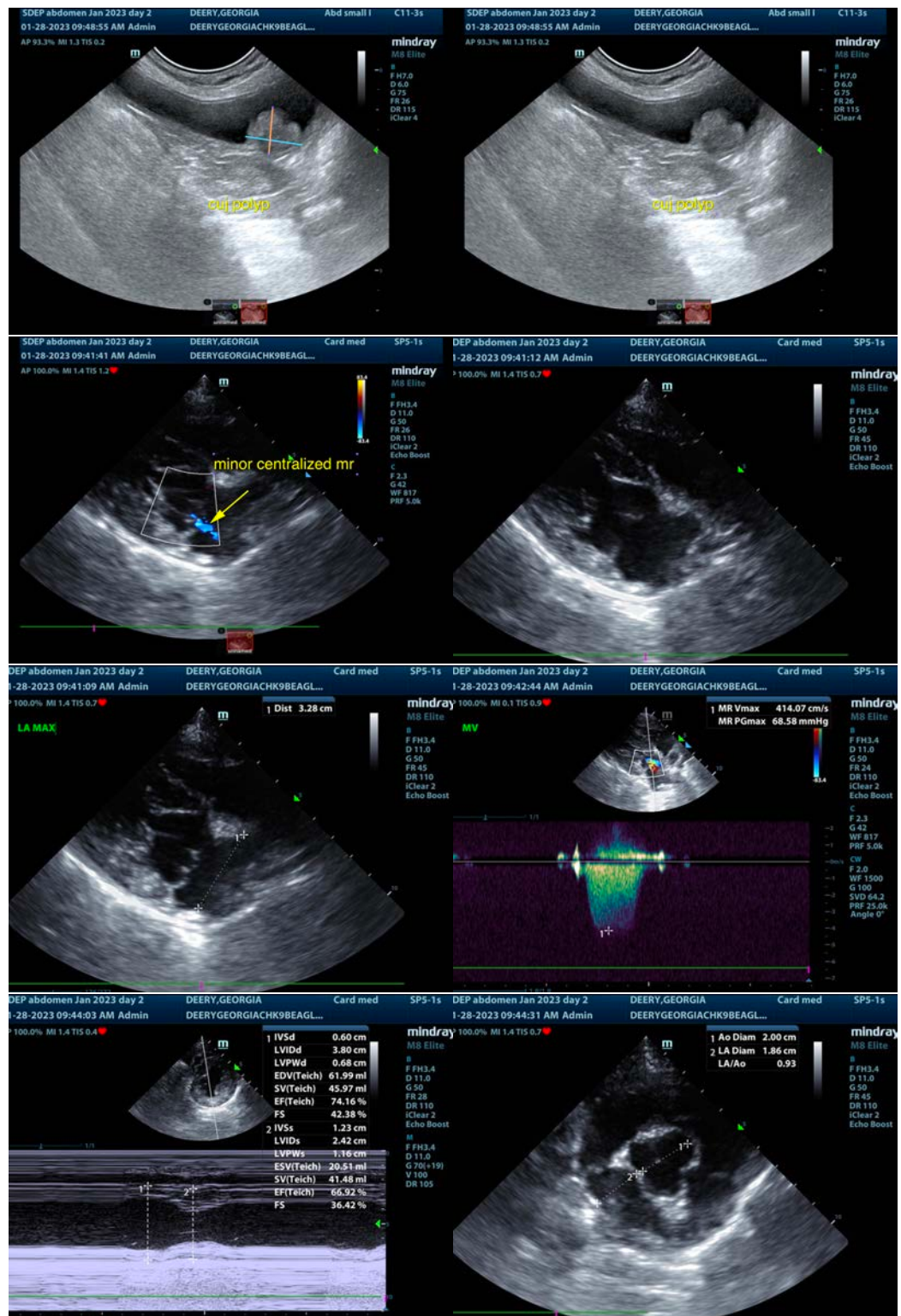
N/A

**INVOICE**

44618

**DATE**

1/28/23





**PATIENT**

Georgia Deery

**SPECIES**

Canine

**BREED**

Mix

**SEX**

Spayed Female

**AGE**

9.5 Years

**WEIGHT**

33 Pounds

**INTERPRETED BY**

Eric Lindquist, DMV

DABVP, Cert. IVUSS

**IMAGING PERFORMED BY**

SDEP Lab

**HOSPITAL NAME**

SDEP Lab

**REFERRING VET**

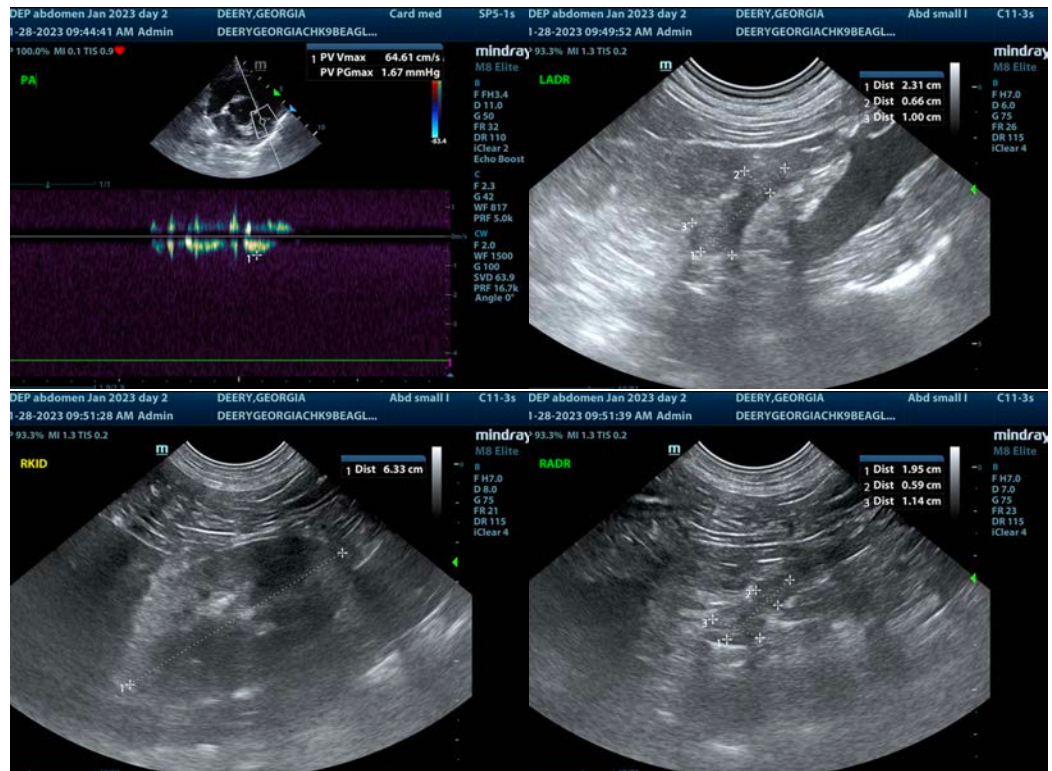
N/A

**INVOICE**

44618

**DATE**

1/28/23



The information and recommendations provided are based on the images presented by the referring veterinarian/sonographer. No evaluation can be communicated regarding pathology that was not visible in the image/video clips provided.

Thank you for this referral. If the clinical or image interpretation does not parallel your findings or if I can be of any further assistance please contact me.

**Eric Lindquist, DMV, DABVP, Cert. IVUSS, CEO of SonoPath.com**

[info@SonoPath.com](mailto:info@SonoPath.com)