



**PATIENT**

Ninja Bradley

**PRESENTING CLINICAL SIGNS**

anorexia and weight loss  
Abnormal PE/Chem/CBC/UA Results: BCS=2/9, neutrophilia noted on CBC, NSF otherwise.

**SPECIES**

Feline

**ULTRASONOGRAPHIC EXAMINATION OF THE ABDOMEN**

**Urinary System**

**BREED**

DSH

The **urinary bladder**, trigone, and pelvic urethra presented normal thicknesses and normal tone. The ureters were not visible which is normal. No uroliths or sediment were visualized and anechoic urine was present. No evidence of inflammatory or neoplastic changes were noted. Ureteral papillae were normal.

**SEX**

Spayed Female

The **kidneys** revealed largely normal size and structure, corticomedullary definition and ratio (cortex 1/3 of medulla) were essentially maintained with some age-related loss of curvilinear patterns regarding the capsule and C/M junction. The cortices presented largely uniform texture with some increased echogenicity expected for his age patient. Medullary structure differed distinctly from that of the cortex and no evidence of pelvic dilation was present. The left kidney measured 3.5 cm. The right kidney measured 3.5 cm.

**AGE**

8 Years

**Adrenal Glands**

The regions of the **adrenal glands** were unremarkable.

**WEIGHT**

5.8 Pounds

**Spleen**

The **spleen** was largely smooth with subtle heterogeneous parenchymal changes while maintaining normal echogenic relationship to the liver and kidney. These changes are consistent with normal age-related alteration. The capsule was smooth without noticeable impingement from within the spleen or from pathology in the adjacent abdomen. The splenic vasculature demonstrated normal volume without signs of congestion or significant contraction. No evidence of active acute or chronic inflammatory, neoplastic, or infarctual changes were noted.

**INTERPRETED BY**

Eric Lindquist, DMV

DABVP, Cert. IVUSS

**Liver**

The **liver** was coarse in architecture with variable areas of remodeling. The gallbladder and common bile duct were unremarkable.

**IMAGING PERFORMED BY**

Sarah Green

**Gastrointestinal**

**HOSPITAL NAME**

Healing Spirit

An undifferentiated **upper gastrointestinal** mass was noted. Origin appeared to be the stomach, yet could not be completely defined. The mass measured approximately 4.0 cm x 3.0 cm. The pylorus appeared to be significantly distorted by the mass. Variable areas of the upper gastrointestinal tract revealed thickening.

**REFERRING VET**

Dr. Izaan du Toit

**Pancreas**

The **pancreas** was coarse in architecture with irregular contour and dilated duct.

**INVOICE**

35199

**Free Abdomen**

A mild amount of free fluid was noted.

**DATE**

1/30/22



**PATIENT**

Ninja Bradley

**ULTRASONOGRAPHIC FINDINGS**

- Upper gastrointestinal mass possibly involving the pancreas
- Regional free fluid

**SPECIES**

Feline

**INTERPRETATION OF THE FINDINGS & FURTHER RECOMMENDATIONS**

The mass does not appear resectable. Carcinomatosis/lymphomatosis type presentation. Ultrasound guided FNA warranted to assess the ability to chemo reduce.

**BREED**

DSH

**SEX**

Spayed Female

**AGE**

8 Years

**WEIGHT**

5.8 Pounds

**INTERPRETED BY**

Eric Lindquist, DMV  
DABVP, Cert. IVUSS

**IMAGING PERFORMED BY**

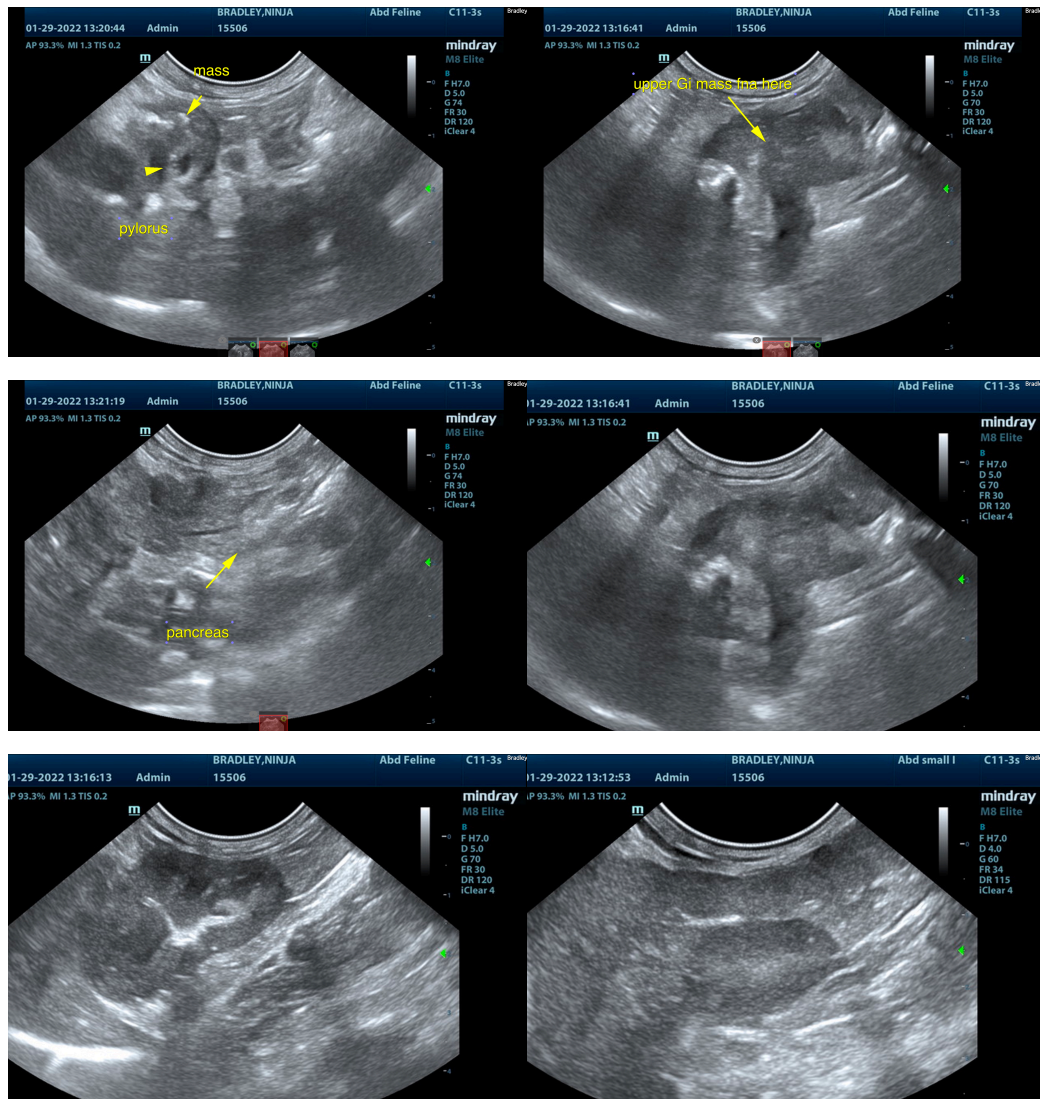
Sarah Green

**HOSPITAL NAME**

Healing Spirit

**REFERRING VET**

Dr. Izaan du Toit



**INVOICE**

35199

**DATE**

1/30/22



**PATIENT**

Ninja Bradley

**SPECIES**

Feline

**BREED**

DSH

**SEX**

Spayed Female

**AGE**

8 Years

**WEIGHT**

5.8 Pounds

**INTERPRETED BY**

Eric Lindquist, DMV

DABVP, Cert. IVUSS

**IMAGING PERFORMED BY**

Sarah Green

**HOSPITAL NAME**

Healing Spirit

**REFERRING VET**

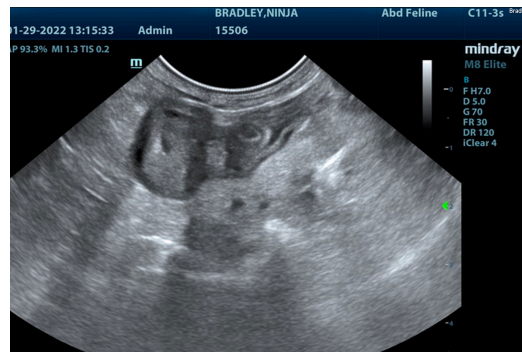Dr. Izaan du Toit

**INVOICE**

35199

**DATE**

1/30/22



The information and recommendations provided are based on the images presented by the referring veterinarian/sonographer. No evaluation can be communicated regarding pathology that was not visible in the image/video clips provided.

Thank you for this referral. If the clinical or image interpretation does not parallel your findings or if I can be of any further assistance please contact me.

Eric Lindquist, DMV, DABVP, Cert. IVUSS, CEO of SonoPath.com

[info@SonoPath.com](mailto:info@SonoPath.com)