



**PATIENT**

Baby Ngo

**SPECIES**

Canine

**BREED**

Maltese

**SEX**

Neutered male

**AGE**

2 years

**WEIGHT**

5.6 lbs

**INTERPRETED BY**

Eric Lindquist, DMV  
DABVP, Cert. IVUSS

**IMAGING  
PERFORMED BY**

Dr. Belan

**HOSPITAL NAME**

Sanctuary VC

**REFERRING VET**

Dr. Warnakulasooriya

**INVOICE**

42482

**DATE**

1/3/23

**PRESENTING CLINICAL SIGNS**

History: Suspicion of PSS having seizures for last 8 months  
Abnormal PE/Chem/CBC/UA Results: Mild elevation of ALT with marked elevation of Bile acids done on Dec 28 2022 pre prandial 73 and post prandial was 242. Normal range less than 13

**ULTRASONOGRAPHIC EXAMINATION OF THE ABDOMEN**

**Urinary System**

The **urinary bladder**, trigone, and pelvic urethra presented normal thicknesses and normal tone. The ureters were not visible which is normal. No uroliths or sediment were visualized and anechoic urine was present. No evidence of inflammatory or neoplastic changes was noted. Ureteral papillae were normal.

The **kidneys** revealed normal size and structure, corticomedullary definition and ratio for this age. The cortices presented largely uniform texture with normal echogenic relationship to liver and spleen. Medullary structure differed distinctly from the cortex and no evidence of pelvic dilation was present. The capsules were acceptably uniform without significant irregularities. The left kidney measured 3.9 cm.

**Adrenal Glands**

Both **adrenal glands** were visualized and recognized as having normal shape, size, position and echogenicity for this breed. The phrenic vasculature, glandular echogenicity and detail were unremarkable. Capsule, cortex, and medullary definition were normal for this age patient. The left adrenal gland measured 0.3 cm at the cranial pole and 0.35 cm at the caudal pole. The right adrenal gland measured 0.39 cm at the cranial pole and 0.41 cm at the caudal pole.

**Spleen**

The **spleen** presented a smooth homogeneous parenchyma hyperechoic to liver and renal cortical parenchyma. The capsule was smooth without noticeable expansion or deviation from within the spleen or adjacent pathology. The splenic vasculature demonstrated normal volume without signs of congestion or thrombosis. No sonographic evidence of acute or chronic inflammatory, neoplastic, or infarctual changes was noted.

**Liver**

The **liver** was subnormal in size. The vena cava measured 0.67 cm. The portal vein measured 0.4 cm. The aorta measured 0.5 cm. An abnormal dorsally directed vessel in the region of the splenocaval shunt appeared to be present; however, this should be confirmed by CT. The suspected shunt measured 0.64 cm in width. Portal vein branching appeared normal. The gallbladder presented acceptably thin walls with primarily anechoic content. The cystic and common bile ducts were normal. No pathological hepatic lymphadenopathy was evident. No overt structural evidence of inflammatory, infiltrative or regenerative pathology was evident.



**PATIENT**

**Gastrointestinal**

Baby Ngo

The **stomach** revealed a minor amount of fluid filled luminal dilation. The small intestines and colon were unremarkable.

**SPECIES**

Canine

**Pancreas**

**BREED**

Maltese

The base and limbs of the **pancreas** were observed to be largely isoechoic to surrounding omental fat. Pancreatic duct and capsular contour were acceptably normal and parenchyma respected normal curvilinear patterns. No overt evidence of active inflammatory or neoplastic disease was noted.

**SEX**

Neutered male

**ULTRASONOGRAPHIC FINDINGS**

Suspect splenocaval shunt.

**AGE**

2 years

Enlarged vena cava with subnormal vein size and abnormal, dorsally directed vessel in the region of the splenocaval shunt.

**WEIGHT**

5.6 lbs

**INTERPRETATION OF THE FINDINGS & FURTHER RECOMMENDATIONS**

Given the bile acid elevation and microhepatica and abnormal vascular pattern, I strongly recommend CT with contrast. Medical management of this patient with the following protocol should prove effective in the meantime.

**INTERPRETED BY**

Eric Lindquist, DMV  
DABVP, Cert. IVUSS

**Royal Canin Hepatic Support diet or Hills L/D, Metronidazole (7.5 mg/kg PO bid)** over the next 14 days, **Lactulose** (Oral: 3.1-3.7 g/5 ml lactulose in a syrup base) long term to target 2-3 soft stools/day, with a **high-quality protein supplement** of minor amount of **yogurt or cheddar cheese**. Monitor bile acids, with attention paid to dropping albumin, BUN or cholesterol. **SAME** and nutraceuticals as needed. **Ursodiol** (10-15 mg/kg p.o. q24h) can be considered as hepatoprotectant and to enhance bile flow. **Zinc** serum level keep between 200–500 ug/dl. If deficient then Tx zinc acetate 1-3 mg/kg/day. Gastrointestinal protectants are recommended if the patient is anorexic.

**IMAGING PERFORMED BY**

Dr. Belan

**HOSPITAL NAME**

Sanctuary VC

**REFERRING VET**

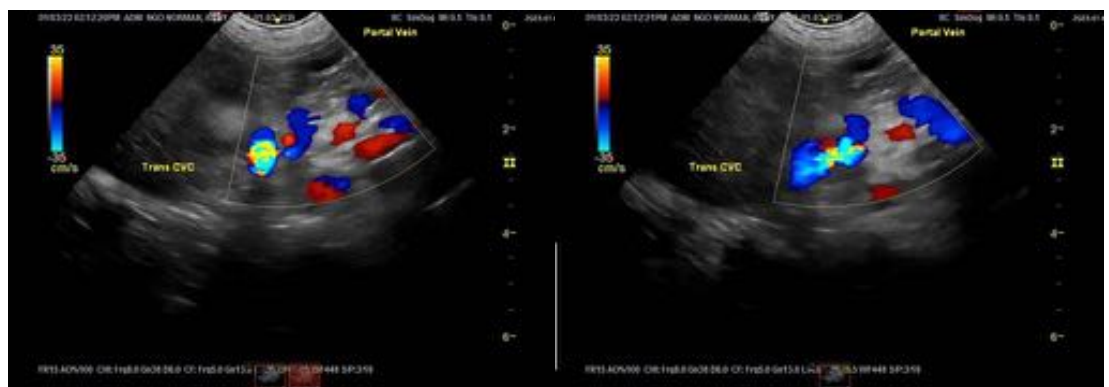
Dr. Warnakulasooriya

**INVOICE**

42482

**DATE**

1/3/23





**PATIENT**

Baby Ngo

**SPECIES**

Canine

**BREED**

Maltese

**SEX**

Neutered male

**AGE**

2 years

**WEIGHT**

5.6 lbs

**INTERPRETED BY**

Eric Lindquist, DMV  
DABVP, Cert. IVUSS

**IMAGING PERFORMED BY**

Dr. Belan

**HOSPITAL NAME**

Sanctuary VC

**REFERRING VET**

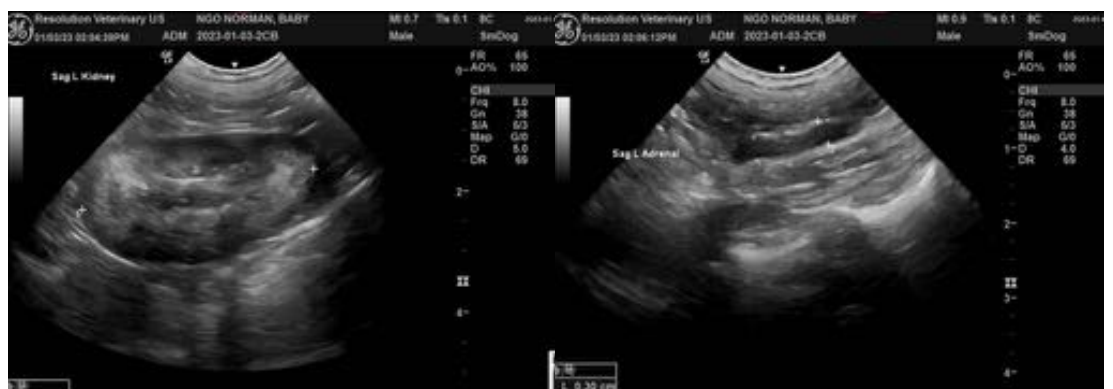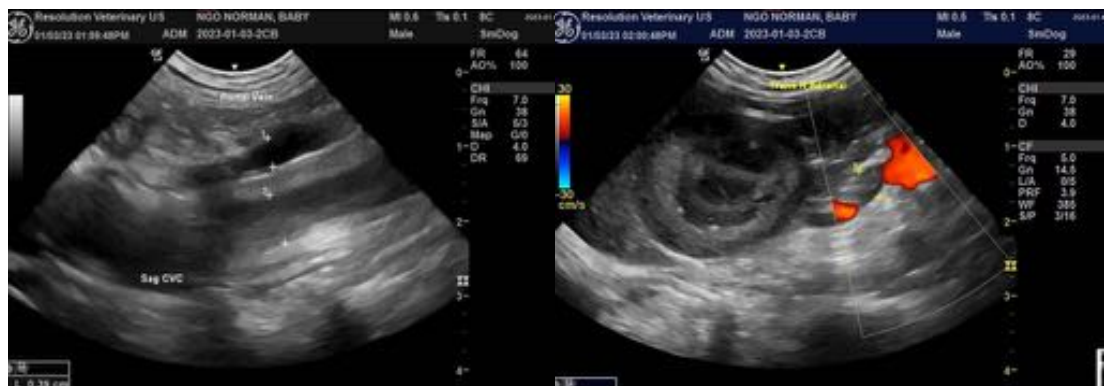
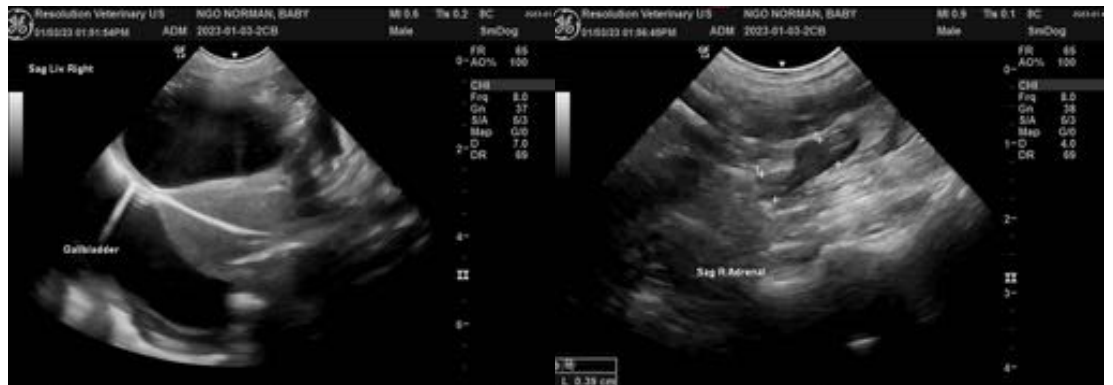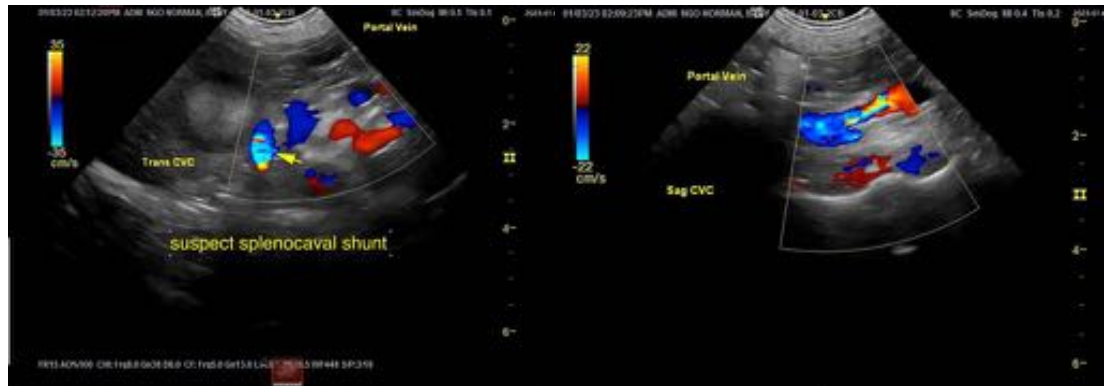
Dr. Warnakulasooriya

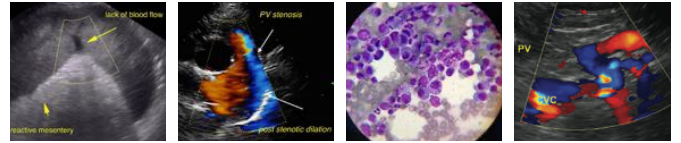
**INVOICE**

42482

**DATE**

1/3/23





**PATIENT**

Baby Ngo

**SPECIES**

Canine

**BREED**

Maltese

**SEX**

Neutered male

**AGE**

2 years

**WEIGHT**

5.6 lbs

**INTERPRETED BY**

Eric Lindquist, DMV  
DABVP, Cert. IVUSS

**IMAGING PERFORMED BY**

Dr. Belan

**HOSPITAL NAME**

Sanctuary VC

**REFERRING VET**

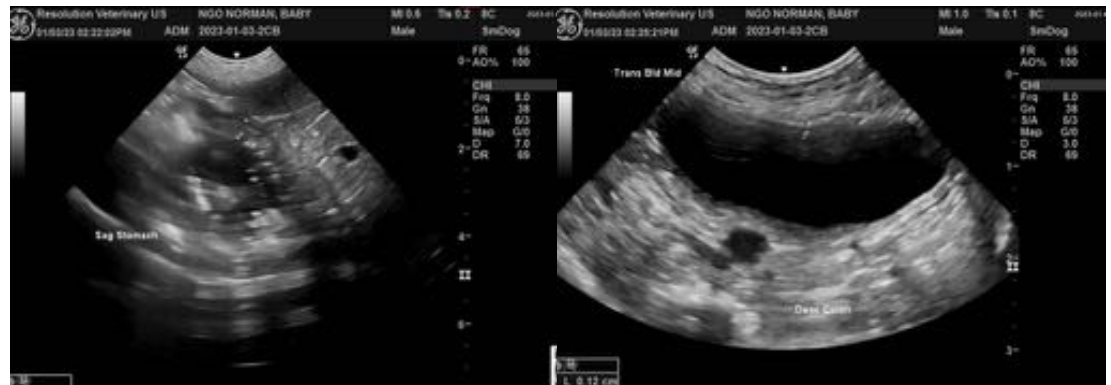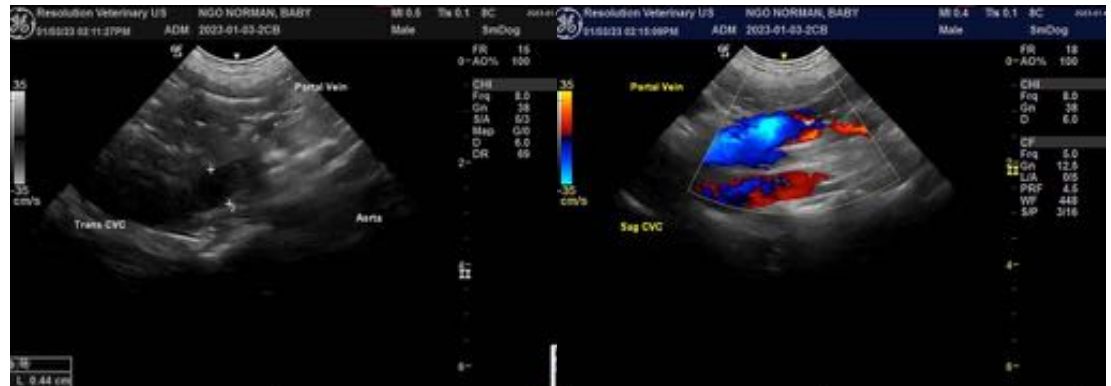Dr. Warnakulasooriya

**INVOICE**

42482

**DATE**

1/3/23



The information and recommendations provided are based on the images presented by the referring veterinarian/sonographer. No evaluation can be communicated regarding pathology that was not visible in the image/video clips provided.

Thank you for this referral. If the clinical or image interpretation does not parallel your findings or if I can be of any further assistance please contact me.

**Eric Lindquist**, DMV, DABVP, Cert. IVUSS, CEO of SonoPath.com  
info@SonoPath.com