



PATIENT

Nala Hurley

SPECIES

Canine

BREED

German Shepherd

SEX

Spayed Female

AGE

7 Years

WEIGHT

38 Pounds

INTERPRETED BY

Eric Lindquist, DMV
DABVP, Cert. IVUSS

IMAGING PERFORMED BY

Dr. Carlos Abdul-Chani

HOSPITAL NAME

Byram AH

REFERRING VET

Dr. Carlos Abdul-Chani

INVOICE

33933

DATE

1/3/22

PRESENTING CLINICAL SIGNS

Reason for US: Chronic diarrhea and wt. loss Current Meds: Metronidazole 250mg BID, Hills I/D low fat diet CBC/Chem findings: CBC - normal, Chem - Alb 2.6 g/dl rest in WNL, TLI = normal, B12 =L150, Folate = 13.5

ULTRASONOGRAPHIC EXAMINATION OF THE ABDOMEN

Urinary System

The **urinary bladder**, trigone, and pelvic urethra presented normal thicknesses and normal tone. The ureters were not visible which is normal. No uroliths or sediment were visualized and anechoic urine was present. No evidence of inflammatory or neoplastic changes were noted. Ureteral papillae were normal.

The **kidneys** revealed normal size and structure, corticomedullary definition and ratio for this age. The cortices presented largely uniform texture with normal echogenic relationship to liver and spleen. Medullary structure differed distinctly from the cortex and no evidence of pelvic dilation was present. The capsules were acceptably uniform without significant irregularities. The right kidney measured 6.61 cm. The left kidney measured 6.53 cm.

Adrenal Glands

Both **adrenal glands** were visualized and recognized as having normal shape, size, position and echogenicity for this breed. The phrenic vasculature, glandular echogenicity and detail were unremarkable. Capsule, cortex, and medullary definition were normal for this age patient. The left adrenal gland measured 2.83 cm x 0.65 cm at the caudal pole and 0.51 cm at the cranial pole. The right adrenal gland measured 3.01 cm x 1.37 cm at the cranial pole and 0.57 cm at the caudal pole.

Spleen

The **spleen** was folded upon itself cranially.

Liver

The **liver** images submitted revealed subjectively normal liver size, contour, and structure. Parenchymal echogenicity was naturally coarse and hypoechoic to the spleen. Vascular and biliary tracts were of normal volume with no evidence of congestion. The gallbladder presented acceptably thin walls with primarily anechoic content. The cystic and common bile ducts were normal. No pathological hepatic lymphadenopathy was evident. No overt structural evidence of inflammatory, infiltrative or regenerative pathology was evident.

Gastrointestinal

Stasis was noted in the **stomach** with some echogenic luminal material, consistent with kibble. However, foreign matter cannot be completely ruled out. The largest structure measured approximately 2.0 cm. Variable small intestinal thickening noted without loss of mural detail. However, increased muscularis thickening noted with areas of 1:1 muscularis/mucosa ratio and trace free fluid. Reactive mesenteric lymph nodes noted at 2.0 cm x 0.5 cm.

Pancreas

The base and limbs of the **pancreas** were observed to be largely isoechoic to surrounding omental fat. Pancreatic duct and capsular contour were acceptably normal and parenchyma respected normal curvilinear patterns. No overt evidence of active inflammatory or neoplastic disease was noted.



PATIENT

Nala Hurley

ULTRASONOGRAPHIC FINDINGS

- Retention of ingesta in the stomach and diffuse inflammatory bowel type presentation with hypertrophied muscularis and reactive mesentery

SPECIES

Canine

INTERPRETATION OF THE FINDINGS & FURTHER RECOMMENDATIONS

Malassimilation of nutrients suspected in this patient. No evidence of neoplasia. If the patient was NPO at the time of the sonogram, foreign matter may be present in the stomach. However, the echotexture is that of kibble or similar. I recommend a fresh fecal smear and fecal floatation analysis and broad-spectrum antiparasitic. Maldigestion panel warranted. Purina HA or Royal Canin HP diet or similar recommended. Pancreatic supplementation and B12 injections could all be considered empirically.

BREED

German Shepherd

For an additional charge, internal medicine consult can be utilized through SonoPath.com. You can select the internal medicine drop down at <http://spa.sonopath.com/>.

SEX

Spayed Female

One of the world's top internists & SonoPath associate Dr. Remo Lobetti BVSc, MMedVet, PhD, DECVIM can evaluate your case through SonoPath. <https://sonopath.com/resources/sonopath-services/internal-medicine-teleconsultation-services>

AGE

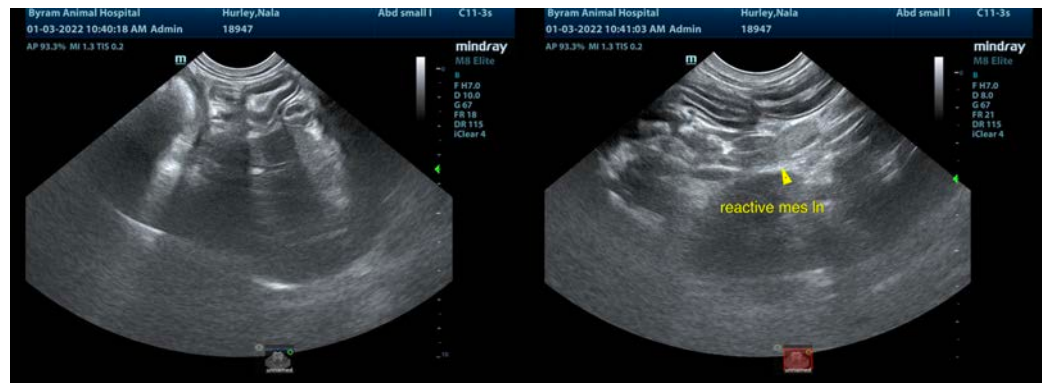
7 Years

WEIGHT

38 Pounds

INTERPRETED BY

Eric Lindquist, DMV
DABVP, Cert. IVUSS



IMAGING PERFORMED BY

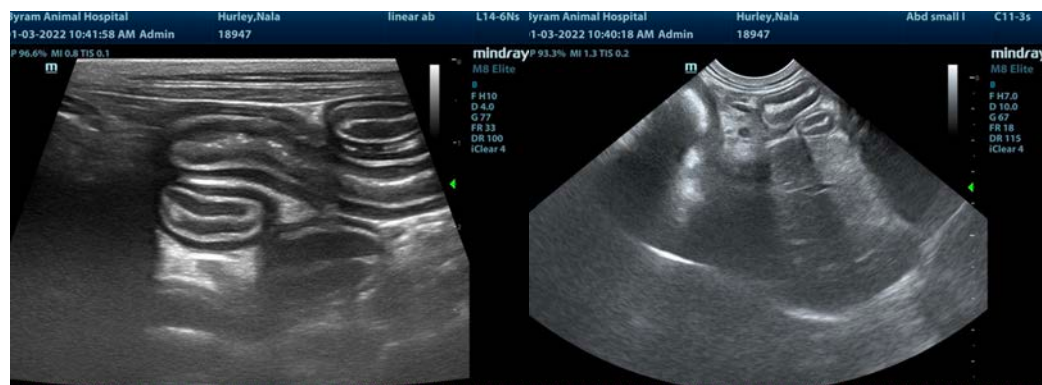
Dr. Carlos Abdul-Chani

HOSPITAL NAME

Byram AH

REFERRING VET

Dr. Carlos Abdul-Chani



INVOICE

33933

DATE

1/3/22



PATIENT

Nala Hurley

SPECIES

Canine

BREED

German Shepherd

SEX

Spayed Female

AGE

7 Years

WEIGHT

38 Pounds

INTERPRETED BY

Eric Lindquist, DMV
DABVP, Cert. IVUSS

IMAGING PERFORMED BY

Dr. Carlos Abdul-Chani

HOSPITAL NAME

Byram AH

REFERRING VET

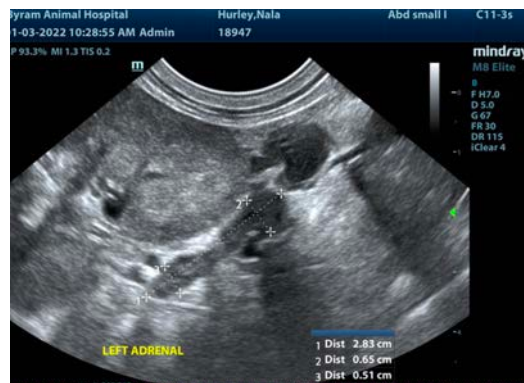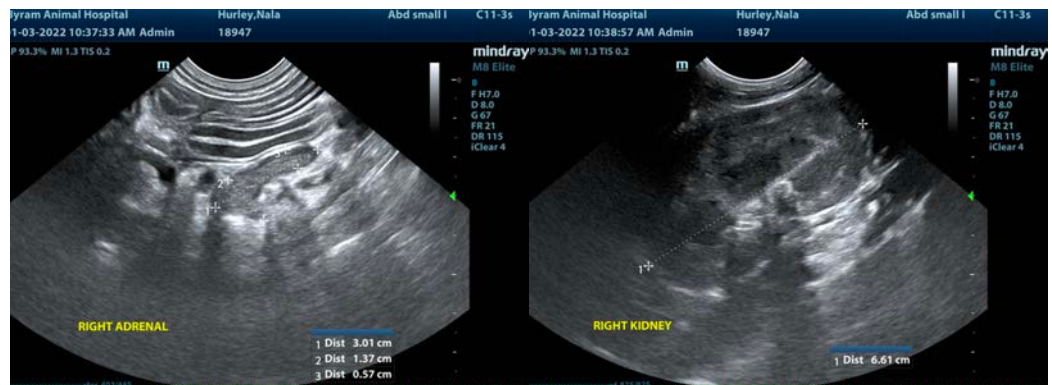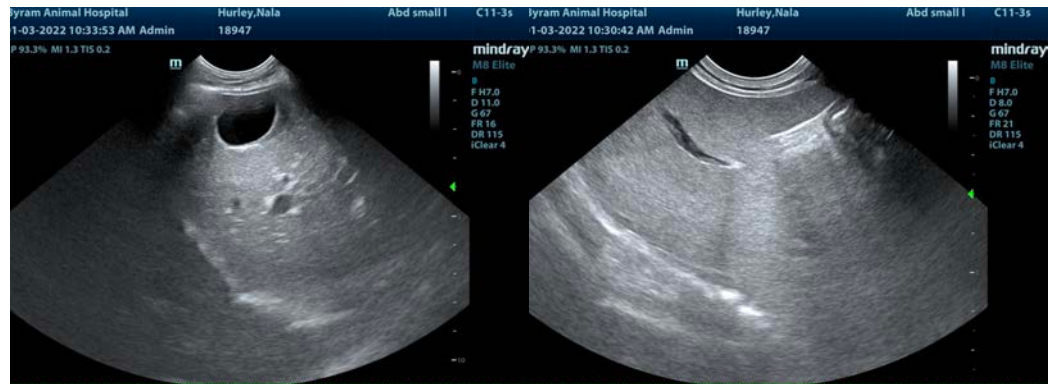
Dr. Carlos Abdul-Chani

INVOICE

33933

DATE

1/3/22



The information and recommendations provided are based on the images presented by the referring veterinarian. No evaluation can be communicated regarding pathology that was not visible in the image/video clips provided.

Thank you for this referral. If the clinical or image interpretation does not parallel your findings or if I can be of any further assistance please contact me.

Eric Lindquist, DMV, DABVP, Cert. IVUSS, CEO of SonoPath.com
info@SonoPath.com