



PATIENT PRESENTING CLINICAL SIGNS

PATIENT
Max Barila
Intermittent decreased appetite for the past year. Blood work in Feb. unremarkable. Mildly tense on abdominal palpation (cranial), no appetite for 2 days, vomited twice. Meds: had mirtazapine 3.75mgs and Cerenia once on 12/31/21

SPECIES
Abnormal PE/Chem/CBC/UA Results: New CBC/Chem: pending.

Feline

ULTRASONOGRAPHIC EXAMINATION OF THE ABDOMEN

BREED *Urinary System*

DSH
The **urinary bladder**, trigone, and pelvic urethra presented normal thicknesses and normal tone. The ureters were not visible which is normal. No uroliths or sediment were visualized and anechoic urine was present. No evidence of inflammatory or neoplastic changes were noted. Ureteral papillae were normal.

SEX

Neutered Male
The **kidneys** revealed largely normal size and structure, corticomedullary definition and ratio (cortex 1/3 of medulla) were essentially maintained with some age-related loss of curvilinear patterns regarding the capsule and C/M junction. The cortices presented largely uniform texture with some increased echogenicity expected for his age patient. Medullary structure differed distinctly from that of the cortex and no evidence of pelvic dilation was present. The right kidney measured 3.76 cm.

AGE

17 Years

Adrenal Glands

WEIGHT

11.6 Pounds

Both **adrenal glands** were visualized and recognized as having normal shape, size, position and echogenicity for this breed. The phrenic vasculature, glandular echogenicity and detail were unremarkable. Capsule, cortex, and medullary definition were normal for this age patient. The right adrenal gland measured 0.37 cm. The left adrenal gland measured 0.44 cm.

INTERPRETED BY

Eric Lindquist, DMV
DABVP, Cert. IVUSS

Spleen

The **spleen** presented a smooth homogeneous parenchyma hyperechoic to liver and renal cortical parenchyma. The spleen measured 0.9 cm. The capsule was smooth without noticeable expansion or deviation from within the spleen or adjacent pathology. The splenic vasculature demonstrated normal volume without signs of congestion or thrombosis. No sonographic evidence of acute or chronic inflammatory, neoplastic, or infarctual changes were noted.

IMAGING PERFORMED BY

Kelly Vazquez

Liver

The **liver** presented slight coarse architecture with minor increased portal markings. The gallbladder and common bile duct were normal.

HOSPITAL NAME

Englewood Cliffs VH

Gastrointestinal

REFERRING VET

Dr. Rachel Park

The **gastrointestinal tract** revealed minor variable thickening and echogenic submucosal changes most consistent with low grade end result of chronic GI disease such as IBD and may be related to malassimilation of nutrients if any weight loss is present. A focal area of jejunum was mildly thickened with early loss of mural detail. This area should be monitored for progressive disease.

INVOICE

33932

Pancreas

The base and limbs of the **pancreas** were observed to be largely isoechoic to surrounding omental fat. Some parenchymal remodeling, however, with mild deviation from curvilinear normalcy was observed. Pancreatic duct and capsular irregularities were present consistent with age related changes. If pain upon imaging (+ Murphy sign) was present or if the patient is focally painful in subxyphoid palpation then low-grade smoldering chronic pancreatitis should be suspected.

DATE

1/3/22



PATIENT

Max Barila

SPECIES

Feline

BREED

DSH

SEX

Neutered Male

AGE

17 Years

WEIGHT

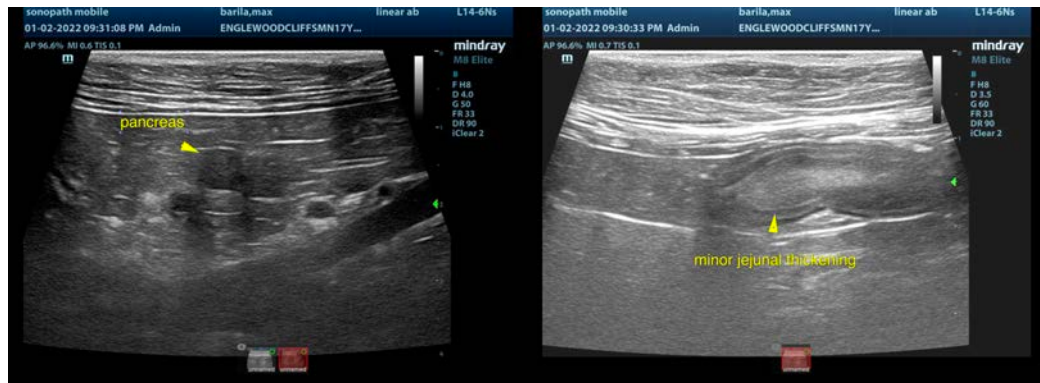11.6 Pounds

ULTRASONOGRAPHIC FINDINGS

- Essentially geriatric abdomen with minor area of jejunal thickening – focal active or history of enteritis suspected. Mild potential for emerging round cell neoplasia.
- Unremarkable abdomen otherwise

INTERPRETATION OF THE FINDINGS & FURTHER RECOMMENDATIONS

Supportive care for inflammatory bowel and periodic pancreatitis would be warranted in this patient. Pain management, broad-spectrum antibiotic therapy and fluid support as necessary. Hydrolyzed diet long-term may be necessary. An empirical protocol of Zithromax/Metronidazole suggested. Other causes of poor appetite such as orthopedic, thoracic or CNS disease should also be considered, as the changes in the abdomen are minor.



INTERPRETED BY

Eric Lindquist, DMV
DABVP, Cert. IVUSS

IMAGING PERFORMED BY

Kelly Vazquez

HOSPITAL NAME

Englewood Cliffs VH

REFERRING VET

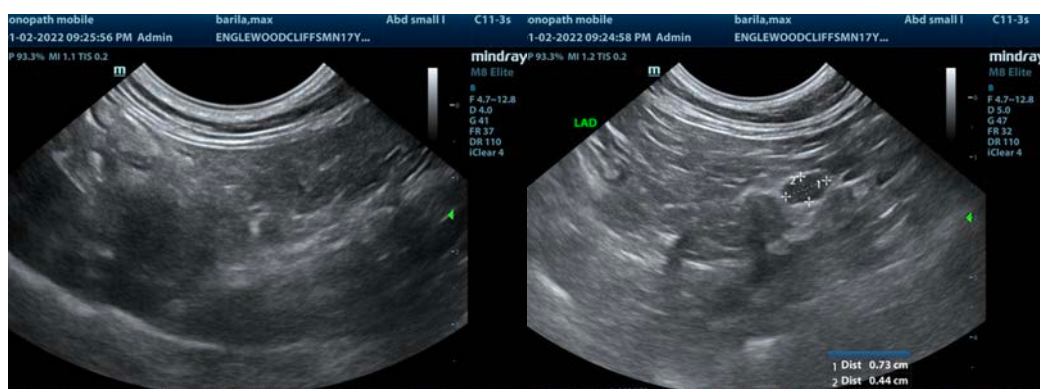
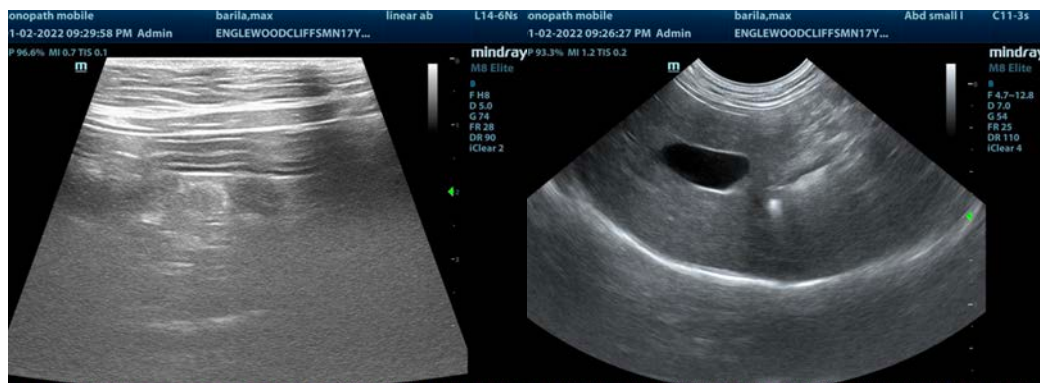Dr. Rachel Park

INVOICE

33932

DATE

1/3/22





PATIENT

Max Barila

SPECIES

Feline

BREED

DSH

SEX

Neutered Male

AGE

17 Years

WEIGHT

11.6 Pounds

INTERPRETED BY

Eric Lindquist, DMV
DABVP, Cert. IVUSS

IMAGING PERFORMED BY

Kelly Vazquez

HOSPITAL NAME

Englewood Cliffs VH

REFERRING VET

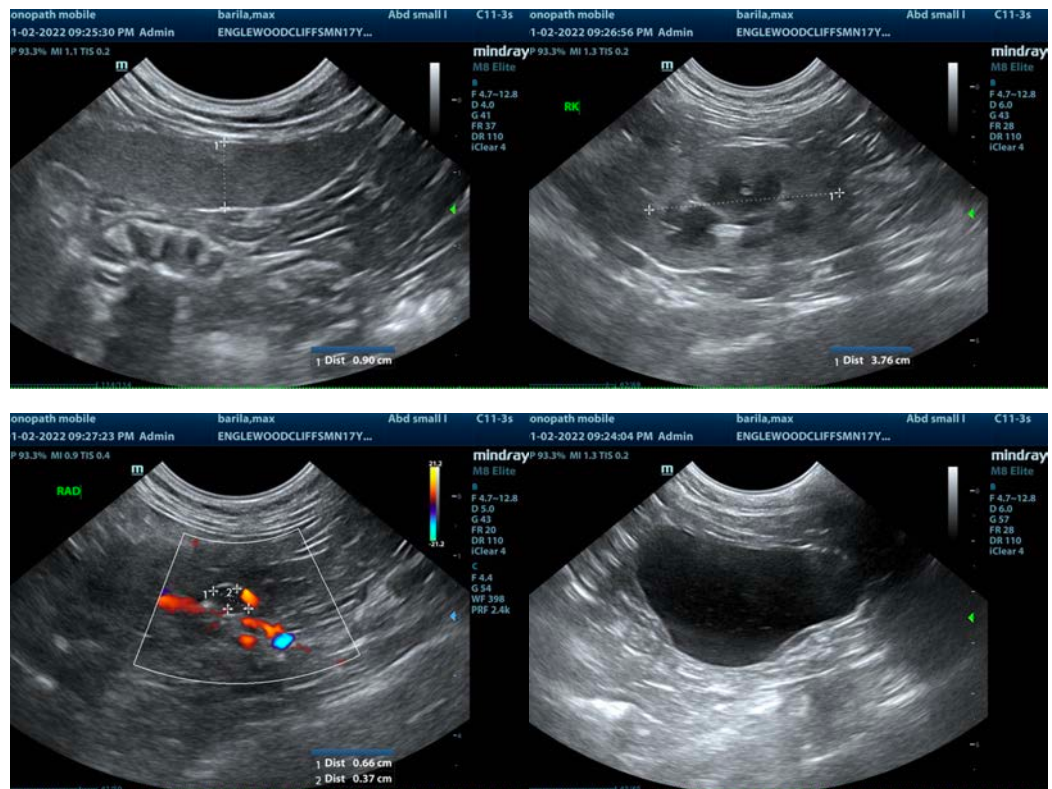
Dr. Rachel Park

INVOICE

33932

DATE

1/3/22



The information and recommendations provided are based on the images presented by the referring veterinarian. No evaluation can be communicated regarding pathology that was not visible in the image/video clips provided.

Thank you for this referral. If the clinical or image interpretation does not parallel your findings or if I can be of any further assistance please contact me.

Eric Lindquist, DMV, DABVP, Cert. IVUSS, CEO of SonoPath.com
info@SonoPath.com