PATIENT

Anderson Morin

SPECIES

Canine

BREED

Shiba Inu

SEX

Neutered male

AGE

16 years

WEIGHT

20.4 lbs

INTERPRETED BY

Eric Lindquist, DMV DABVP, Cert. IVUSS

IMAGING PERFORMED BY

Denise Bruno, LVT, RDMS

HOSPITAL NAME

Kenilworth AH

REFERRING VET

Dr. Mansour

INVOICE

71099

DATE

1/29/26

PRESENTING CLINICAL SIGNS

- Trachea pushed dorsally on X-ray. Evaluate neck for neoplasia. X-rays + Diagram attached.

ULTRASONOGRAPHIC EXAMINATION

9 still images and 4 videos were submitted

The left cervical region revealed a 2.73 cm, hypoechoic, enlarged lymph node and a similar enlarged 3.0 x 2.0 cm, hypoechoic enlarged lymph node in the right cervical region. Regional inflammation was noted. The lymph nodes appear to be encapsulated and undifferentiated. This is most consistent with retropharyngeal lymph nodes.

ULTRASONOGRAPHIC FINDINGS

- Retropharyngeal lymphadenopathy. Strong concern for underlying neoplasia.

INTERPRETATION OF THE FINDINGS & FURTHER RECOMMENDATIONS

Ultrasound-guided FNA of the lymph nodes are indicated for further definition. Chest radiographs and abdominal ultrasound are recommended to assess for staging of potential infiltrative disease.

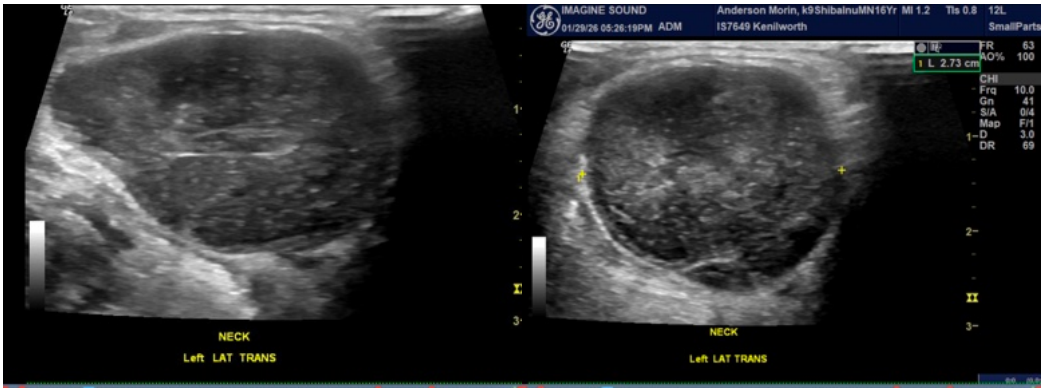

PATIENT

Anderson Morin

SPECIES

Canine

BREED

Shiba Inu

SEX

Neutered male

AGE

16 years

WEIGHT

20.4 lbs

INTERPRETED BY

Eric Lindquist, DMV DABVP, Cert. IVUSS

IMAGING PERFORMED BY

Denise Bruno, LVT, RDMS

HOSPITAL NAME

Kenilworth AH

REFERRING VET

Dr. Mansour

INVOICE

71099

DATE

1/29/26

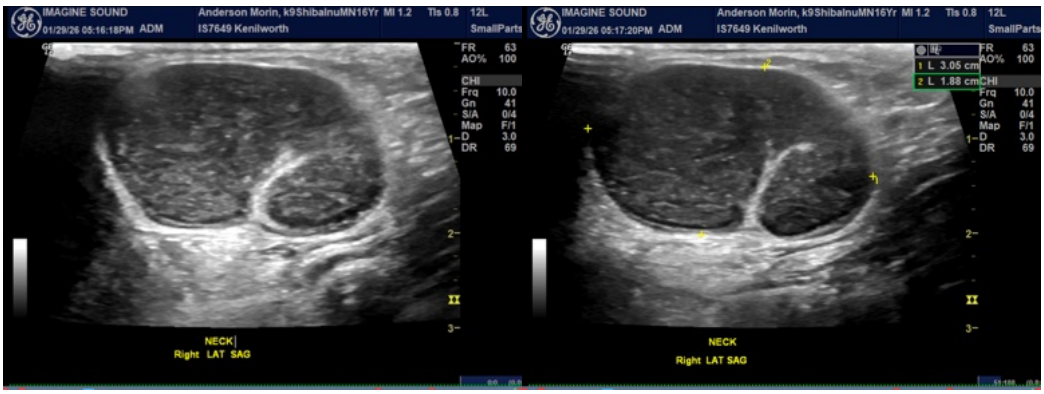

The information and recommendations provided are based on the images presented by the referring veterinarian/sonographer. No evaluation can be communicated regarding pathology that was not visible in the image/video clips provided.

Thank you for this referral. If the clinical or image interpretation does not parallel your findings or if I can be of any further assistance please contact me.

Eric Lindquist, DMV, DABVP, Cert. IVUSS, CEO of SonoPath.com

info@SonoPath.com