



PATIENT PRESENTING CLINICAL SIGNS

Nash Clegg Arrhythmia noted prior to CT for lameness. Holter monitor pending. Current meds: Rimadyl, Gabapentin
Abnormal PE/Chem/CBC/UA Results: Pending

SPECIES

Canine

ULTRASONOGRAPHIC EXAMINATION OF THE HEART

BREED

Bull Mastiff

The echocardiogram in this patient demonstrated normal **left atrial** size based on 3 different LA measurement methods. Chamber volumes and echogenicity were normal. The cranial and caudal **mitral** valve leaflets presented vegetative thickening consistent with endocardiosis. Doppler indicated measurable insufficiency. The **left ventricle** presented thicknesses with linear contour and was not dilated nor restricted. The **myocardium** presented normal echogenicity without subjective evidence of significant fibrotic or ischemic disease. **Contractility** of the ventricular walls was adequate and in normal range for this patient evidenced by the fractional shortening measurement and subjective evaluation of the different regions of the myocardium. The **left ventricular outflow** tract demonstrated normal laminar flow and subjective structural integrity. The **right atrium** and auricle revealed normal size, structure and content. No evidence of masses was noted or chamber overload. **Tricuspid** valvular assessment demonstrated adequate linear morphology. The **right ventricle** was of normal size (1/3 diameter of LV), chordae structure, myocardial echogenicity and thickness. **Pulmonic** tract assessment revealed normal valve structure, laminar flow, and diameter (approx.1:1 pa/ao ratio). No visible **pericardial** or free pleura fluid was noted. No echographically detectable evidence of infiltrative disease was visible. The cranial **mediastinum and pericardial regions** were free of masses in the visible window. Periodic arrhythmia was noted in this patient that is affecting the fractional shortening.

SEX

Neutered male

AGE

10 years

WEIGHT

95 ;bs

INTERPRETED BY

Eric Lindquist, DMV
DABVP, Cert. IVUSS

IMAGING PERFORMED BY

Shari Reffi, CVT

HOSPITAL NAME

VCA Blairstown AH

REFERRING VET

Dr. Clegg

CANINE CARDIAC PARAMETERS	MR VMAX (m/s)	TR VMAX (m/s)	LA/AO (Boon method)	LA/AO (Heart Base; Swe)	FS (%)	EF (%)	EPSS (cm)
NORMAL PARAMETER	4.5-5.5	<2.7	1.3	<1.6	28-40	40-100	<0.6
PATIENT	5.0		1.2	1.32	21	42	0.69
CANINE CARDIAC PARAMETERS	HR (BPM)	AV VMAX (m/s)	PV MAX (m/s)	BODY WEIGHT (kg)	LA 2D short axis Base view (cm)	LVIDd Avg; 2D and m-mode short axis (cm)	LVIDs Avg; 2D and m-mode short axis (cm)
NORMAL PARAMETER	50-100	0.7-1.7	0.7-1.6				
PATIENT		1.53	1.0		5.0	4.81	

INVOICE

95597

ULTRASONOGRAPHIC FINDINGS

DATE

1/28/22

Minor stage B1 valvular disease.



PATIENT

Nash Clegg

SPECIES

Canine

BREED

Bull Mastiff

SEX

Neutered male

AGE

10 years

WEIGHT

95 ;bs

INTERPRETED BY

Eric Lindquist, DMV
DABVP, Cert. IVUSS

IMAGING PERFORMED BY

Shari Reffi, CVT

HOSPITAL NAME

VCA Blairstown AH

REFERRING VET

Dr. Clegg

INVOICE

95597

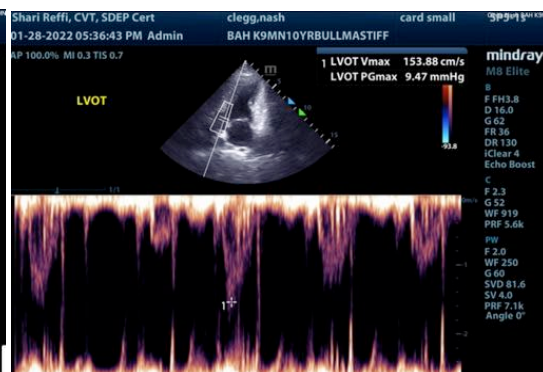
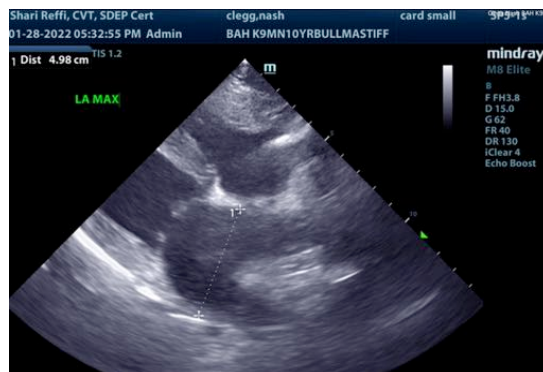
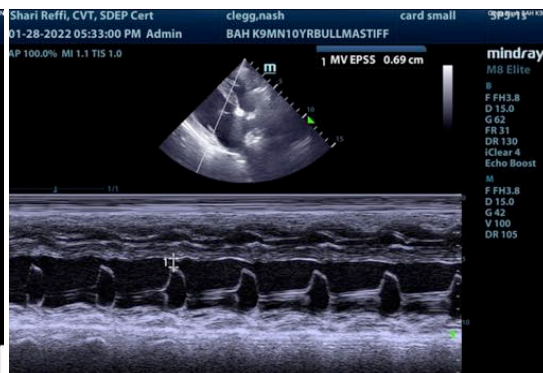
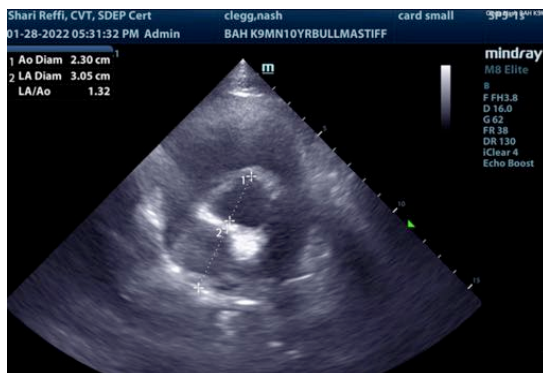
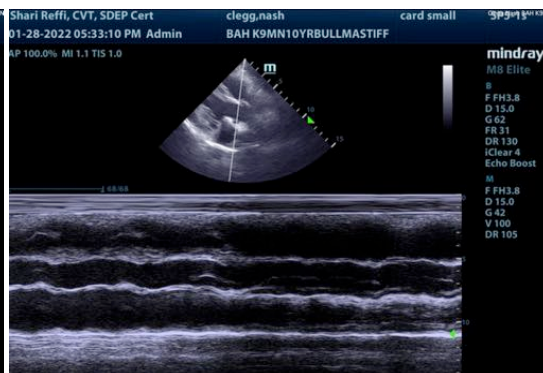
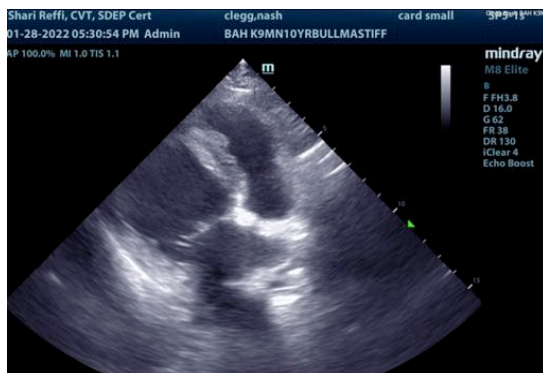
DATE

1/28/22

INTERPRETATION OF THE FINDINGS & FURTHER RECOMMENDATIONS

There is no significant volume overload. Periodic hypocontractility was noted owing to arrhythmogenic activity. Primary treatment of the arrhythmia is recommended. Holter monitor is ideal and can be obtained from our office. No specific cardiac treatment is recommended. The arrhythmia appears to be fairly significant. Therefore, anti-arrhythmic therapy will likely be necessary. The arrhythmia may be lethal.

B1: The heart is stable without clinical disease. No overt contraindication for anesthesia of brief to moderate duration. I suggest Torbutrol premed, Propofol induction, Isoflurane maintenance or similar protocol if anesthesia is desired. Blood pressure recommended if not already performed and target white coat negative systolic pressure of < 160 mmHg. If higher than this ACE-inhibitor is suggested to reach this level. Recheck echocardiogram is recommended in 6 months, earlier if murmur grade increases or clinical signs initiate.





PATIENT

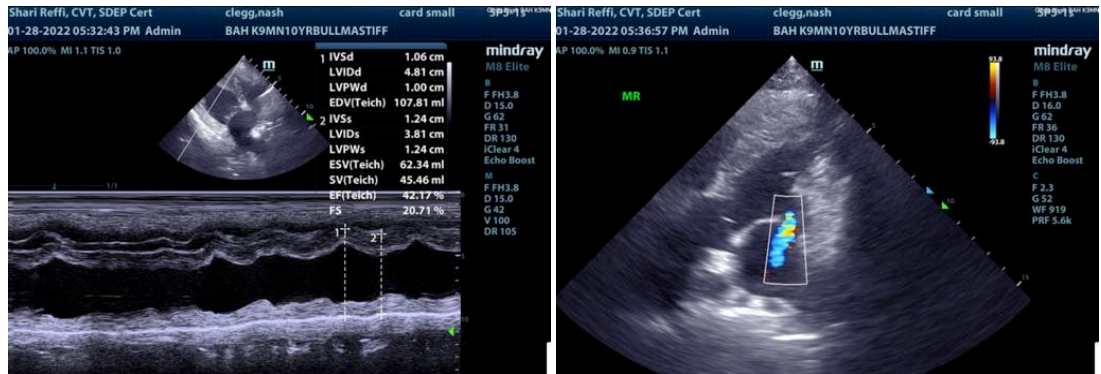
Nash Clegg

SPECIES

Canine

BREED

Bull Mastiff



SEX

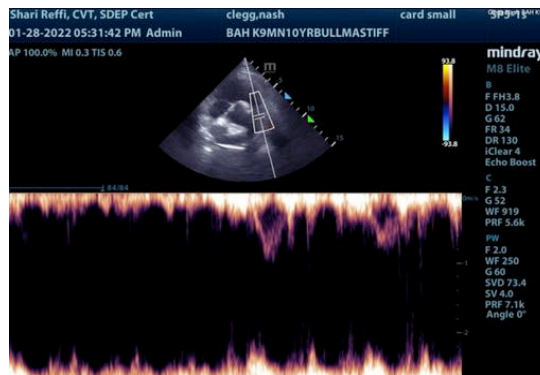
Neutered male

AGE

10 years

WEIGHT

95 ;bs



INTERPRETED BY

Eric Lindquist, DMV
DABVP, Cert. IVUSS

IMAGING PERFORMED BY

Shari Reffi, CVT

HOSPITAL NAME

VCA Blairstown AH

REFERRING VET

Dr. Clegg

INVOICE

95597

DATE

1/28/22

The information and recommendations provided are based on the images presented by the referring veterinarian/sonographer. No evaluation can be communicated regarding pathology that was not visible in the image/video clips provided.

Thank you for this referral. If the clinical or image interpretation does not parallel your findings or if I can be of any further assistance please contact me.

Eric Lindquist, DMV, DABVP, Cert. IVUSS, CEO of SonoPath.com
Info@SonoPath.com