



PATIENT

Jameson Gorman

PRESENTING CLINICAL SIGNS

acute onset lethargy, head tilt, hypersalivation, elevated liver enzymes

SPECIES

Canine

ULTRASONOGRAPHIC EXAMINATION OF THE ABDOMEN

Urinary System

The **urinary bladder**, trigone, and pelvic urethra presented normal thicknesses and normal tone. The ureters were not visible which is normal. No uroliths or sediment were visualized and anechoic urine was present. No evidence of inflammatory or neoplastic changes were noted. Ureteral papillae were normal. The pelvic urethra was imaged 2.0 cm beyond the cystourethral junction.

BREED

Pit Bull X

SEX

Neutered Male

The **kidneys** revealed largely normal size and structure, corticomedullary definition and ratio (cortex 1/3 of medulla) were essentially maintained with some age-related loss of curvilinear patterns regarding the capsule and C/M junction. The cortices presented largely uniform texture with some increased echogenicity expected for his age patient. Medullary structure differed distinctly from that of the cortex and no evidence of pelvic dilation was present. The right kidney measured 7.08 cm. The left kidney measured 7.32 cm.

AGE

10 Years

Adrenal Glands

Both **adrenal glands** were visualized and recognized as having largely normal shape, size, position and acceptable echogenicity for this age group and breed. Some heterogeneity was noted within the adrenal parenchyma without concerning capsular distortion. These changes are likely age related but should be monitored by sonogram should the patient be suspected of having adrenal disease. The left adrenal gland measured 2.77 cm x 0.76 cm at the caudal pole and 0.83 cm at the cranial pole. The right adrenal gland measured 4.04 cm x 1.76 cm at the cranial pole and 0.71 cm at the caudal pole.

WEIGHT

85 Pounds

INTERPRETED BY

Eric Lindquist, DMV

Spleen

The **spleen** presented a smooth homogeneous parenchyma hyperechoic to liver and renal cortical parenchyma. The capsule was smooth without noticeable expansion or deviation from within the spleen or adjacent pathology. The splenic vasculature demonstrated normal volume without signs of congestion or thrombosis. No sonographic evidence of acute or chronic inflammatory, neoplastic, or infarctual changes were noted.

DABVP, Cert. IVUSS

IMAGING PERFORMED BY

Diane McFadden

Liver

HOSPITAL NAME

Rockaway AH

The **liver** images submitted revealed subjectively normal liver size, contour, and structure. Parenchymal echogenicity was naturally coarse and hypoechoic to the spleen. Vascular and biliary tracts were of normal volume with no evidence of congestion. The gallbladder presented acceptably thin walls with primarily anechoic content. The cystic and common bile ducts were normal. No pathological hepatic lymphadenopathy was evident. No overt structural evidence of inflammatory, infiltrative or regenerative pathology was evident.

REFERRING VET

Dr. Maniar

Gastrointestinal

INVOICE

35167

Examination of the **gastrointestinal tract** revealed a stomach and intestine free of stasis, of normal wall thickness, acceptable curvilinear mural detail, and peristaltic activity. Small and large intestine demonstrated normal luminal chyme and stool consistency respectively. No obstructive or overt infiltrative disease was noted. No associated abnormal lymphatic activity was noted.

DATE

1/28/22



PATIENT

Pancreas

Jameson Gorman

Diffuse hyperechoic changes were present in the area of the **pancreas**. The pancreatic remodeling was evident with multifocal to diffuse hyperechoic changes. These changes are consistent with fibrosis, amyloid, saponification of fat and may contain areas of low-grade chronic active inflammation especially if pain on imaging (+ Murphy sign) was present +/- focal subxyphoid palpation reveals pain response. No overt masses were noted.

SPECIES

Canine

BREED

Pit Bull X

- Structurally unremarkable abdomen
- Age related changes with pancreatic remodeling

ULTRASONOGRAPHIC FINDINGS

INTERPRETATION OF THE FINDINGS & FURTHER RECOMMENDATIONS

SEX

Given the patient history, CT of the CNS warranted.

Neutered Male

SonoPath CT Services are offered at the Blairstown Animal Hospital. Blairstown animal hospital is just a 30-minute drive west on route 80 from the route 80/287 interchange/Parsippany, New Jersey. More information can be found at:

AGE

10 Years

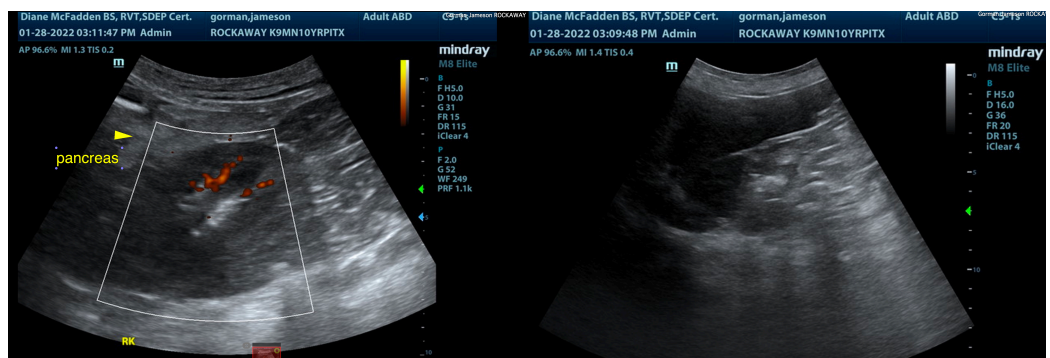
<https://sonopath.com/resources/sonopath-teleconsultation-services-and-sdep-certification/sonopath-ct-services>

WEIGHT

85 Pounds

INTERPRETED BY

Eric Lindquist, DMV
DABVP, Cert. IVUSS



IMAGING PERFORMED BY

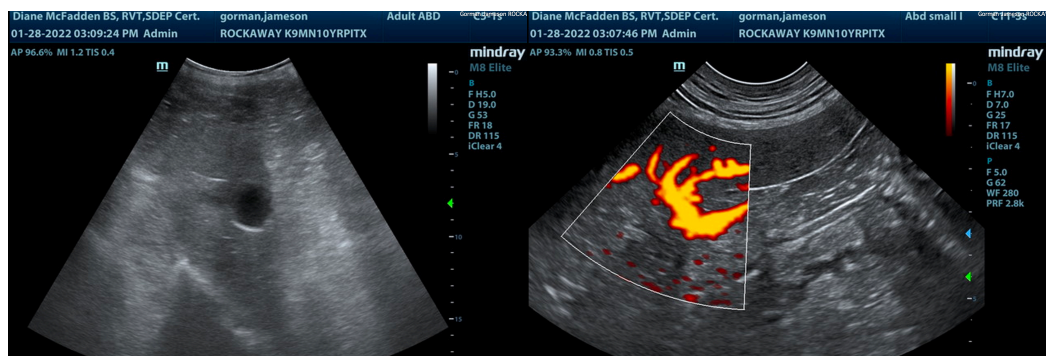
Diane McFadden

HOSPITAL NAME

Rockaway AH

REFERRING VET

Dr. Maniar



INVOICE

35167

DATE

1/28/22



PATIENT

Jameson Gorman

SPECIES

Canine

BREED

Pit Bull X

SEX

Neutered Male

AGE

10 Years

WEIGHT

85 Pounds

INTERPRETED BY

Eric Lindquist, DMV
DABVP, Cert. IVUSS

IMAGING PERFORMED BY

Diane McFadden

HOSPITAL NAME

Rockaway AH

REFERRING VET

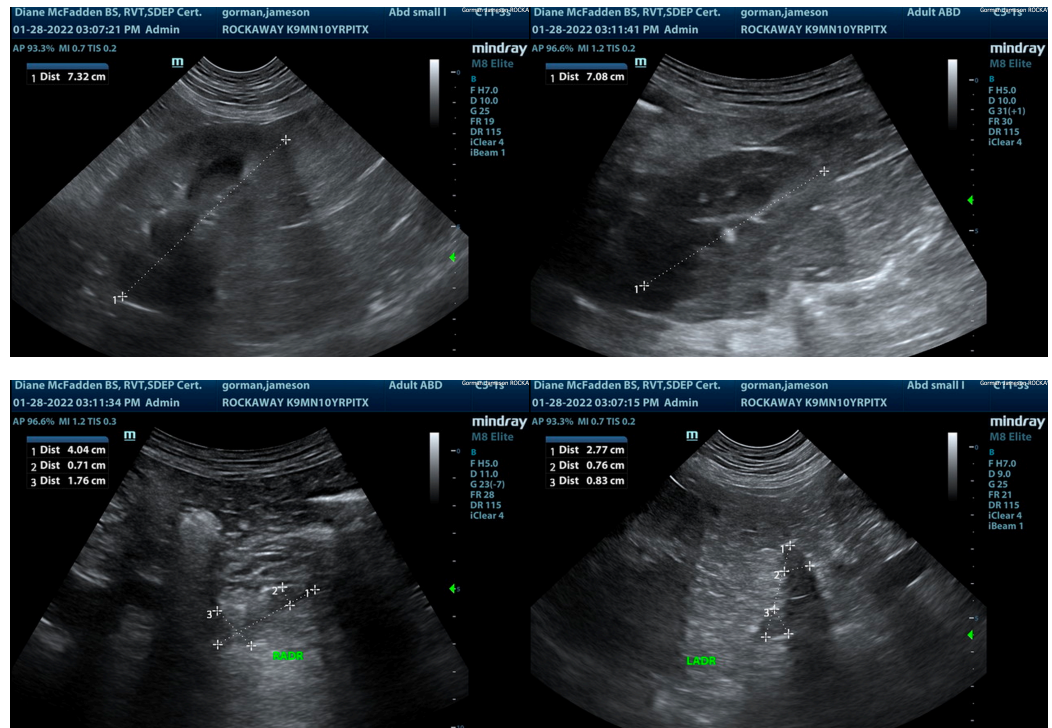
Dr. Maniar

INVOICE

35167

DATE

1/28/22



The information and recommendations provided are based on the images presented by the referring veterinarian/sonographer. No evaluation can be communicated regarding pathology that was not visible in the image/video clips provided.

Thank you for this referral. If the clinical or image interpretation does not parallel your findings or if I can be of any further assistance please contact me.

Eric Lindquist, DMV, DABVP, Cert. IVUSS, CEO of SonoPath.com

info@SonoPath.com