



PATIENT PRESENTING CLINICAL SIGNS

PATIENT
Dixie Bock
lethargic, walking more slowly, not eating well, vomiting last few days, jaundice, new puppy in house about 3 weeks ago

SPECIES
Canine
Abnormal PE/Chem/CBC/UA Results: elevated liver values, leptospirosis test pending, elevated bilirubin and GGT, low PLT confirmed on slides...seems adequate - BW sent to lab to confirm. BUN 33, Crea 2.0, ALT 947, ALP 6158, GGT 15, Bili 9.8.

Abdominal radiographs – Unremarkable, minor hepatomegaly, slight irregular spleen.

BREED ULTRASONOGRAPHIC EXAMINATION OF THE ABDOMEN

Mixed Urinary System

The **urinary bladder**, trigone, and pelvic urethra presented normal thicknesses and normal tone. The ureters were not visible which is normal. No uroliths or sediment were visualized and anechoic urine was present. No evidence of inflammatory or neoplastic changes were noted. Ureteral papillae were normal. The pelvic urethra was imaged 2.0 cm beyond the cystourethral junction.

SEX

Spayed Female

The **kidneys** were swollen with slight pericapsular enhanced mesentery, suggestive for nephritis, very non-specific. Some loss of corticomedullary definition noted. The right kidney measured 6.3 cm.

AGE

12 Years

Adrenal Glands

The **left adrenal gland** was visualized and recognized as having normal shape, size, position and echogenicity for this breed. The phrenic vasculature, glandular echogenicity and detail were unremarkable. Capsule, cortex, and medullary definition were normal for this age patient. The left adrenal gland measured 0.76 cm.

WEIGHT

49 Pounds

The **right adrenal gland** was slightly irregular, primarily at the phrenic vein. This should be monitored carefully and rechecked. The right adrenal gland measured 3.05 cm x 0.89 cm at the cranial pole and 0.65 cm at the caudal pole.

INTERPRETED BY

Eric Lindquist, DMV

Spleen

The **spleen** was slightly swollen with minor heterogeneous parenchymal changes.

DABVP, Cert. IVUSS

IMAGING PERFORMED BY

Adrienne Ligenza

Liver

The **liver** was swollen and hypoechoic to falciform fat. The gallbladder wall was slightly echogenic and thickened. Mild increased portal markings noted.

HOSPITAL NAME

Rush Vet Urgent Care

Gastrointestinal

Examination of the **gastrointestinal tract** revealed a stomach and intestine free of stasis, of normal wall thickness, acceptable curvilinear mural detail, and peristaltic activity. Small and large intestine demonstrated normal luminal chyme and stool consistency respectively. No obstructive or overt infiltrative disease was noted. No associated abnormal lymphatic activity was noted.

REFERRING VET

Dr. Taylor Urban

Pancreas

INVOICE

35156

The base and limbs of the **pancreas** were observed to be largely isoechoic to surrounding omental fat. Pancreatic duct and capsular contour were acceptably normal and parenchyma respected normal curvilinear patterns. No overt evidence of active inflammatory or neoplastic disease was noted.

DATE

1/28/22

ULTRASONOGRAPHIC FINDINGS

- Non-specific hepatitis and nephritis with reactive spleen



PATIENT

Dixie Bock

INTERPRETATION OF THE FINDINGS & FURTHER RECOMMENDATIONS

Acute insult (infectious or toxin exposure) should be considered, such as Leptospirosis. FNA of the liver warranted. Ampicillin/Metronidazole, nutraceuticals all indicated. No obvious evidence of neoplasia.

SPECIES

Canine

BREED

Mixed

SEX

Spayed Female

AGE

12 Years

WEIGHT

49 Pounds

INTERPRETED BY

Eric Lindquist, DMV

DABVP, Cert. IVUSS

IMAGING PERFORMED BY

Adrienne Ligenza

HOSPITAL NAME

Rush Vet Urgent Care

REFERRING VET

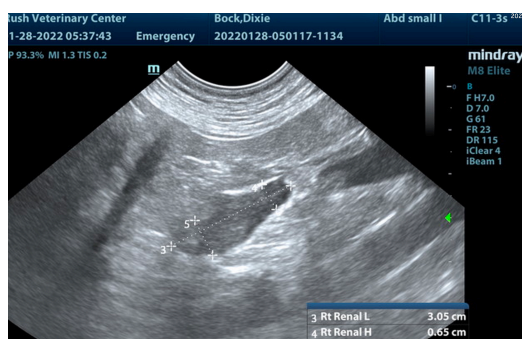
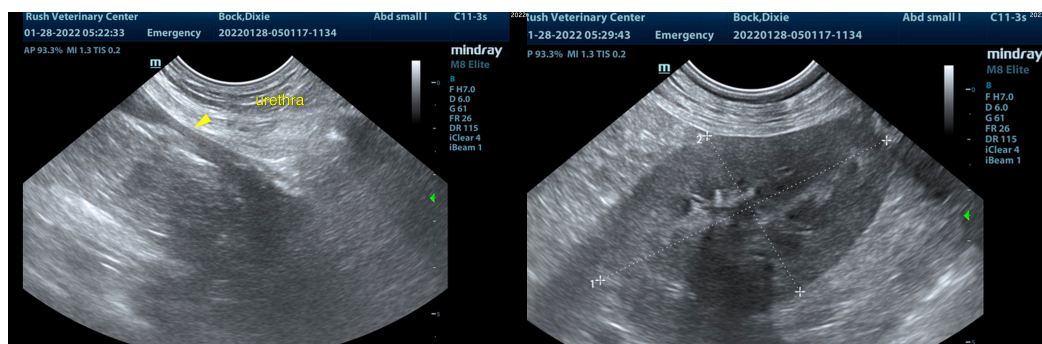
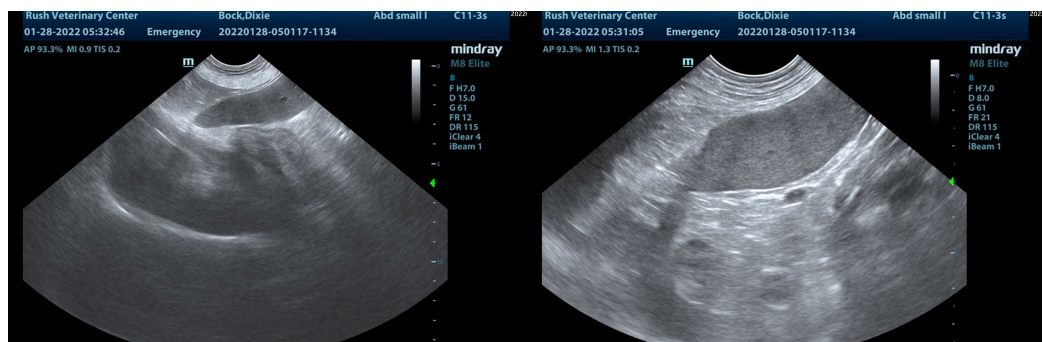
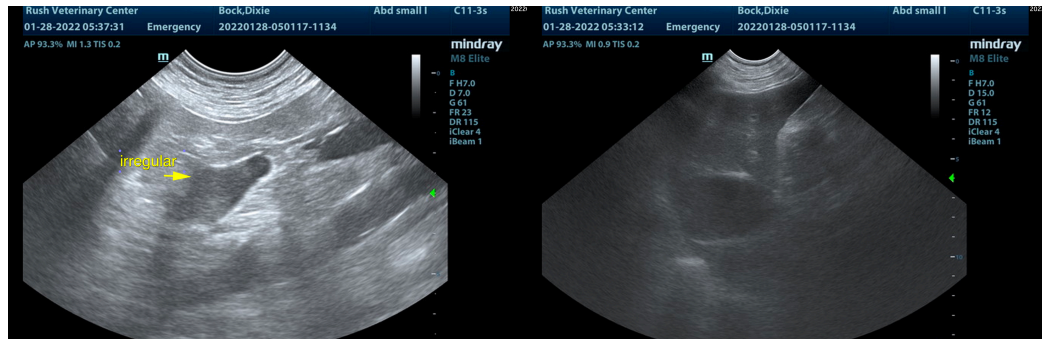
Dr. Taylor Urban

INVOICE

35156

DATE

1/28/22





PATIENT

Dixie Bock

The information and recommendations provided are based on the images presented by the referring veterinarian/sonographer. No evaluation can be communicated regarding pathology that was not visible in the image/video clips provided.

SPECIES

Canine

Thank you for this referral. If the clinical or image interpretation does not parallel your findings or if I can be of any further assistance please contact me.

Eric Lindquist, DMV, DABVP, Cert. IVUSS, CEO of SonoPath.com

info@SonoPath.com

BREED

Mixed

SEX

Spayed Female

AGE

12 Years

WEIGHT

49 Pounds

INTERPRETED BY

Eric Lindquist, DMV

DABVP, Cert. IVUSS

IMAGING PERFORMED BY

Adrienne Ligenza

HOSPITAL NAME

Rush Vet Urgent Care

REFERRING VET

Dr. Taylor Urban

INVOICE

35156

DATE

1/28/22