**DATE**

1/27/23

**PRESENTING CLINICAL SIGNS**

1/19/12: vomiting more than usual x2-3 weeks; ropey intestine. 1/23/23: not eating as much, vomited a lot of fluid yesterday; ropey intestines.

**PATIENT**

Stone Barthelme

Current Medications: 1/19/23: Cerenia 5.4mg SQ, Buprenorphine 0.04mg SQ, I/D diet. Cerenia 24mg ½ SID, Gabapentin 25mg q12-24hrs. 1/23/23: Cerenia 5.4mg SQ, Buprenorphine 0.04mg SQ, oral Buprenorphine 0.3mg/mL, 0.1mL BID, Elura 20mg/mL 0.55mL SID; Hold on Gabapentin.

Lab Results: 1/19/23: Chem NSF, CBC NSF, T4 2.8, Fpl abnormal.

Date of Previous IntraPet Ultrasound: No previous.

Sedation: Not required to complete full diagnostic ultrasound.

Stat Report: Not requested.

Imaging Performed By: Rachel Brillhart, RDMS.

**SPECIES**

Feline

**BREED**

Domestic Shorthair

**ULTRASONOGRAPHIC EXAMINATION OF THE ABDOMEN****Urinary System**

The **urinary bladder**, trigone, and pelvic urethra presented normal thicknesses and normal tone. The ureters were not visible which is normal. No uroliths or sediment were visualized and anechoic urine was present. No evidence of inflammatory or neoplastic changes was noted. Ureteral papillae were normal.

**SEX**

Neutered male

The **kidneys** revealed normal size and structure, corticomedullary definition and ratio for this age. The cortices presented largely uniform texture with normal echogenic relationship to liver and spleen. Medullary structure differed distinctly from the cortex and no evidence of pelvic dilation was present. The capsules were acceptably uniform without significant irregularities. The left kidney measured 4.12 cm. The right kidney measured 4.14 cm.

**AGE**

8/14/07

**WEIGHT**

12 lbs

**Adrenal Glands**

Both **adrenal glands** were visualized and recognized as having normal shape, size, position and echogenicity for this breed. The phrenic vasculature, glandular echogenicity and detail were unremarkable. Capsule, cortex, and medullary definition were normal for this age patient.

**INTERPRETED BY**

Eric Lindquist, DMV  
DABVP, Cert. IVUSS

**Spleen**

The **spleen** presented a smooth homogeneous parenchyma hyperechoic to liver and renal cortical parenchyma. The capsule was smooth without noticeable expansion or deviation from within the spleen or adjacent pathology. The splenic vasculature demonstrated normal volume without signs of congestion or thrombosis. No sonographic evidence of acute or chronic inflammatory, neoplastic, or infarctual changes was noted.

**HOSPITAL NAME**

Jacksonville VH

**REFERRING VET**

Dr. Kablis

**Liver**

The **liver** images from right and left intercostal as well as subcostal views revealed subjectively normal liver size, contour, and structure. Some age-related parenchymal remodeling was noted but likely not clinically significant at this time. Vascular and biliary tracts were of normal volume and no evidence of congestion was noted. The gallbladder presented some dependent debris with essentially normal contour. The cystic and common bile ducts were normal. No overt evidence of active inflammatory, infiltrative or regenerative pathology was noted but should be paired with current or past LE elevations regarding any clinical significance to this presentation. The hepatic lymph nodes were unremarkable. Slight free fluid was noted between the liver lobes.

**INVOICE**

42370

### ***Gastrointestinal***

The **gastrointestinal** presentation revealed mild uniform prominence of the gastric mucosa as well as areas of "ropey" small intestinal wall. The muscularis layer was hypertrophied inverting the normal ratio (1:3). The intestinal submucosa was slightly irregular, thickened and hyperechoic suggestive of low grade, chronic inflammation. No evidence of obstruction was present. Chronic inflammatory bowel disease is probable with a low possibility of an early neoplastic event such as lymphoma or, less likely, dry form FIP can at times be found on biopsy of these presentations. Full thickness tissue biopsies via open laparotomy, ideally guided by intraoperative ultrasound in order to obtain the most representative mural sample, would be necessary to rule more significant disease than IBD. A mesenteric lymph node mass is noted and measured 5.0 x 3.0 cm. Epigastric and other smaller lymph nodes appeared enlarged. There were slight areas owing to lymphatic congestion.

### ***Pancreas***

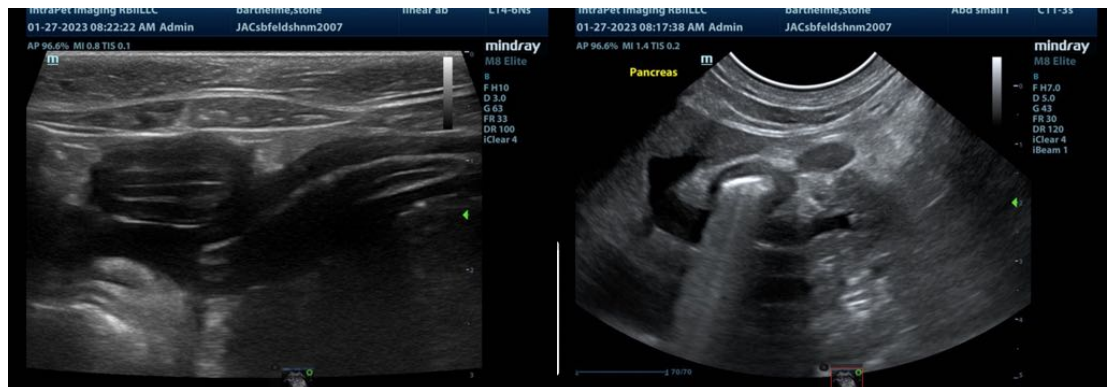
The **pancreas** revealed hypoechoic, undulating contour with a dilated duct and enhanced surrounding mesentery. This is consistent with age related pancreas. Some level of inflammation is likely.

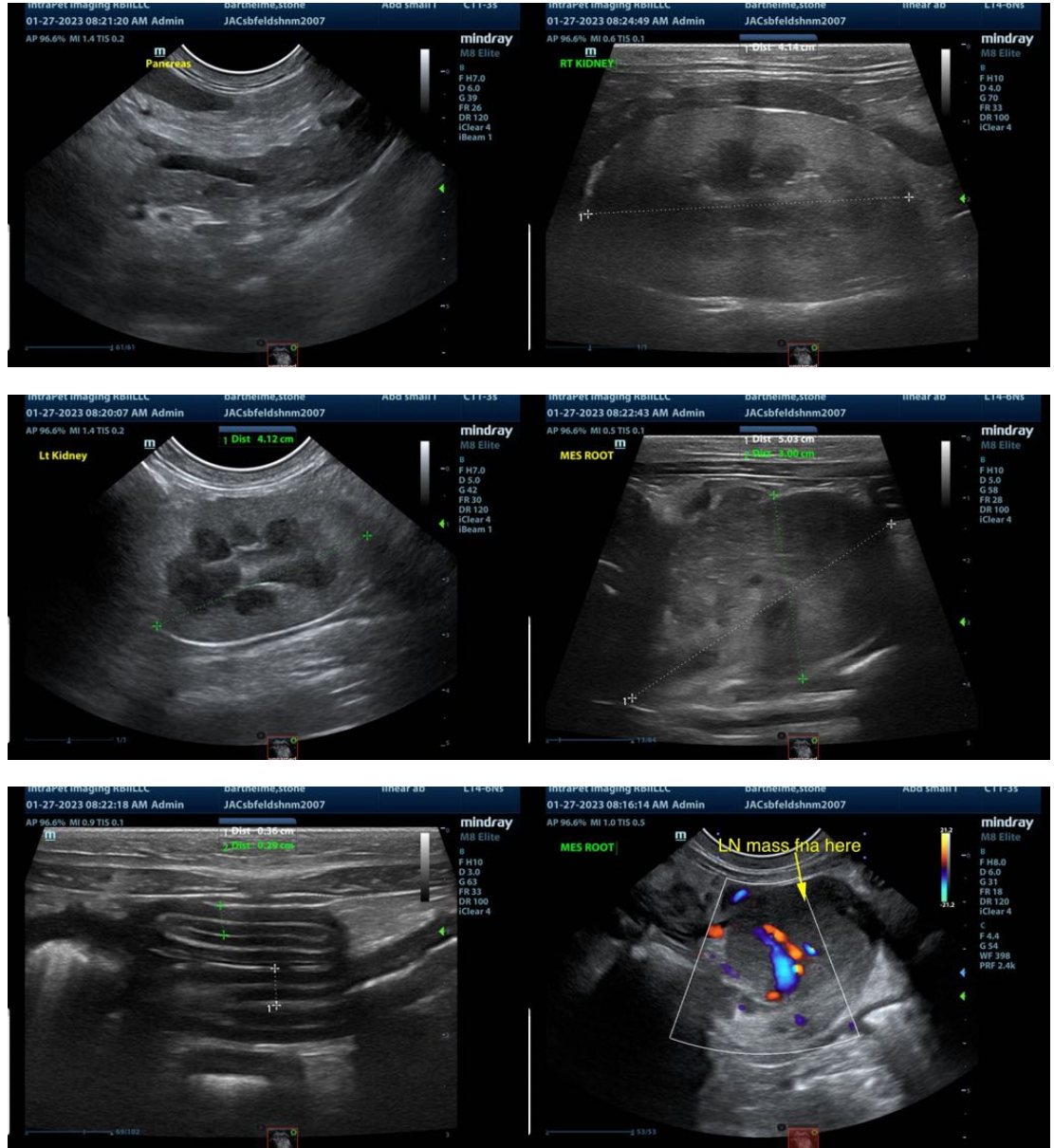
### **ULTRASONOGRAPHIC FINDINGS**

Diffuse intestinal thickening with mesenteric lymph node mass.  
Free fluid owing to lymphatic congestion.  
Minor lymphadenopathy.

### **INTERPRETATION OF THE FINDINGS & FURTHER RECOMMENDATIONS**

Neoplastic criteria is not completely met in the small intestine. However, the lymph node mass does meet neoplastic criteria. Lymphoma is suspected. Emerging intestinal neoplasia/lymphoma in the small intestine is suspected. FNA of the lymph node mass is recommended for further definition. The prognosis is guarded depending upon eventual response to chemotherapy. The hope is that small cell lymphoma may be present to respond readily to Prednisolone and Leukeran combination.





The information and recommendations provided are based on the images presented by the referring veterinarian. No evaluation can be communicated regarding pathology that was not visible in the image/video clips provided.

Thank you for this referral. If the clinical or image interpretation does not parallel your findings or if I can be of any further assistance please contact me.

**Eric Lindquist**, DMV, DABVP, Cert. IVUSS, CEO of SonoPath.com  
 Eric.Lindquist@SonoPath.com