



**PATIENT PRESENTING CLINICAL SIGNS**

**Groot Long** History: Coughing -originally owner thought was kennel cough then went on for too long. BCS 4/9 with 1 kg weight loss.HR 160 bounding, vocal and growling. VHS 15, pulmonary edema. started on lasix and Pimobendan prior to scan today.

**SPECIES** Abnormal PE/Chem/CBC/UA Results: sedation: oral gabapentin premedication with torbugesic/midazolam IM prior to scan. Owner present to aid in patient handling.

Canine

**BREED ULTRASONOGRAPHIC EXAMINATION OF THE HEART**

**Mastiff Cross** The echocardiogram in this patient revealed moderate to severe volume overload in all four chambers. Mitral and tricuspid insufficiency was noted with subnormal contractility. This is consistent with dilated cardiomyopathy. EPSS and tricuspid insufficiency was excessive. Causes of this presentation can include nutritional cardiomyopathy and myocarditis. Trace pericardial effusion was also noted likely owing to longstanding volume overload as a reflection of the overall excessive volume.

**SEX**

Neutered male

**AGE**

5 years

**WEIGHT**

49 kg

**INTERPRETED BY**

Eric Lindquist, DMV  
DABVP, Cert. IVUSS

**IMAGING PERFORMED BY**

Dr. McFarlen

**HOSPITAL NAME**

Van Isle VH

**REFERRING VET**

Dr. McFarlen

CANINE CARDIAC PARAMETERS	MR VMAX (m/s)	TR VMAX (m/s)	LA/AO (Boon method)	LA/AO (Heart Base;)	FS (%)	EF (%)	EPSS (cm)
NORMAL PARAMETER	4.5-5.5	<2.7	1.3	<1.6	28-40	40-100	<0.6
PATIENT		3.0	2.0	2.2	11-17	24	2.0
CANINE CARDIAC PARAMETERS	HR (BPM)	AV VMAX (m/s)	PV MAX (m/s)	BODY WEIGHT (kg)	LA (2D short axis Base view) (cm)	LVIDd (Avg; 2D and m-mode short axis) (cm)	LVIDs (Avg; 2D and m-mode short axis) (cm)
NORMAL PARAMETER	50-100	0.7-1.7	0.7-1.6	BELOW	BELOW	BELOW	BELOW
PATIENT		1.0	0.51	49 kg		7.83	

**ULTRASONOGRAPHIC FINDINGS**

Dilated cardiomyopathy with emerging right and left sided heart failure.

Mild pulmonary hypertension.

Secondary trace pericardial effusion.

**INVOICE**

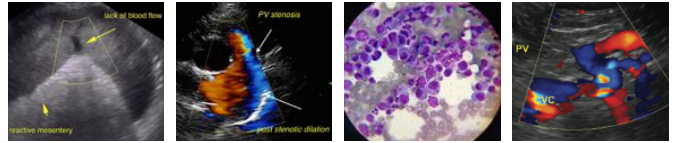
42363

**DATE**

1/27/23

**INTERPRETATION OF THE FINDINGS & FURTHER RECOMMENDATIONS**

I recommend quadrotherapy in this patient with Lasix at 2-3 mg/kg b.i.d. Ace inhibitor is recommended at 0.5 mg/kg s.i.d. progressing to b.i.d. and Pimobendan at 0.3 mg/kg b.i.d. and Spironolactone at 1-2 mg/kg b.i.d. EKG and blood pressure measurements are indicated. Taurine supplementation and taurine level testing is recommended. Assessment for causes of myocarditis is also indicated. The prognosis is guarded. Recheck echocardiogram is recommended in a month. Sedation may have a minor effect upon



**PATIENT**

the contractility in this patient if all parameters for DCM are present and volume overload is significant. The aortic velocity is likely subnormal owing to myocardial insufficiency.

Groot Long

**SPECIES**

Canine

**BREED**

Mastiff Cross

**SEX**

Neutered male

**AGE**

5 years

**WEIGHT**

49 kg

**INTERPRETED BY**

Eric Lindquist, DMV  
DABVP, Cert. IVUS

**IMAGING PERFORMED BY**

Dr. McFarlen

**HOSPITAL NAME**

Van Isle VH

**REFERRING VET**

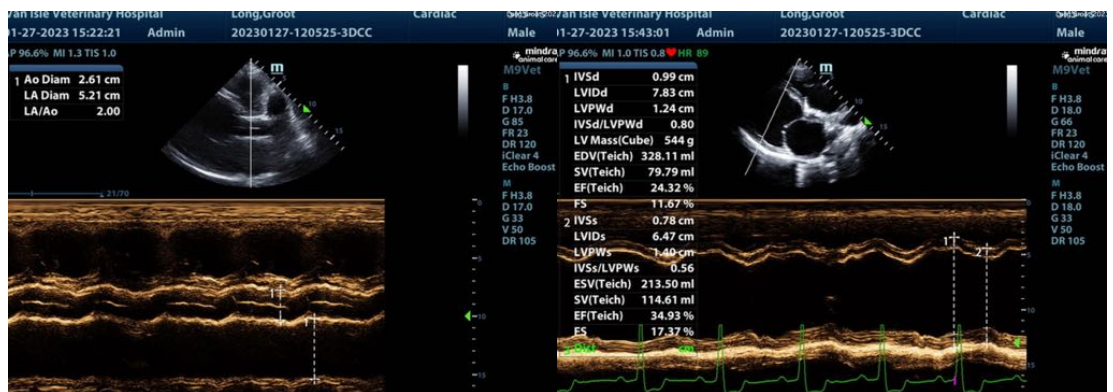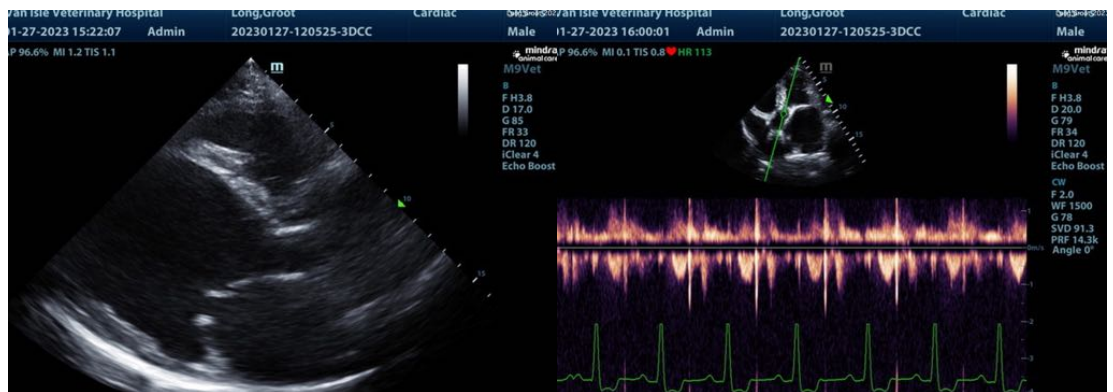
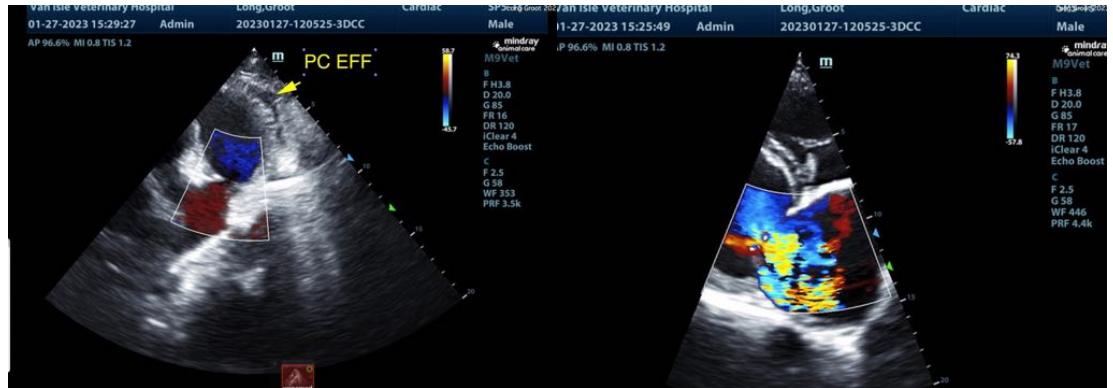
Dr. McFarlen

**INVOICE**

42363

**DATE**

1/27/23





**PATIENT**

Groot Long

**SPECIES**

Canine

**BREED**

Mastiff Cross

**SEX**

Neutered male

**AGE**

5 years

**WEIGHT**

49 kg

**INTERPRETED BY**

Eric Lindquist, DMV  
DABVP, Cert. IVUSS

**IMAGING PERFORMED BY**

Dr. McFarlen

**HOSPITAL NAME**

Van Isle VH

**REFERRING VET**

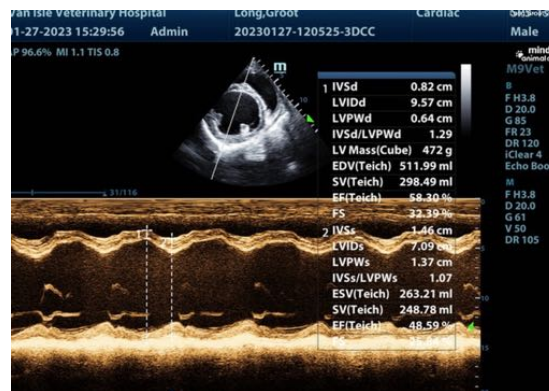
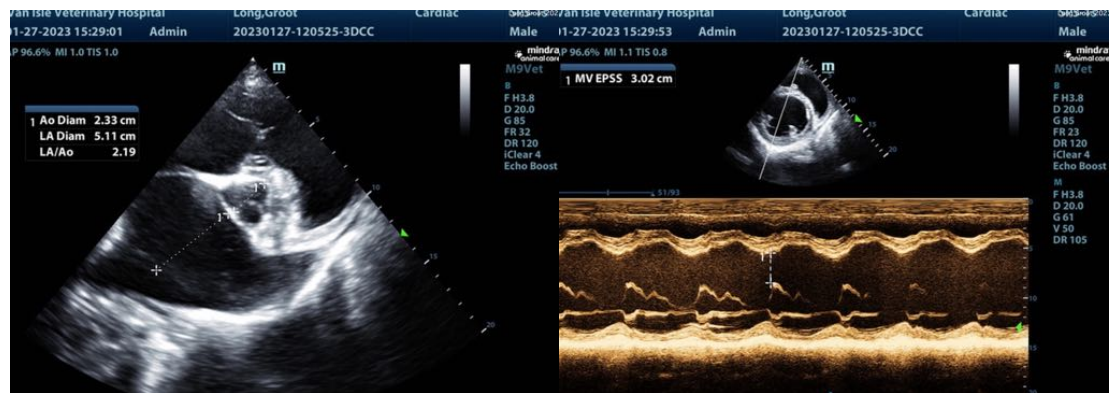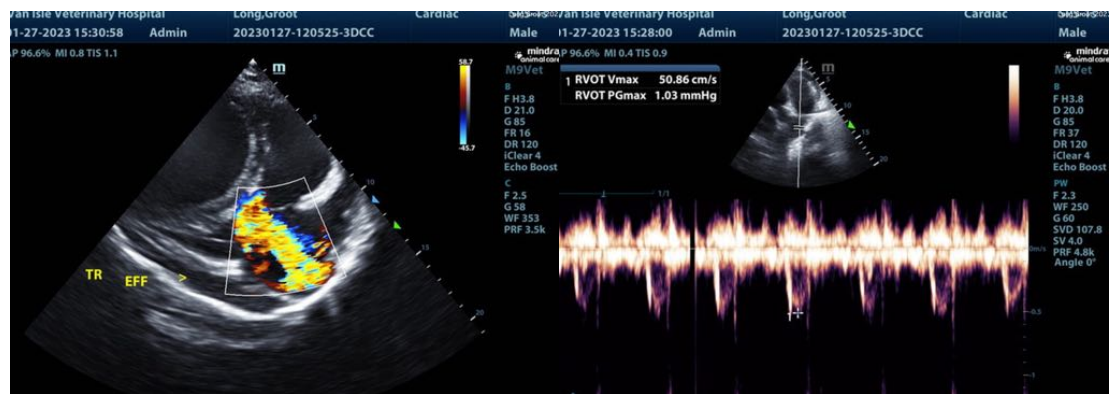
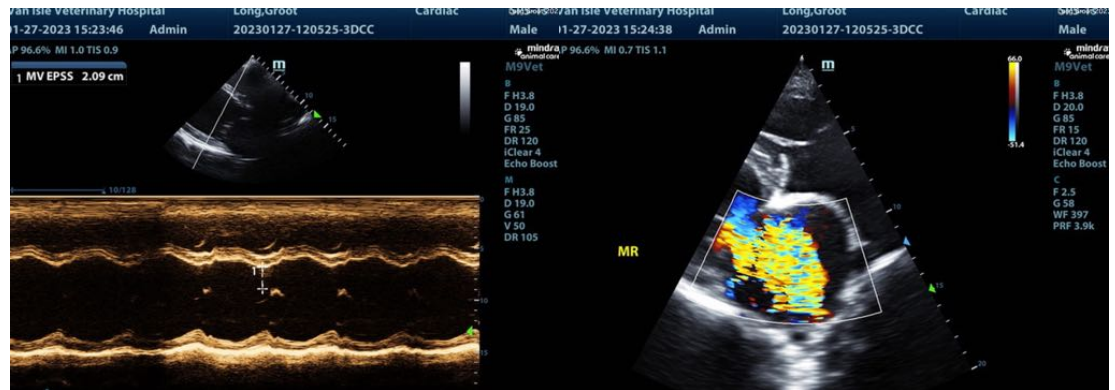Dr. McFarlen

**INVOICE**

42363

**DATE**

1/27/23





**PATIENT**

Groot Long

The information and recommendations provided are based on the images presented by the referring veterinarian/sonographer. No evaluation can be communicated regarding pathology that was not visible in the image/video clips provided.

**SPECIES**

Canine

Thank you for this referral. If the clinical or image interpretation does not parallel your findings or if I can be of any further assistance please contact me.

**BREED**

Mastiff Cross

**Eric Lindquist**, DMV, DABVP, Cert. IVUSS, CEO of SonoPath.com  
info@SonoPath.com

**SEX**

Neutered male

**AGE**

5 years

**WEIGHT**

49 kg

**INTERPRETED BY**

Eric Lindquist, DMV  
DABVP, Cert. IVUSS

**IMAGING  
PERFORMED BY**

Dr. McFarlen

**HOSPITAL NAME**

Van Isle VH

**REFERRING VET**

Dr. McFarlen

**INVOICE**

42363

**DATE**

1/27/23