



DATE	PRESENTING CLINICAL SIGNS
1/27/22	History: History of ascites, diarrhea, hypoalbuminemia diagnosed with protein losing enteropathy via labs and ultrasound in June of 2019. Has been well managed with dietary and medical therapy with resolution of all clinical signs. Past 6 months, new proteinuria and worsening hypoalbuminemia. UPC elevation.
PATIENT	
Sweet Pea Iman	
SPECIES	Current Medications: Since June of 2019 - Current medications 1) prednisone 2.5 mg SID, 2) metronidazole 250 mg: 1/4 SID, 3) carafate 1 g: 1/4 BID, 4) every other week B12, 5) hill's z/d, 6) plavix 75 mg: 1/4 SID, 7) cerenia 16 mg: 1/2 tablet 2 x /week.
Canine	Lab Results: 1/15/22: UPC 3
BREED	12/30/21: urine 3+ protein, SG 1.014, culture negative, albumin 2.6, 5/21/21: alb 2.9, urine protein 2+, USG 1.022.
Yorkshire Terrier	Date of Previous IntraPet Ultrasound: 6-3-2019.
SEX	Sedation: Not required to complete full diagnostic ultrasound.
Spayed Female	Stat Report: Not requested.
	Imaging Performed By: Stephanie Pearce RDCS, RVT.
AGE	ULTRASONOGRAPHIC EXAMINATION OF THE ABDOMEN
3/4/14	Urinary System
WEIGHT	The urinary bladder , trigone, and pelvic urethra presented normal thicknesses and normal tone. The ureters were not visible which is normal. No uroliths or sediment were visualized and anechoic urine was present. No evidence of inflammatory or neoplastic changes were noted. Ureteral papillae were normal.
9.6 Lbs.	The kidneys revealed normal size and structure, corticomedullary definition and ratio for this age. The cortices presented largely uniform texture with normal echogenic relationship to liver and spleen. Medullary structure differed distinctly from the cortex and no evidence of pelvic dilation was present. The capsules were acceptably uniform without significant irregularities. The right kidney measured 4.07 cm. The left kidney measured 4.13 cm.
INTERPRETED BY	Adrenal Glands
Eric Lindquist, DMV DABVP, Cert. IVUSS	Both adrenal glands were visualized and recognized as having normal shape, size, position and echogenicity for this breed. The phrenic vasculature, glandular echogenicity and detail were unremarkable. Capsule, cortex, and medullary definition were normal for this age patient. The right adrenal gland measured 1.67 cm x 0.45 cm at the caudal pole and 0.44 cm at the cranial pole. The left adrenal gland measured 1.48 cm x 0.52 cm at the caudal pole and 0.39 cm at the cranial pole.
HOSPITAL NAME	Spleen
Everhart VC	The spleen presented a smooth homogeneous parenchyma hyperechoic to liver and renal cortical parenchyma. The capsule was smooth without noticeable expansion or deviation from within the spleen or adjacent pathology. The splenic vasculature demonstrated normal volume without signs of congestion or thrombosis. No sonographic evidence of acute or chronic inflammatory, neoplastic, or infarctual changes were noted. Caudal folding of the spleen was noted.
REFERRING VET	Liver
Dr. Notarangelo	The liver was uniform and relatively normal in size with slight increased portal markings. The gallbladder and common bile duct were unremarkable.
INVOICE	
13662	

Gastrointestinal

The **stomach** was empty. Mucosal fogging was persistent in portions of the small intestine, however curvilinear patterns were maintained. The lumen was empty.

Pancreas

The base and limbs of the **pancreas** were observed to be largely isoechoic to surrounding omental fat. Some parenchymal remodeling, however, with mild deviation from curvilinear normalcy was observed. Pancreatic duct and capsular irregularities were present consistent with age related changes. If pain upon imaging (+ Murphy sign) was present or if the patient is focally painful in subxyphoid palpation then low-grade smoldering chronic pancreatitis should be suspected.

ULTRASONOGRAPHIC FINDINGS

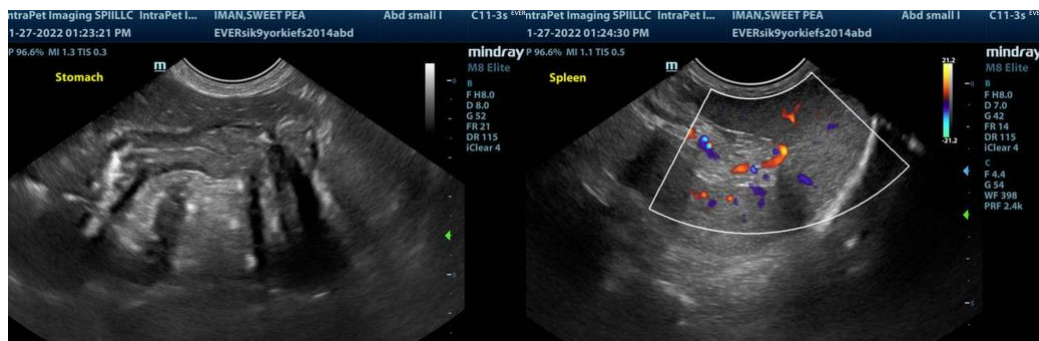- Benign abdomen with persistent mucosal fogging
- Age-related pancreatic changes
- Increased portal markings in the liver
- Splenic fold

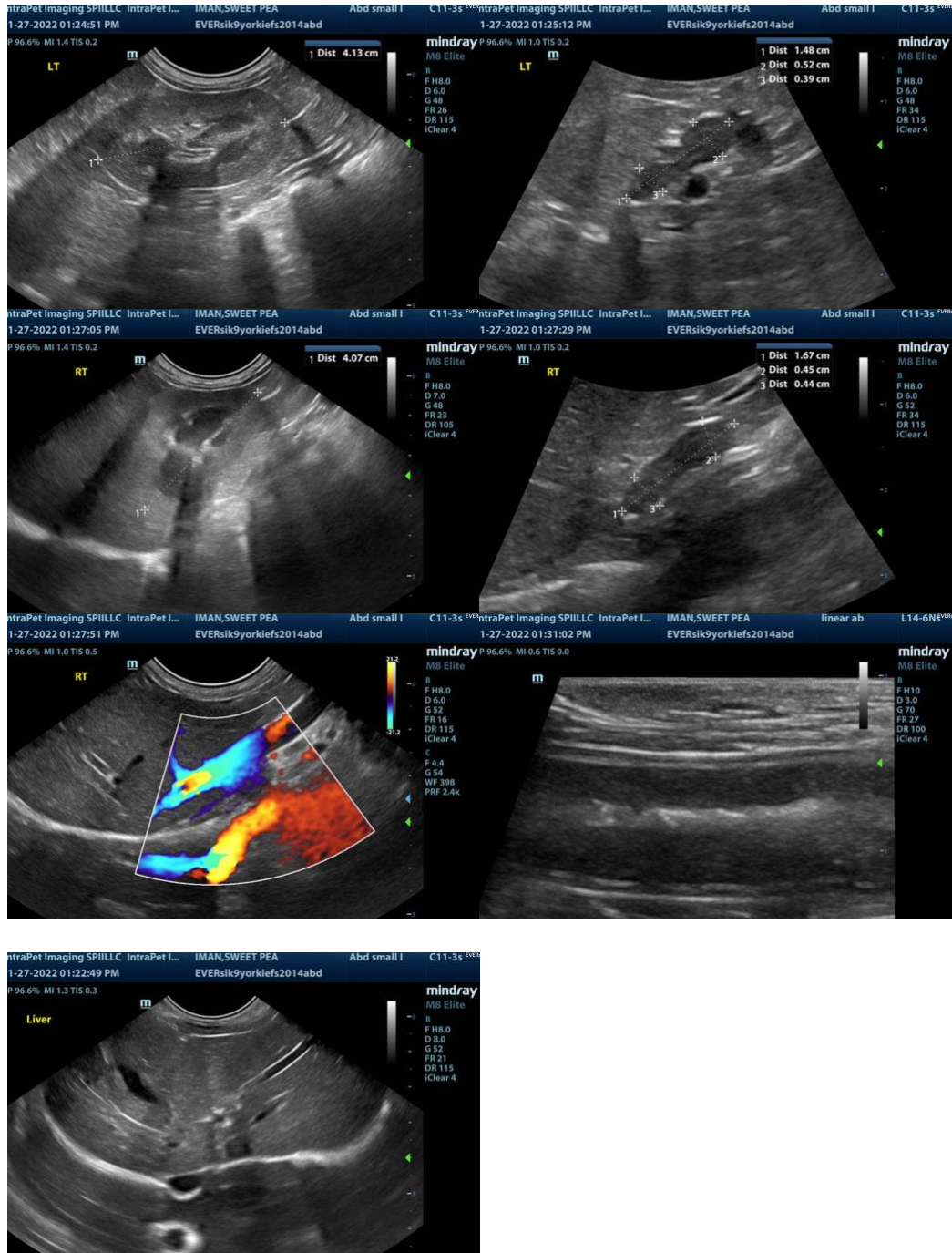
INTERPRETATION OF THE FINDINGS & FURTHER RECOMMENDATIONS

The abdomen appears stable. I am concerned about the hypertriglyceridemia. However, periodic pancreatitis may be an issue. Lipase may be deriving from low-grade inflammation in the GI tract or the pancreas yet no evidence of significant disease present.

For an additional charge, internal medicine consult can be utilized through Sonopath.com. You can select the internal medicine drop down at <http://spa.sonopath.com/>.

One of the world's top internists & SonoPath associate Dr. Remo Lobetti BVSc, MMedVet, PhD, DECVIM can evaluate your case through SonoPath. <https://sonopath.com/resources/sonopath-services/internal-medicine-teleconsultation-services>





The information and recommendations provided are based on the images presented by the referring veterinarian. No evaluation can be communicated regarding pathology that was not visible in the image/video clips provided.

Thank you for this referral. If the clinical or image interpretation does not parallel your findings or if I can be of any further assistance please contact me.

Eric Lindquist, DMV, DABVP, Cert. IVUSS, CEO of SonoPath.com
Eric.Lindquist@SonoPath.com