



PATIENT

Noah Wadman

SPECIES

Feline

BREED

DSH

SEX

Neutered Male

AGE

4 Years

WEIGHT

2.91 kg

INTERPRETED BY

Eric Lindquist, DMV

DABVP, Cert. IVUSS

IMAGING PERFORMED BY

Dr. Yashar Alami
Alamdari

HOSPITAL NAME

King Hopkins Pet
Hospital

REFERRING VET

Dr. Yashar Alami
Alamdari

INVOICE

35145

DATE

1/27/22

PRESENTING CLINICAL SIGNS

Noah is a 4 y/o NM indoor cat. Adopted as a kitten Recently started acting strange, sleeping a lot. Normally active, alert. Still eating/drinking but appetite decreased Normal urinations BM's slightly more soft, no diarrhea Drinking a little more yesterday No vomiting.

Abnormal PE/Chem/CBC/UA Results: RBC 5.35 6.54 12.20 x10¹²/L HCT 24.9 30.3 52.3 % HGB 8.0 9.8 16.2 g/d EOS 0.01 0.17 1.57 x10⁹/L PLT 115 151 600 K/μL PCR test is negative for tick transmitted disease agents, FIV/FelV and Fecal tests also negative.

ULTRASONOGRAPHIC EXAMINATION OF THE ABDOMEN

Urinary System

The **urinary bladder**, trigone, and pelvic urethra presented normal thicknesses and normal tone. The ureters were not visible which is normal. No uroliths or sediment were visualized and anechoic urine was present. No evidence of inflammatory or neoplastic changes were noted. Ureteral papillae were normal.

The **kidneys** revealed normal size and structure, corticomedullary definition and ratio for this age. The cortices presented largely uniform texture with normal echogenic relationship to liver and spleen. Medullary structure differed distinctly from the cortex and no evidence of pelvic dilation was present. The capsules were acceptably uniform without significant irregularities. The left kidney measured 3.8 cm.

Adrenal Glands

The regions of the **adrenal glands** were unremarkable.

Spleen

The **spleen** presented a smooth homogeneous parenchyma hyperechoic to liver and renal cortical parenchyma. The capsule was smooth without noticeable expansion or deviation from within the spleen or adjacent pathology. The splenic vasculature demonstrated normal volume without signs of congestion or thrombosis. No sonographic evidence of acute or chronic inflammatory, neoplastic, or infarctual changes were noted.

Liver

The **liver** images submitted revealed subjectively normal liver size, contour, and structure. Parenchymal echogenicity was naturally coarse and hypoechoic to the spleen. Vascular and biliary tracts were of normal volume with no evidence of congestion. The gallbladder presented acceptably thin walls with primarily anechoic content. The cystic and common bile ducts were normal. No pathological hepatic lymphadenopathy was evident. No overt structural evidence of inflammatory, infiltrative or regenerative pathology was evident.

Gastrointestinal

Minor fluid filled **gastric** lumen present. The ileocecal junction and proximal colon revealed infiltrative pattern with complete loss of mural detail, extending caudally for approximately 4.0 cm. Wall thickness measured up to 0.6 cm. The colonic thickening initiated at the cecum and proximal colon. The small intestine up to that point appeared to be largely unremarkable.

Pancreas

The **pancreas** was heterogeneous, hypoechoic and irregular. Some level of pancreatitis suspected.



PATIENT

Free Abdomen

Noah Wadman

Slight free fluid noted between the liver lobes. The liver itself was uniform, no evident pathology.

SPECIES

Feline

- Infiltrative cecocolic pattern – suspect round cell neoplasia/lymphoma.
- Low-grade pancreatitis suspected
- Age related abdominal changes otherwise

BREED

DSH

INTERPRETATION OF THE FINDINGS & FURTHER RECOMMENDATIONS

Ultrasound guided FNA of the proximal colonic wall warranted. Dry form FIP is also a potential. Ileocecolic resection could be considered from the distal ileum to the level of the mid descending colon. The free fluid is a bit concerning as to lymphatic congestion. Sampling is essential in this patient. Even though neoplastic criteria is met sonographically, there is a possibility of granulomatous non-neoplastic disease involving the colon.

AGE

4 Years

WEIGHT

2.91 kg

INTERPRETED BY

Eric Lindquist, DMV

DABVP, Cert. IVUSS

IMAGING PERFORMED BY

Dr. Yashar Alami
Alamdari

HOSPITAL NAME

King Hopkins Pet
Hospital

REFERRING VET

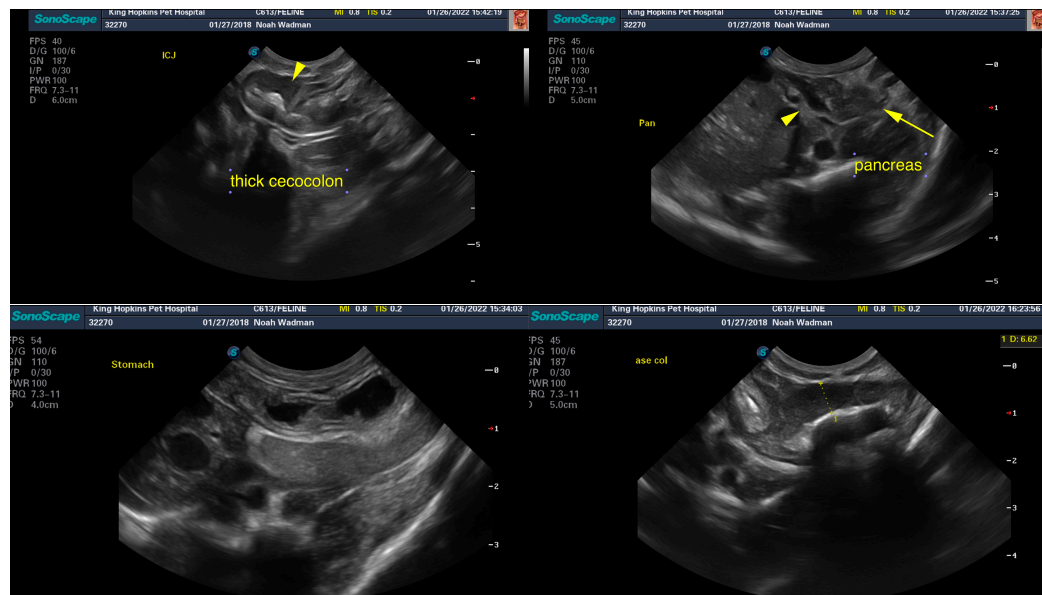
Dr. Yashar Alami
Alamdari

INVOICE

35145

DATE

1/27/22





PATIENT

Noah Wadman

SPECIES

Feline

BREED

DSH

SEX

Neutered Male

AGE

4 Years

WEIGHT

2.91 kg

INTERPRETED BY

Eric Lindquist, DMV
DABVP, Cert. IVUSS

IMAGING PERFORMED BY

Dr. Yashar Alami
Alamdari

HOSPITAL NAME

King Hopkins Pet Hospital

REFERRING VET

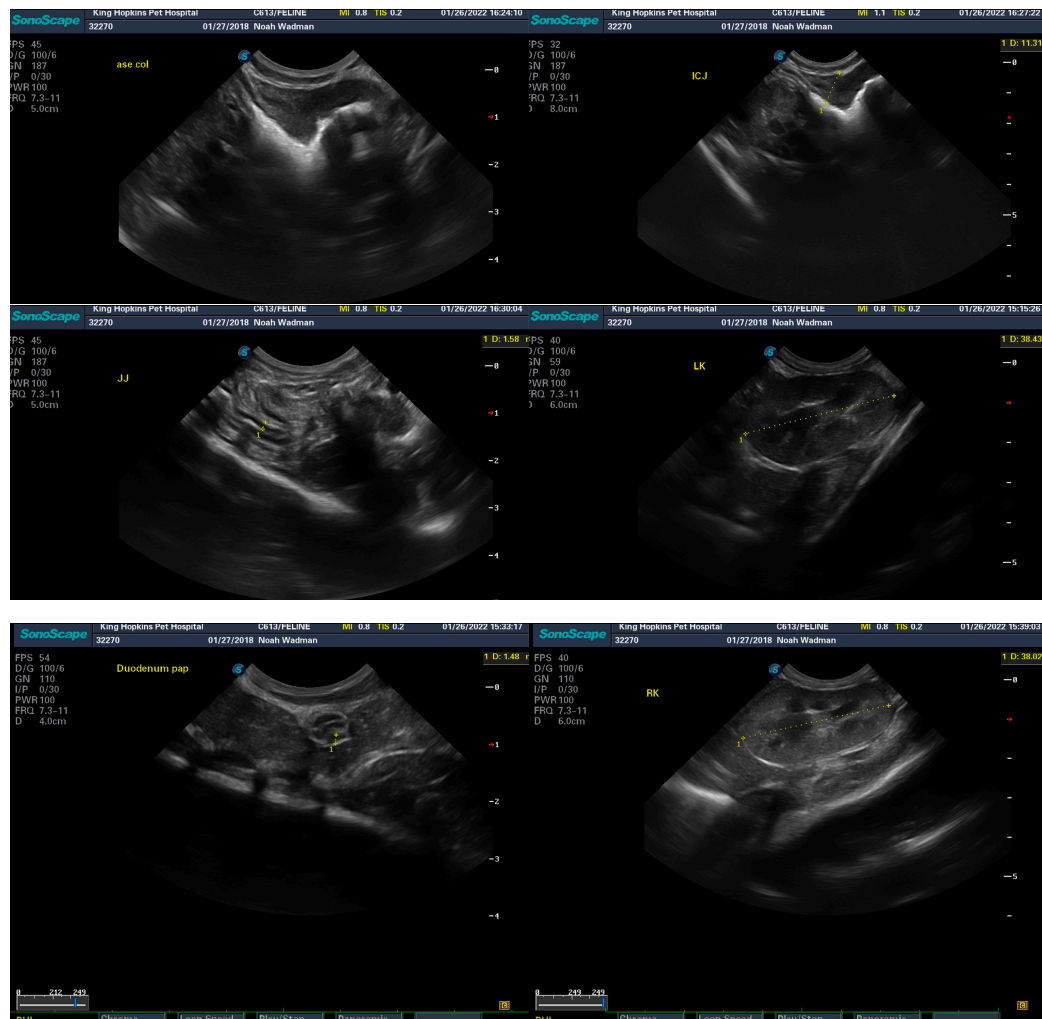
Dr. Yashar Alami
Alamdari

INVOICE

35145

DATE

1/27/22



The information and recommendations provided are based on the images presented by the referring veterinarian/sonographer. No evaluation can be communicated regarding pathology that was not visible in the image/video clips provided.

Thank you for this referral. If the clinical or image interpretation does not parallel your findings or if I can be of any further assistance please contact me.

Eric Lindquist, DMV, DABVP, Cert. IVUSS, CEO of SonoPath.com

info@SonoPath.com