

**DATE**

1/27/22

PRESENTING CLINICAL SIGNS

History: Hx of mast cell tumor - removed 11/2020. Saw oncologist 12/2020 - US then showed no evidence of mets. Rec repeat US in 3-4 months. 4-6-2021 AUS here showed no evidence of mets. 1/24/2022 wanted 2 lumps rechecked. Mass on R let thigh poss MCT. Rec surgery to remove all suspicious masses. Rec another US first to fully evaluate. Dog also has been vomiting bile periodically past 6 months.

PATIENT

Cash Meissner

Lab Results: Bloodwork will be re-evaluated at time of US.

Date of Previous IntraPet Ultrasound: 4-5-2021.

Sedation: Not required to complete full diagnostic ultrasound.

Stat Report: Not requested.

Imaging Performed By: Rachel Brilhart, RDMS.

SPECIES

Canine

BREED

Boxer

SEX

Neutered male

AGE

8/16/14

WEIGHT

82 lbs

INTERPRETED BY

Eric Lindquist, DMV
DABVP, Cert. IVUSS

HOSPITAL NAME

Jacksonville VC

REFERRING VET

Dr. Kablis

INVOICE

95593

ULTRASONOGRAPHIC EXAMINATION OF THE ABDOMEN**Urinary System**

The **urinary bladder**, trigone, and pelvic urethra presented normal thicknesses and normal tone. The ureters were not visible which is normal. No uroliths or sediment were visualized and anechoic urine was present. No evidence of inflammatory or neoplastic changes was noted. Ureteral papillae were normal.

The **kidneys** revealed normal size and structure, corticomedullary definition and ratio for this age. The cortices presented largely uniform texture with normal echogenic relationship to liver and spleen. Medullary structure differed distinctly from the cortex and no evidence of pelvic dilation was present. The capsules were acceptably uniform without significant irregularities. The right kidney measured 6.37 cm. The left kidney measured 6.7 cm.

Adrenal Glands

Both **adrenal glands** were visualized and recognized as having normal shape, size, position and echogenicity for this breed. The phrenic vasculature, glandular echogenicity and detail were unremarkable. Capsule, cortex, and medullary definition were normal for this age patient. The left adrenal gland measured 2.88 x 0.82 cm at the caudal pole and 0.65 cm at the cranial pole. The right adrenal gland measured 2.29 x 0.95 cm at the caudal pole and 0.9 cm at the cranial pole.

Spleen

The **spleen** revealed a focal, hypoechoic nodule. This is a new development from the prior sonogram and measured 0.87 cm. FNA is indicated.

Liver

The **liver** images submitted revealed subjectively normal liver size, contour, and structure. Parenchymal echogenicity was naturally coarse and hypoechoic to the spleen. Vascular and biliary tracts were of normal volume with no evidence of congestion. The gallbladder presented acceptably thin walls with primarily anechoic content. The cystic and common bile ducts were normal. No pathological hepatic lymphadenopathy was evident. No overt structural evidence of inflammatory, infiltrative or regenerative pathology was evident.

Gastrointestinal

Examination of the **gastrointestinal tract** revealed a stomach and intestine free of stasis, of normal wall thickness, acceptable curvilinear mural detail, and peristaltic activity. Small and large intestine demonstrated normal luminal chyme and stool consistency respectively. No obstructive or overt infiltrative disease was noted. No associated abnormal lymphatic activity was noted.

Pancreas

The base and limbs of the **pancreas** were observed to be largely isoechoic to surrounding omental fat. Pancreatic duct and capsular contour were acceptably normal and parenchyma respected normal curvilinear patterns. No overt evidence of active inflammatory or neoplastic disease was noted.

Free Abdomen

The prior surgical site from mast cell revealed an undifferentiated, hypoechoic 0.5 cm subcutaneous nodule. This is concerning for local return. FNA or surgical resection is recommended.

Thorax

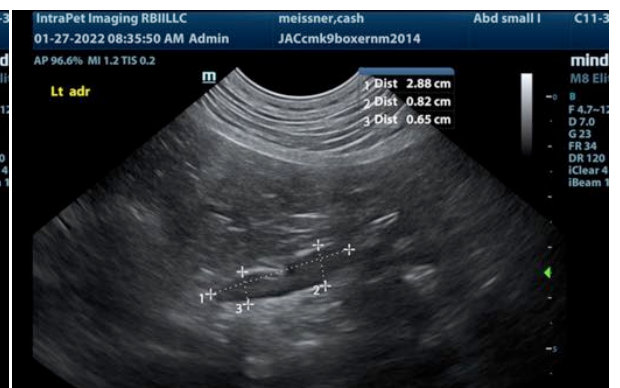
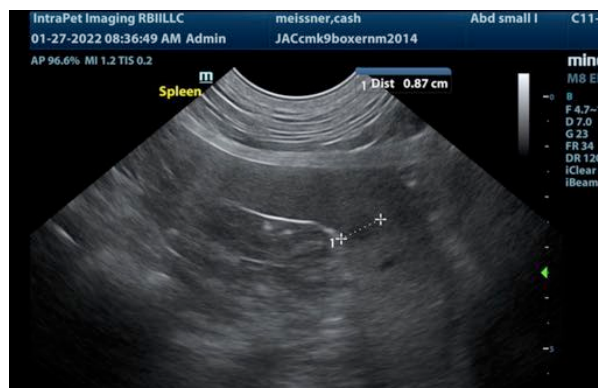
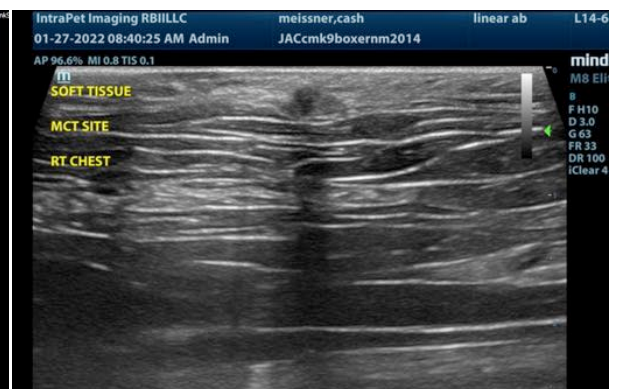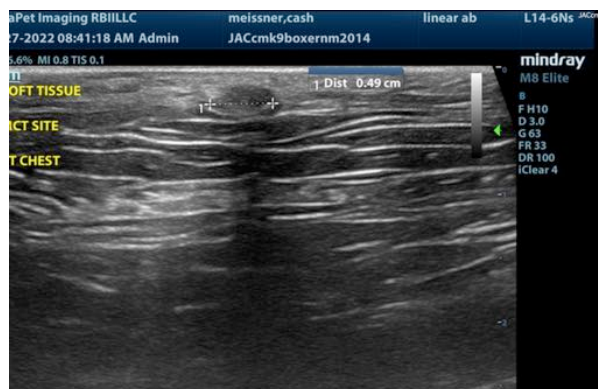
The right thorax revealed similar hypoechoic nodule at the surgical site. The heart revealed no evidence of pathology.

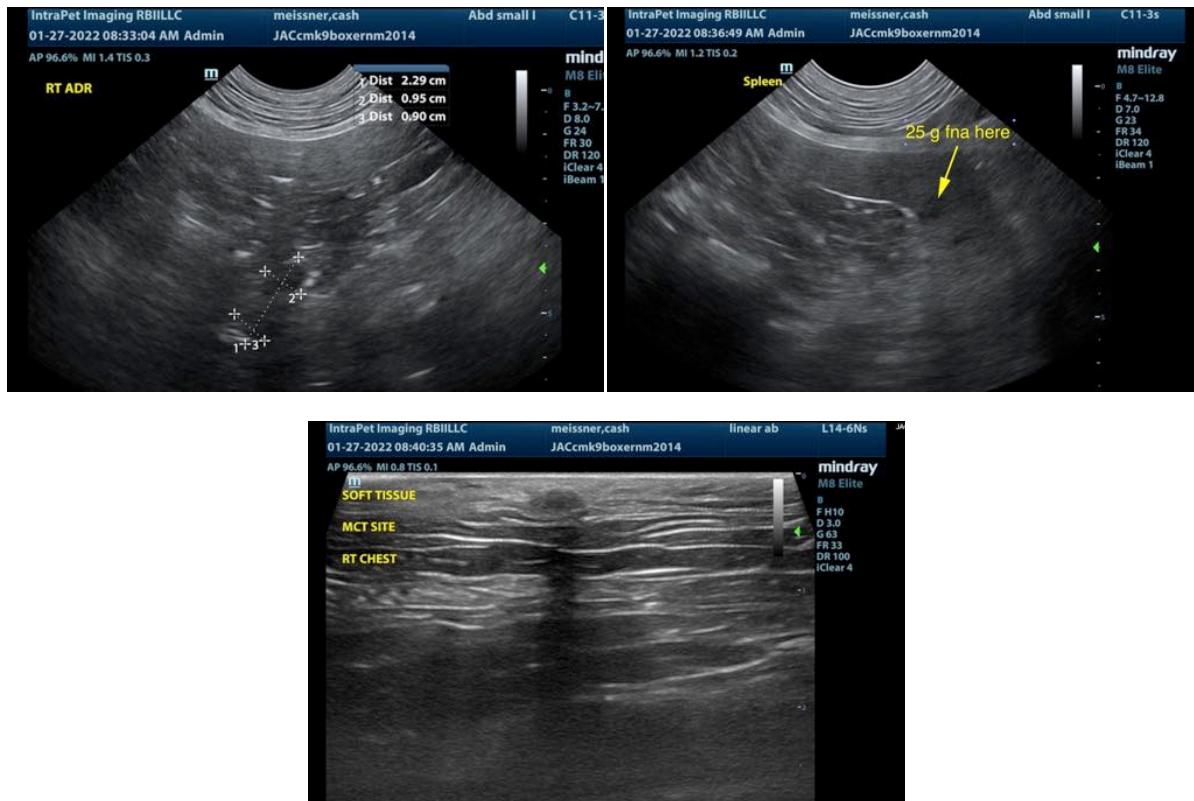
ULTRASONOGRAPHIC FINDINGS

Focal splenic nodule, new development.
Subcutaneous nodule at the surgical site.

INTERPRETATION OF THE FINDINGS & FURTHER RECOMMENDATIONS

The focal splenic nodule is a new development. Resection or FNA of the subcutaneous nodule is indicated. FNA of the spleen is indicated. There is concern for local return of mast cell in both surgical sites.





The information and recommendations provided are based on the images presented by the referring veterinarian. No evaluation can be communicated regarding pathology that was not visible in the image/video clips provided.

Thank you for this referral. If the clinical or image interpretation does not parallel your findings or if I can be of any further assistance please contact me.

Eric Lindquist, DMV, DABVP, Cert. IVUSS, CEO of SonoPath.com
 Eric.Lindquist@SonoPath.com