



PATIENT

Loki Kauffman

SPECIES

Feline

BREED

Egyptian Mau

SEX

Neutered Male

AGE

13 Years

WEIGHT

11.8 pounds

INTERPRETED BY

Eric Lindquist, DMV,
DABVP(CFM), Cert.
IVUSS

IMAGING PERFORMED BY

Dr. Jennifer Todd

HOSPITAL NAME

Lambs Gap Animal
Hospital

REFERRING VET

Dr. Jennifer Todd

INVOICE

14304

DATE

01/26/26

PRESENTING CLINICAL SIGNS

- Loki is a thirteen year old, MN, Egyptian Mau cat who is hyperthyroid controlled on transdermal methimazole.
- Several month history of intermittent ADR (lethargy, decreased appetite)
- Two day history of anorexia, weakness, pain symptoms, lethargy, and possible distended left abdomen noticed by owner
- CBC: mild chronic non-regenerative anemia, normal chemistry, mildly increased fPL (4.8), normal T4
- Full body rads showed distorted stomach axis (horizontal instead of vertical)
- Abdominal ultrasound advised and did FNA of splenic mass and spleen when observed cines.

ULTRASONOGRAPHIC EXAMINATION OF THE ABDOMEN

Urinary System

The **urinary bladder** presented with a minor amount of sand. The urethra was normal in structure and tone to a depth of 1.0 cm.

The **kidneys** revealed largely normal size and structure, corticomedullary definition and ratio (cortex 1/3 of medulla) were essentially maintained with some minor age-related loss of curvilinear patterns regarding the capsule and C/M junction. The cortices presented largely uniform texture with some increased echogenicity expected for his age patient. Medullary structure differed distinctly from that of the cortex and no evidence of pelvic dilation was present. The left kidney measured 4.19 cm in length. The right kidney measured 4.23 cm in length.

Adrenal Glands

Both **adrenal glands** were visualized and recognized as having normal shape, size, position and echogenicity for this breed. The phrenic vasculature, glandular echogenicity and detail were unremarkable. Capsule, cortex, and medullary definition were normal for this age patient. The left adrenal gland measured 1.0 cm x 0.32 cm width. The right adrenal gland measured 1.1 cm x 0.30 cm width.

Spleen

The **spleen** revealed a focal hypoechoic expansive nodule measuring 1.5 cm at the mid cranial body. Target type lesion and appears to be solitary. Subtle micronodular changes were also noted in the spleen. The splenic presentation may be completely incidental, however, round cell neoplasia and multiple myeloma and similar can present in this fashion especially given the long term history.

Liver

The **liver** images from right and left intercostal as well as subcostal views revealed subjectively normal liver size, contour, and structure. Some age-related parenchymal remodeling was noted but likely not clinically significant at this time. Vascular and biliary tracts were of normal volume and no evidence of congestion was noted. The gallbladder presented some dependent debris with essentially normal contour. The cystic and common bile ducts were normal. No overt evidence of active inflammatory, infiltrative or regenerative pathology was noted but should be paired with current or past LE elevations regarding any clinical significance to this presentation. The hepatic lymph nodes were unremarkable.



PATIENT

Loki Kauffman

SPECIES

Feline

BREED

Egyptian Mau

SEX

Neutered Male

AGE

13 Years

WEIGHT

11.8 pounds

INTERPRETED BY

Eric Lindquist, DMV,
DABVP(CFM), Cert.
IVUS

IMAGING PERFORMED BY

Dr. Jennifer Todd

HOSPITAL NAME

Lambs Gap Animal
Hospital

REFERRING VET

Dr. Jennifer Todd

INVOICE

14304

DATE

01/26/26

Gastrointestinal

Examination of the **gastrointestinal tract** revealed a stomach and intestine free of stasis, of normal wall thickness, acceptable curvilinear mural detail, and peristaltic activity. Small and large intestine demonstrated normal luminal chyme and stool consistency respectively. No obstructive or overt infiltrative disease was noted. No associated abnormal lymphatic activity was noted.

Pancreas

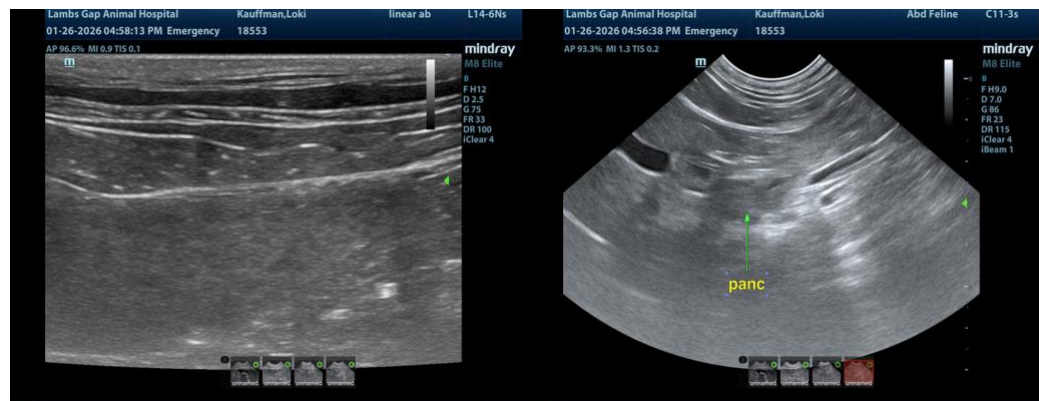
The base and limbs of the **pancreas** were observed to be largely isoechoic to surrounding omental fat. Some parenchymal remodeling, however, with mild deviation from curvilinear normalcy was observed. Pancreatic duct and capsular irregularities were present consistent with age related changes. If pain upon imaging (+ Murphy sign) was present or if the patient is focally painful in subxiphoid palpation then low-grade smoldering chronic pancreatitis should be suspected.

ULTRASONOGRAPHIC FINDINGS

- Age-related abdominal changes.
- Focal splenic nodule- emerging round cell neoplasia, hemangiosarcoma, nodular hyperplasia are all possible.

INTERPRETATION OF THE FINDINGS & FURTHER RECOMMENDATIONS

If this a solitary lesion, proactive splenectomy could be considered or an ultrasound guided 25-gauge FNA. Chest radiographs are indicated. Other comorbidities such as spinal pain, CNS or thoracic disease should all be ruled out as potential contributing issues.





PATIENT

Loki Kauffman

SPECIES

Feline

BREED

Egyptian Mau

SEX

Neutered Male

AGE

13 Years

WEIGHT

11.8 pounds

INTERPRETED BY

Eric Lindquist, DMV,
DABVP(CFM), Cert.
IUUS

IMAGING PERFORMED BY

Dr. Jennifer Todd

HOSPITAL NAME

Lambs Gap Animal
Hospital

REFERRING VET

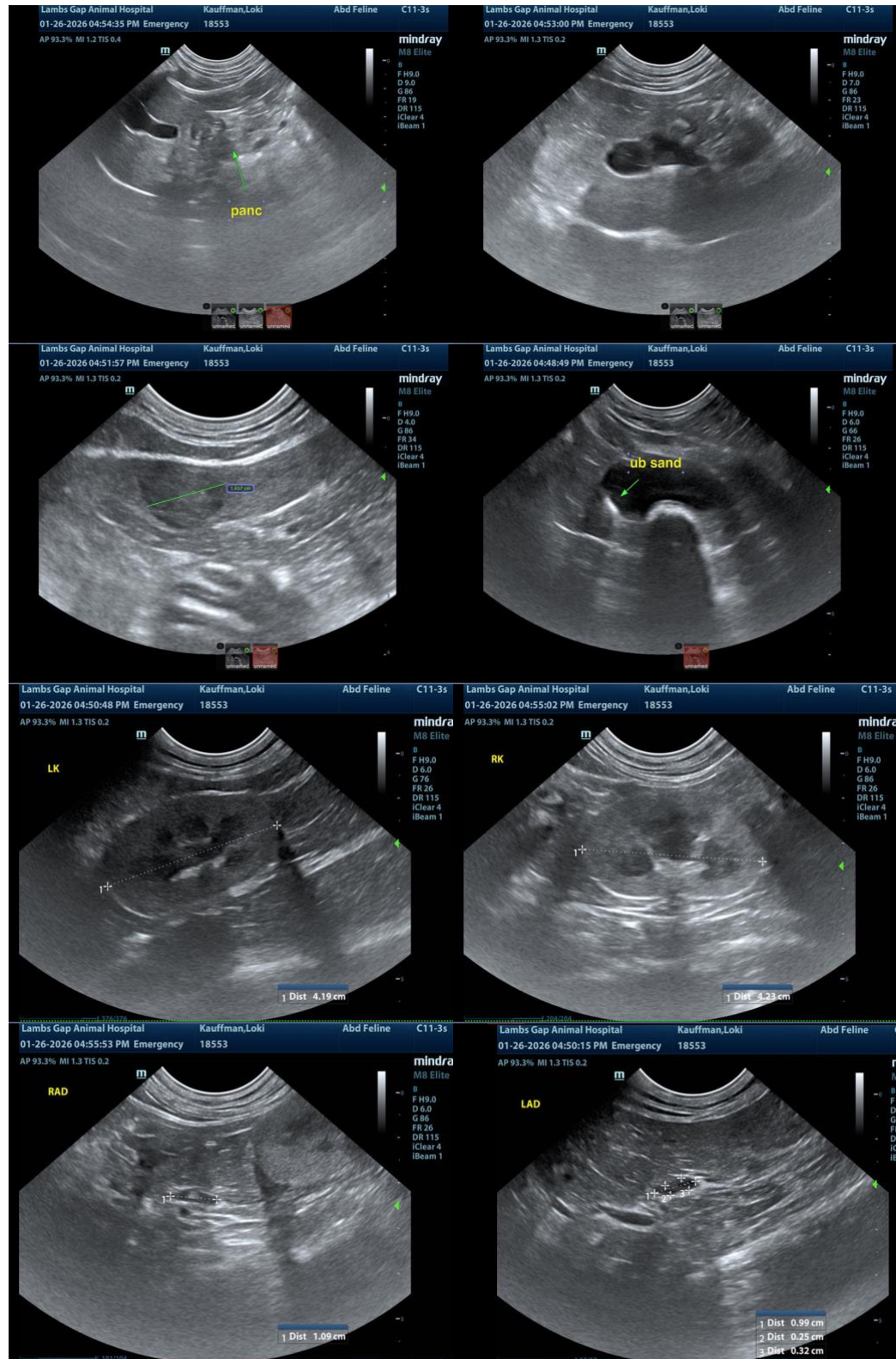
Dr. Jennifer Todd

INVOICE

14304

DATE

01/26/26





PATIENT

Loki Kauffman

SPECIES

Feline

BREED

Egyptian Mau

SEX

Neutered Male

AGE

13 Years

WEIGHT

11.8 pounds

INTERPRETED BY

Eric Lindquist, DMV,
DABVP(CFM), Cert.
IVUSS

IMAGING PERFORMED BY

Dr. Jennifer Todd

HOSPITAL NAME

Lambs Gap Animal
Hospital

REFERRING VET

Dr. Jennifer Todd

INVOICE

14304

DATE

01/26/26

The information and recommendations provided are based on the images presented by the referring veterinarian/sonographer. No evaluation can be communicated regarding pathology that was not visible in the image/video clips provided.

Thank you for this referral. If the clinical or image interpretation does not parallel your findings or if I can be of any further assistance, please contact me.

Eric Lindquist, DMV, DABVP(CFM), Cert. IVUSS,
CEO, Owner, Founder -- SonoPath.com

info@SonoPath.com