**DATE**

1/26/23

PATIENT

Goose Hylton

SPECIES

Canine

BREED

Red Heeler Mix

SEX

Spayed female

AGE

10/1/15

WEIGHT

31.4 lbs

INTERPRETED BYEric Lindquist, DMV
DABVP, Cert. IVUSS**HOSPITAL NAME**Animal Emergency
Hospital**REFERRING VET**

Dr. Kalwa

INVOICE

42345

PRESENTING CLINICAL SIGNS

Goose 7 yr 3m FS Heeler mix - Increasing lethargy - Vomiting- few times this am- food - Not eating-breakfast - C/S 1-2 days - Diarrhea - Diet: Purina Pro plan, shredded chicken and rice, occasional treats - Hx of getting into trash, had marinara sauce, missing chocolate 2 days ago - Hx: limp last week for a day few days increasing lethargic, new dog in house- 1 yr old, 3 yr old dog + her Sunday came home tried to get into pill case- none missing and all dog safe Sunday got into trash ate ribs + chocolate No hx of ingestion of non digestible items Hx of DI in past Stool harder last night, straining though

Current Medications: None listed.

Lab Results: See attached.

Radiographs: Material in stomach- ingests vs other - No obvious* obstructive pattern - Metal / opaque flake in intestine vs other GIT

Date of Previous IntraPet Ultrasound: No previous.

Sedation: Not required to complete full diagnostic ultrasound.

Stat Report: Not requested.

Imaging Performed By: Rachel Brillhart, RDMS.

ULTRASONOGRAPHIC EXAMINATION OF THE ABDOMEN**Urinary System**

The **urinary bladder**, trigone, and pelvic urethra presented normal thicknesses and normal tone. The ureters were not visible which is normal. No uroliths or sediment were visualized and anechoic urine was present. No evidence of inflammatory or neoplastic changes was noted. Ureteral papillae were normal.

The **kidneys** revealed normal size and structure, corticomedullary definition and ratio for this age. The cortices presented largely uniform texture with normal echogenic relationship to liver and spleen. Medullary structure differed distinctly from the cortex and no evidence of pelvic dilation was present. The capsules were acceptably uniform without significant irregularities. The right kidney measured 5.07 cm. The left kidney measured 4.96 cm.

Adrenal Glands

Both **adrenal glands** were visualized and recognized as having normal shape, size, position and echogenicity for this breed. The phrenic vasculature, glandular echogenicity and detail were unremarkable. Capsule, cortex, and medullary definition were normal for this age patient. The right adrenal gland measured 1.92 x 0.61 cm at the caudal pole and 0.58 cm at the cranial pole. The left adrenal gland measured 2.15 x 0.53 cm at the caudal pole and 0.45 cm at the cranial pole.

Spleen

The **spleen** presented a smooth homogeneous parenchyma hyperechoic to liver and renal cortical parenchyma. The capsule was smooth without noticeable expansion or deviation from within the spleen or adjacent pathology. The splenic vasculature demonstrated normal volume without signs of congestion or thrombosis. No sonographic evidence of acute or chronic inflammatory, neoplastic, or infarctual changes was noted.

Liver

The **liver** revealed mild coarse architecture with slightly increased portal markings. The gallbladder was mildly over distended.

Gastrointestinal

There was some residual chyme and gas was noted in the **stomach**, yet not pathological. This is consistent with end post prandial presentation. Transit of chyme into the small intestine was normal. Curvilinear patterns were maintained throughout the GI tract. No evidence of pathology. Small and large intestine demonstrated normal luminal chyme and stool consistency respectively. No obstructive or overt infiltrative disease was noted. No associated abnormal lymphatic activity was noted.

Pancreas

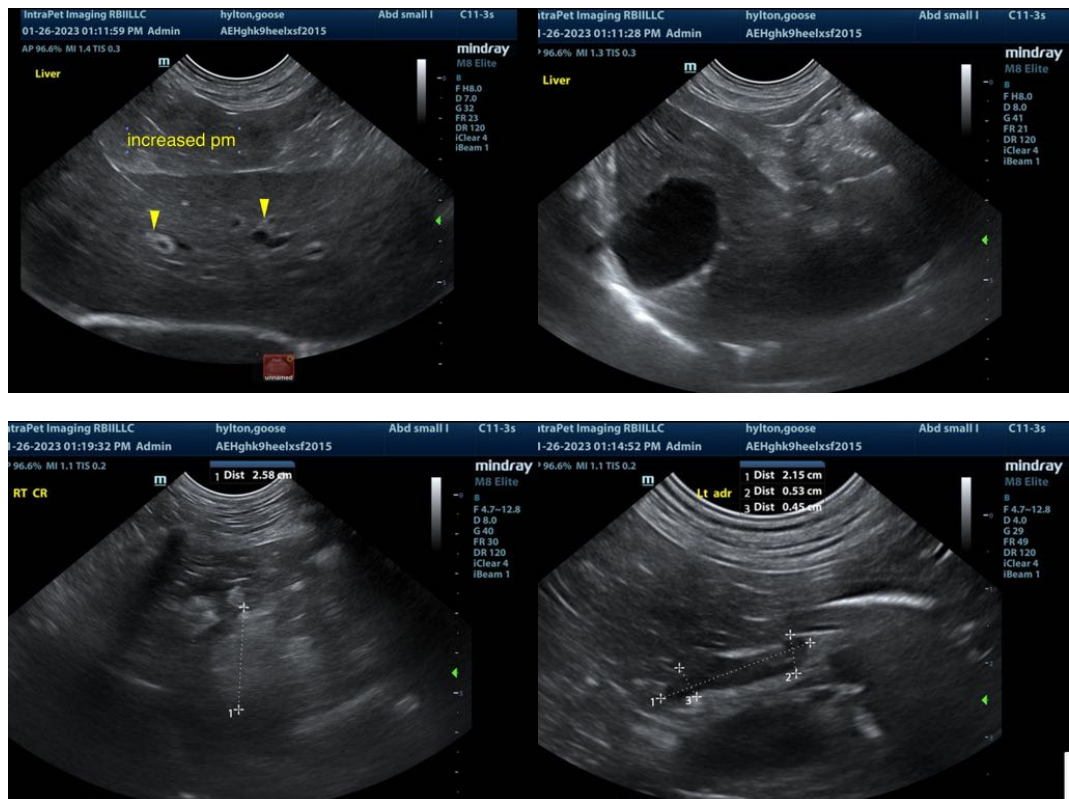
The **pancreas** revealed hyperechoic, coarse architecture. The pancreas measured up to 2.58 cm in the right limb.

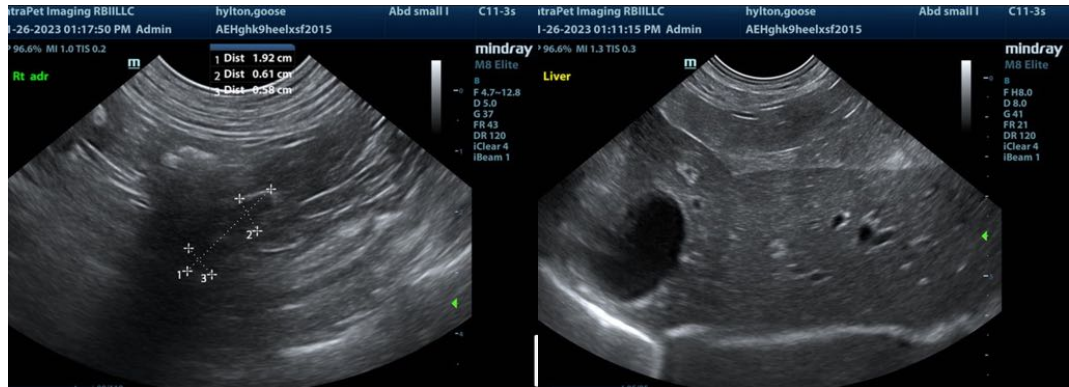
ULTRASONOGRAPHIC FINDINGS

Non-specific inflammatory hepatopathy, acute on chronic.
Hyperechoic pancreas.

INTERPRETATION OF THE FINDINGS & FURTHER RECOMMENDATIONS

FNA of the liver is indicated with cytology and culture. Leptospirosis titers are indicated. Ampicillin and Metronidazole as well as nutraceuticals are all warranted as well as IV fluid support. There was no evidence of portosystemic shunting or neoplasia.





The information and recommendations provided are based on the images presented by the referring veterinarian. No evaluation can be communicated regarding pathology that was not visible in the image/video clips provided.

Thank you for this referral. If the clinical or image interpretation does not parallel your findings or if I can be of any further assistance please contact me.

Eric Lindquist, DMV, DABVP, Cert. IVUSS, CEO of SonoPath.com
Eric.Lindquist@SonoPath.com