



PATIENT PRESENTING CLINICAL SIGNS

Tuna Cortez vomiting daily 3 weeks

SPECIES ULTRASONOGRAPHIC EXAMINATION OF THE ABDOMEN

Feline Urinary System

The **urinary bladder**, trigone, and pelvic urethra presented normal thicknesses and normal tone. The ureters were not visible which is normal. No uroliths or sediment were visualized and anechoic urine was present. No evidence of inflammatory or neoplastic changes were noted. Ureteral papillae were normal.

BREED

DSH

SEX

Neutered Male

The **kidneys** presented a relatively uniform cortical hyperechogenicity when compared to the renal medulla, spleen and liver. No overt masses were noted. Corticomedullary definition was nebulous and the ratio favored the cortex slightly. The ureters were not visible and assumed to be normal. These changes are most consistent with chronic interstitial nephritis yet infiltrative disease could not be entirely ruled out without biopsy though neoplasia is not suspected. The left kidney measured 3.72 cm. The right kidney measured 4.13 cm.

AGE

10 Years

Adrenal Glands

The regions of the **adrenal glands** were unremarkable.

WEIGHT

10 Pounds

Spleen

The **spleen** presented a smooth homogeneous parenchyma hyperechoic to liver and renal cortical parenchyma. The capsule was smooth without noticeable expansion or deviation from within the spleen or adjacent pathology. The splenic vasculature demonstrated normal volume without signs of congestion or thrombosis. No sonographic evidence of acute or chronic inflammatory, neoplastic, or infarctual changes were noted.

INTERPRETED BY

Eric Lindquist, DMV

Liver

The **liver** was diffusely hyperechoic to falciform fat. The gallbladder was duplicated, normal variant.

DABVP, Cert. IVUSS

IMAGING PERFORMED BY

Jenn

Gastrointestinal

The **gastrointestinal** presentation revealed mild uniform prominence of the gastric mucosa as well as areas of "ropey" small intestinal wall with slight disruption of the normal 1:3 muscularis/mucosal ratio. The intestinal submucosa was slightly irregular, thickened and hyperechoic suggestive of low grade, chronic disease. No concerning lymphadenopathy was visible. No evidence of obstruction was present. Chronic inflammatory bowel disease is likely with a low possibility of an early neoplastic event such as lymphoma. Full thickness tissue biopsies via open laparotomy, ideally guided by intraoperative ultrasound in order to obtain the most representative mural sample, would be necessary to rule out this possibility.

HOSPITAL NAME

Rockaway AH

REFERRING VET

Dr. Maniar

Pancreas

The base and limbs of the **pancreas** were observed to be largely isoechoic to surrounding omental fat. Some parenchymal remodeling, however, with mild deviation from curvilinear normalcy was observed. Pancreatic duct and capsular irregularities were present consistent with age related changes. If pain upon imaging (+ Murphy sign) was present or if the patient is focally painful in subxyphoid palpation then low-grade smoldering chronic pancreatitis should be suspected.

INVOICE

35055

DATE

1/26/22



PATIENT

Tuna Cortez

SPECIES

Feline

BREED

DSH

SEX

Neutered Male

AGE

10 Years

WEIGHT

10 Pounds

INTERPRETED BY

Eric Lindquist, DMV

DABVP, Cert. IVUSS

IMAGING PERFORMED BY

Jenn

HOSPITAL NAME

Rockaway AH

REFERRING VET

Dr. Maniar

INVOICE

35055

DATE

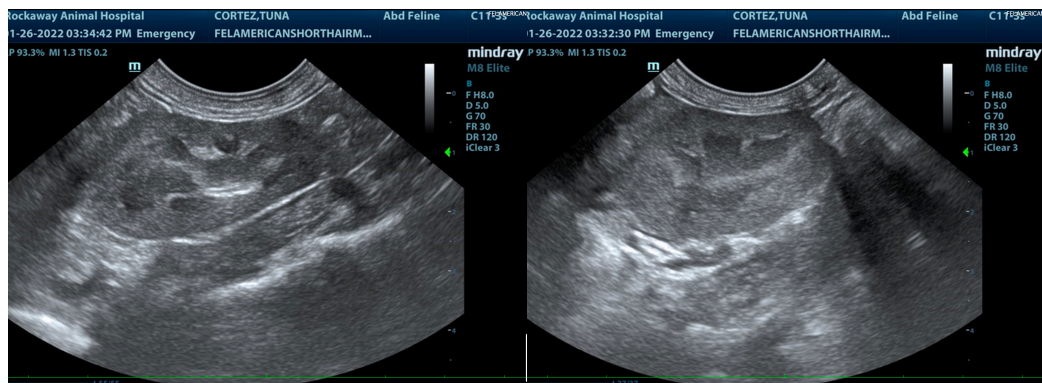
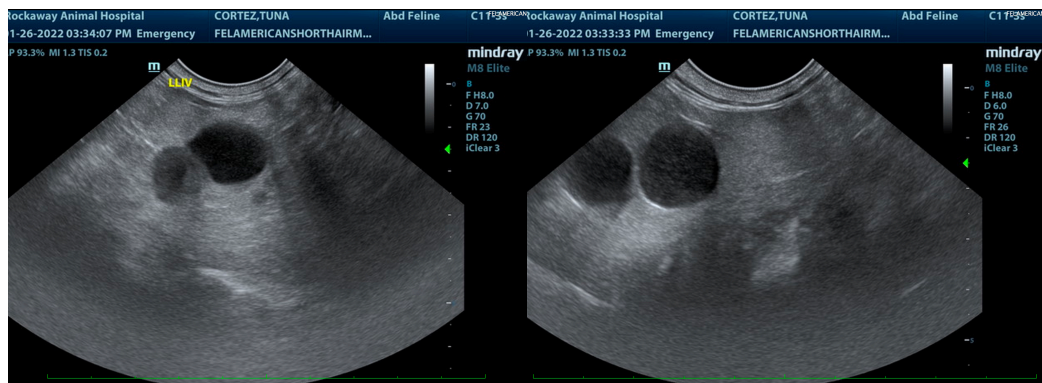
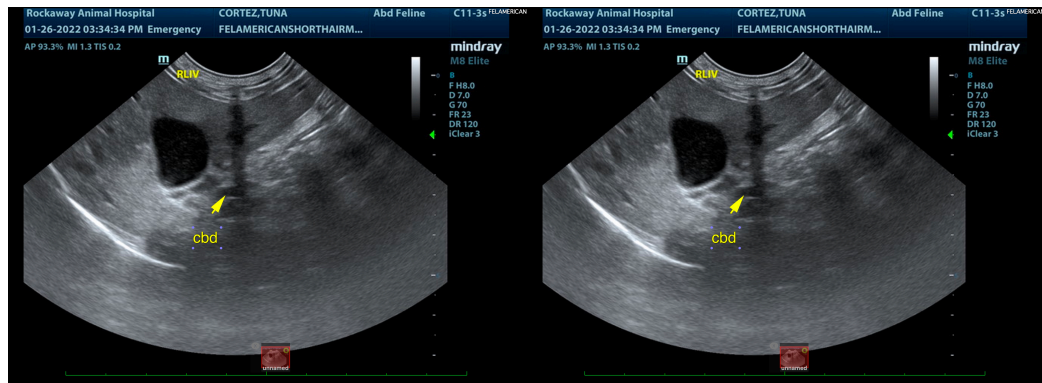
1/26/22

ULTRASONOGRAPHIC FINDINGS

- Duplicated gallbladder, normal variant
- Hyperechoic liver – consistent with lipidosis
- Age related abdominal changes otherwise

INTERPRETATION OF THE FINDINGS & FURTHER RECOMMENDATIONS

Management for inflammatory bowel/acute on chronic enteritis should prove effective.





PATIENT

Tuna Cortez

The information and recommendations provided are based on the images presented by the referring veterinarian/sonographer. No evaluation can be communicated regarding pathology that was not visible in the image/video clips provided.

SPECIES

Feline

Thank you for this referral. If the clinical or image interpretation does not parallel your findings or if I can be of any further assistance please contact me.

Eric Lindquist, DMV, DABVP, Cert. IVUSS, CEO of SonoPath.com

info@SonoPath.com

BREED

DSH

SEX

Neutered Male

AGE

10 Years

WEIGHT

10 Pounds

INTERPRETED BY

Eric Lindquist, DMV

DABVP, Cert. IVUSS

IMAGING PERFORMED BY

Jenn

HOSPITAL NAME

Rockaway AH

REFERRING VET

Dr. Maniar

INVOICE

35055

DATE

1/26/22