



PATIENT

Mowgli Scarpino

SPECIES

Feline

BREED

Domestic Shorthair

SEX

Neutered male

AGE

4 years

WEIGHT

17.5 lbs

INTERPRETED BY

Eric Lindquist, DMV
DABVP, Cert. IVUSS

IMAGING PERFORMED BY

Dr. Rodriguez

HOSPITAL NAME

Foxfield VS

REFERRING VET

Dr. Rodriguez

INVOICE

95564

DATE

1/26/22

PRESENTING CLINICAL SIGNS

Sedated with torb for the echo. Heart murmur 2-3/6. Currently on 1.25mg vetmedin 1 tab am and 1/2 tab pm as well as lasix due to a prev diagnosed cough

ULTRASONOGRAPHIC EXAMINATION OF THE HEART

The echocardiogram in this patient demonstrated normal **left atrial** size based on 3 separate LA measurements. The cranial and caudal **mitral** valve leaflets presented normal linear structure and kinetics.. The **left ventricle** presented normal thicknesses with linear contour and was not dilated nor restricted. The **myocardium** presented normal echogenicity without subjective evidence of significant fibrotic or ischemic disease. **Contractility** of the ventricular walls was adequate and in normal range for this patient evidenced by the fractional shortening measurement and subjective evaluation of the different regions and angles of the myocardium. The **left ventricular outflow** tract demonstrated normal laminar flow and subjective structural integrity. The **right atrium** and auricle revealed normal size, structure and content. No evidence of masses was noted or chamber overload. **Tricuspid** valvular assessment demonstrated adequate linear morphology and kinetics. The **right ventricle** was of normal size (1/3 diameter of LV), chordae structure, myocardial echogenicity and thickness. **Pulmonic** tract assessment revealed normal valve structure, laminar flow, and diameter (approx.1:1 pa/ao ratio). No visible **pericardial** or free pleura fluid was noted or extra cardiac pathology in the visible planes. The cranial **mediastinum and pericardial regions** were free of masses in the visible window. Slight comet tail pattern is noted in the lung fields. Mildly excessive cardiac fat was noted.

FELINE CARDIAC PARAMETERS	BODY WEIGHT (kg)	HR (BPM)	IVSd (cm)	LVIDd (cm)	LVWd (cm)	FS (%)	EF (%)
NORMAL PARAMETER	-----	150-240	0.3-0.6	1.0-2.1	0.25-0.6	35-67	80-100
PATIENT		NM		1.5		45	90
FELINE CARDIAC PARAMETERS	LA/AO (Boon)	LA/AO HEART BASE (Sisson)	LA 2D 4-chamber long axis AS to FW (Sisson) (cm)	LVOT VEL. (m/s)	RVOT VEL. (m/s)	IVRT (m/)	
NORMAL PARAMETER	<1.5	0.88-1.79	0.7-1.7	<1.6	<1.3	40-60	
PATIENT	1.0	1.12	1.2 max		1.2	NM	
Adapted from June Boon, Veterinary Echocardiography, 1998 Sisson D et al. JVIM 1991; 5: 232, Jacobs et al. Am J Vet Res 1985; 46:1705							

ULTRASONOGRAPHIC FINDINGS

Normal echocardiogram.

Comet tail pattern in lung fields.



PATIENT

Mowgli Scarpino

INTERPRETATION OF THE FINDINGS & FURTHER RECOMMENDATIONS

SPECIES

Feline

There was no evidence of volume overload or significant structural disease. The volume and function is normal. No significant murmur is detected, yet this is likely a flow murmur and common in cats. I recommend weaning off cardiac medications at this point. The cough is not cardiogenic at this time. Primary bronchial disease or heartworm are the primary concerns with cough in cats. It is possible that the patient underwent an episode of myocarditis causing temporary cardiac ingestion. However at this time there is no evidence of structural or functional disease.

BREED

Domestic Shorthair

Benign flow murmurs are common in cats. This may be owing to volume shifts, tachycardia, benign (DRVOTO) right ventricular outflow changes, trivial turbulence in any of the valvular apparatuses, or possibly excessive stethoscope pressure against the chest according to a recent study These are physiologically benign and unrelated to specific pathology.

SEX

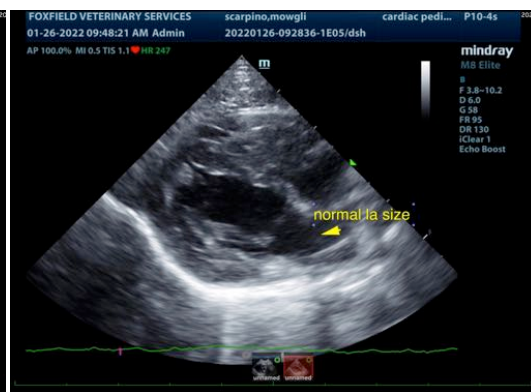
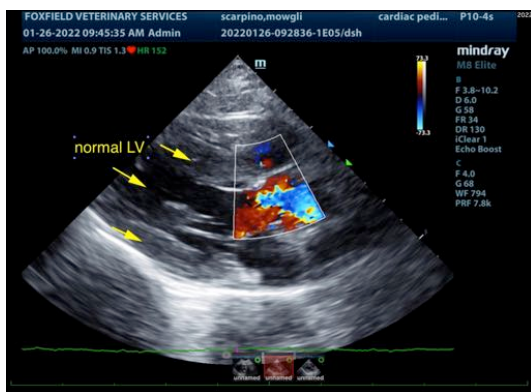
Neutered male

AGE

4 years

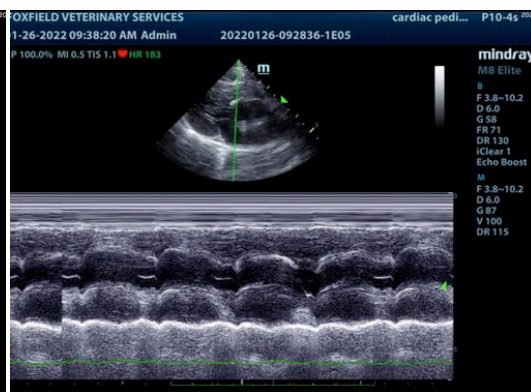
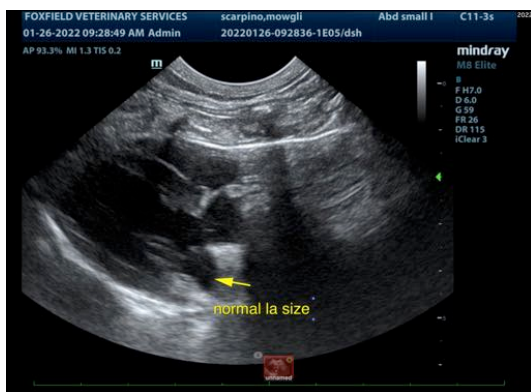WEIGHT

17.5 lbs



INTERPRETED BY

Eric Lindquist, DMV
DABVP, Cert. IVUS



IMAGING PERFORMED BY

Dr. Rodriguez

HOSPITAL NAME

Foxfield VS

REFERRING VET

Dr. Rodriguez

INVOICE

95564

DATE

1/26/22



PATIENT

Mowgli Scarpino

SPECIES

Feline

BREED

Domestic Shorthair

SEX

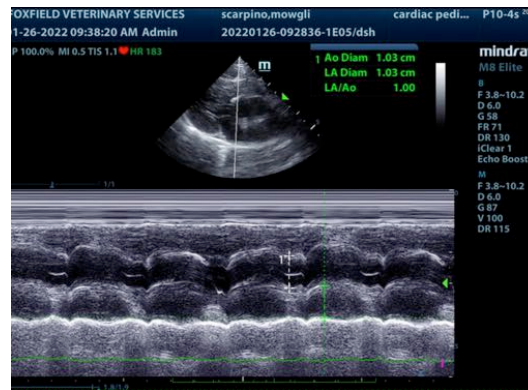
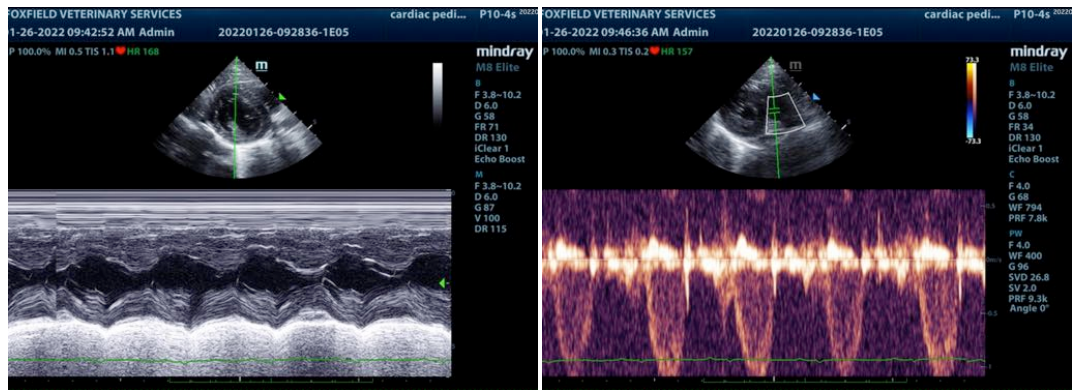
Neutered male

AGE

4 years

WEIGHT

17.5 lbs



INTERPRETED BY

Eric Lindquist, DMV
DABVP, Cert. IVUSS

IMAGING PERFORMED BY

Dr. Rodriguez

HOSPITAL NAME

Foxfield VS

REFERRING VET

Dr. Rodriguez

INVOICE

95564

DATE

1/26/22

The information and recommendations provided are based on the images presented by the referring veterinarian/sonographer. No evaluation can be communicated regarding pathology that was not visible in the image/video clips provided.

Thank you for this referral. If the clinical or image interpretation does not parallel your findings or if I can be of any further assistance please contact me.

Eric Lindquist, DMV, DABVP, Cert. IVUSS, CEO of SonoPath.com
info@SonoPath.com