



PATIENT

Beans Bush Badolato

PRESENTING CLINICAL SIGNS

Cat presented with chronic vomiting and on/off eating. History of increased liver values. BCS - 5/9
Abnormal PE/Chem/CBC/UA Results: Alk Phos - 155 ALT -392 Rest panel WNL

SPECIES

Feline

ULTRASONOGRAPHIC EXAMINATION OF THE ABDOMEN

Urinary System

The **urinary bladder**, trigone, and pelvic urethra presented normal thicknesses and normal tone. The ureters were not visible which is normal. No uroliths or sediment were visualized and anechoic urine was present. No evidence of inflammatory or neoplastic changes was noted. Ureteral papillae were normal.

BREED

Domestic Medium Hair

SEX

Neutered male

The **kidneys** revealed largely normal size and structure, corticomedullary definition and ratio (cortex 1/3 of medulla) were essentially maintained with some age-related loss of curvilinear patterns regarding the capsule and C/M junction. The cortices presented largely uniform texture with some increased echogenicity expected for this age patient. Medullary structure differed distinctly from that of the cortex and no evidence of pelvic dilation was present. The left kidney measured 3.92 cm.

AGE

12 years

WEIGHT

9.8 lbs

Adrenal Glands

Both **adrenal glands** were visualized and recognized as having normal shape, size, position and echogenicity for this breed. The phrenic vasculature, glandular echogenicity and detail were unremarkable. Capsule, cortex, and medullary definition were normal for this age patient.

INTERPRETED BY

Eric Lindquist, DMV
DABVP, Cert. IVUSS

Spleen

The **spleen** was mildly enlarged with uniform, but subtly micronodular parenchyma, and undulating capsular contour. This is consistent with reactive spleen owing to immune stimulus or early infiltrative disease such as mast cell disease or lymphoma. 25-gauge FNA would be ideal if weight loss is an issue to differentiate early round cell neoplasia versus splenitis or reactive spleen all of which can present in this manner.

IMAGING PERFORMED BY

Dr. Leal

HOSPITAL NAME

Blairstown AH

Liver

The **liver** images submitted revealed subjectively normal liver size, contour, and structure. Parenchymal echogenicity was naturally coarse and hypoechoic to the spleen. Vascular and biliary tracts were of normal volume with no evidence of congestion. The gallbladder presented acceptably thin walls with primarily anechoic content. The cystic and common bile ducts were normal. No pathological hepatic lymphadenopathy was evident. No overt structural evidence of inflammatory, infiltrative or regenerative pathology was evident.

REFERRING VET

Dr. Summers

INVOICE

95573

DATE

1/26/22



PATIENT

Beans Bush Badolato

SPECIES

Feline

BREED

Domestic Medium Hair

SEX

Neutered male

AGE

12 years

WEIGHT

9.8 lbs

INTERPRETED BY

Eric Lindquist, DMV
DABVP, Cert. IVUSS

IMAGING PERFORMED BY

Dr. Leal

HOSPITAL NAME

Blairstown AH

REFERRING VET

Dr. Summers

INVOICE

95573

DATE

1/26/22

Gastrointestinal

Examination of the **gastrointestinal tract** revealed a stomach and intestine free of stasis, of normal wall thickness, acceptable curvilinear mural detail, and peristaltic activity. Retention of ingesta was noted in the stomach. Small and large intestine demonstrated normal luminal chyme and stool consistency respectively. No obstructive or overt infiltrative disease was noted. No associated abnormal lymphatic activity was noted.

Pancreas

The **pancreas** was hypoechoic with irregular, undulating contour.

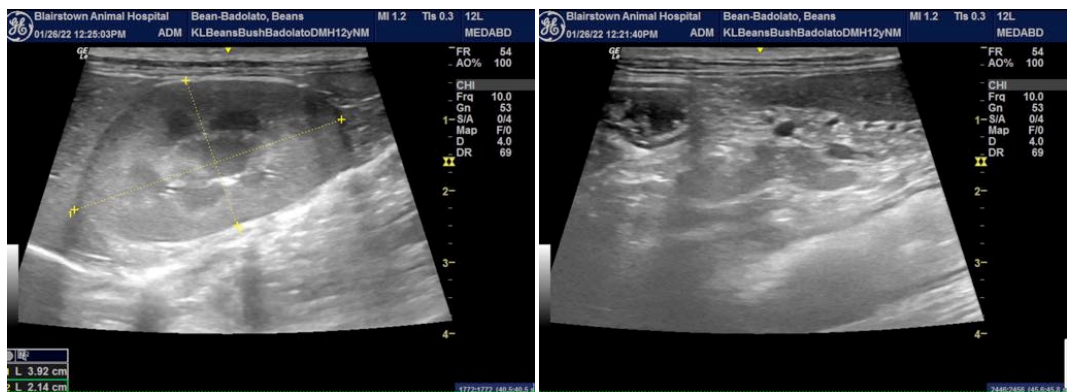
ULTRASONOGRAPHIC FINDINGS

Prominent, irregular pancreas.

Minor micronodular splenic changes.

INTERPRETATION OF THE FINDINGS & FURTHER RECOMMENDATIONS

I suspect history of pancreatitis and reactive spleen. There is a minor potential for emerging round cell neoplasia of the spleen. 25-gauge splenic FNA +/- culture and cytology is indicated. Subxiphoid palpation is recommended to assess for pain-solicited response. If pain is noted low grade pancreatitis is suspected. This is likely structurally insignificant inflammatory bowel with reactive hepatopathy and periodic pancreatitis. A clinical trial of the following may prove effective. However, underlying food intolerance is likely an issue.





PATIENT

Beans Bush Badolato

SPECIES

Feline

BREED

Domestic Medium Hair

SEX

Neutered male

AGE

12 years

WEIGHT

9.8 lbs

INTERPRETED BY

Eric Lindquist, DMV
DABVP, Cert. IVUSS

IMAGING PERFORMED BY

Dr. Leal

HOSPITAL NAME

Blairstown AH

REFERRING VET

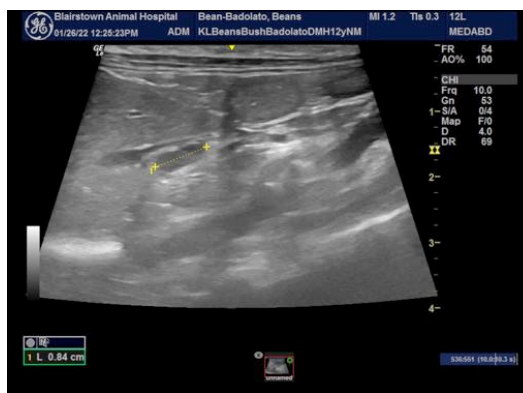
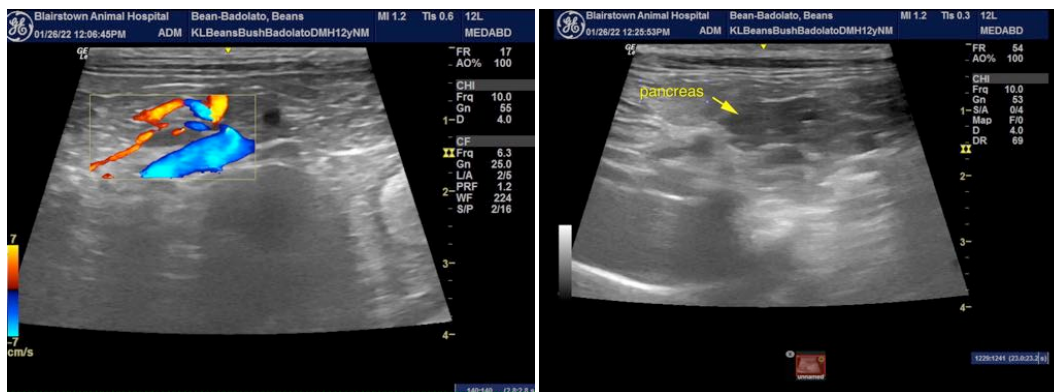
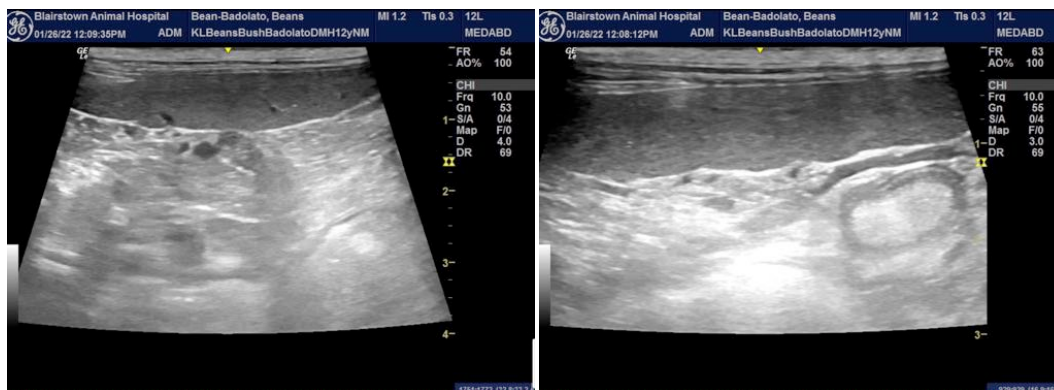
Dr. Summers

INVOICE

95573

DATE

1/26/22



The information and recommendations provided are based on the images presented by the referring veterinarian/sonographer. No evaluation can be communicated regarding pathology that was not visible in the image/video clips provided.

Thank you for this referral. If the clinical or image interpretation does not parallel your findings or if I can be of any further assistance please contact me.

Eric Lindquist, DMV, DABVP, Cert. IVUSS, CEO of SonoPath.com
info@SonoPath.com