

**PATIENT**

Loki Noll

**SPECIES**

Feline

**BREED**

DLH

**SEX**

Neutered Male

**AGE**

1 Year 8 Months

**WEIGHT**

5.25 kg

**INTERPRETED BY**

Eric Lindquist, DMV

DABVP, Cert. IVUSS

**IMAGING PERFORMED BY**

Jolee Stegemoller,  
DVM

**HOSPITAL NAME**

North Idaho AH

**REFERRING VET**

Talitha Neher, DVM

**INVOICE**

44479

**DATE**

1/25/23

**PRESENTING CLINICAL SIGNS**

Initially presented for urethral obstruction 12/19/22; CBC WNL at that time. Medical management (NSAID, buprenorphine, IV fluids, prazosin, gabapentin, enrichment, separate from aggressor cat, feliway plug in, composure treats, c/d stress dry and canned c/d). Patient experienced repeat episode and presented 1/16/23 for perineal urethrostomy. Preop labs at that time: marked neutropenia. Surgery not performed; obstruction relieved, patient urinating on own. IV cefazolin and IV fluids in clinic; started transdermal fluoxetine and convenia SC given at discharge (owners unable to give oral medications). Returned for recheck/possible obstruction 1/25. Weight loss.

Abnormal PE/Chem/CBC/UA Results: marked neutropenia verified with multiple samples and slide review on 1/16/23; WBC now 0.65 with decreased neutrophils, monocytes and lymphocytes vs WBC \* 0.65 today 2.87 - 17.02 K/ $\mu$ L L(1/16: two separate samples 1.00 \* 0.98) Neutrophils \* 0.16 2.30 - 10.29 K/ $\mu$ L L (1/16: 0.33 \* 0.29) Lymphocytes \* 0.40 0.92 - 6.88 K/ $\mu$ L L (1/16: 0.55 \* 0.55) Monocytes \* 0.05 0.05 - 0.67 K/ $\mu$ L ( 1/16: 0.08 \* 0.09) Eosinophils \* 0.02 0.17 - 1.57 K/ $\mu$ L L 0.03 \*

**ULTRASONOGRAPHIC EXAMINATION OF THE ABDOMEN**

**Urinary System**

The **urinary bladder** revealed sand accumulation and dependent debris. Sand measured approximately 1.0 cm, non-obstructive at the time of the sonogram. The bladder wall itself was unremarkable. The pelvic urethra was imaged 2.0 cm beyond the cystourethral junction.

The iliac trifurcation was unremarkable.

The **kidneys** revealed normal size and structure, corticomedullary definition and ratio for this age. The cortices presented largely uniform texture with normal echogenic relationship to liver and spleen. Medullary structure differed distinctly from the cortex and no evidence of pelvic dilation was present. The capsules were acceptably uniform without significant irregularities. The left kidney measured 4.0 cm. The right kidney measured 4.0 cm.

**Adrenal Glands**

Both **adrenal glands** were visualized and recognized as having normal shape, size, position and echogenicity for this breed. The phrenic vasculature, glandular echogenicity and detail were unremarkable. Capsule, cortex, and medullary definition were normal for this age patient. The left adrenal gland measured 0.33 cm. The right adrenal gland measured 0.40 cm.

**Spleen**

The **spleen** presented a smooth homogeneous parenchyma hyperechoic to liver and renal cortical parenchyma. The capsule was smooth without noticeable expansion or deviation from within the spleen or adjacent pathology. The splenic vasculature demonstrated normal volume without signs of congestion or thrombosis. No sonographic evidence of acute or chronic inflammatory, neoplastic, or infarctual changes were noted.

**Liver**

The **liver** images submitted revealed subjectively normal liver size, contour, and structure. Parenchymal echogenicity was naturally coarse and hypoechoic to the spleen. Vascular and biliary tracts were of normal volume with no evidence of congestion. The gallbladder presented acceptably thin walls with primarily anechoic content. The cystic and common bile ducts were normal. No pathological hepatic lymphadenopathy was evident. No overt structural evidence of inflammatory, infiltrative or regenerative pathology was evident.



**PATIENT**

Loki Noll

**SPECIES**

Feline

**BREED**

DLH

**SEX**

Neutered Male

**AGE**

1 Year 8 Months

**WEIGHT**

5.25 kg

**INTERPRETED BY**

Eric Lindquist, DMV

DABVP, Cert. IVUSS

**IMAGING PERFORMED BY**

Jolee Stegemoller, DVM

**HOSPITAL NAME**

North Idaho AH

**REFERRING VET**

Talitha Neher, DVM

**INVOICE**

44479

**DATE**

1/25/23

**Gastrointestinal**

The **stomach** was filled with hairball type density. The small intestine and colon were unremarkable. GI wall was unremarkable. Curvilinear patterns were maintained.

**Pancreas**

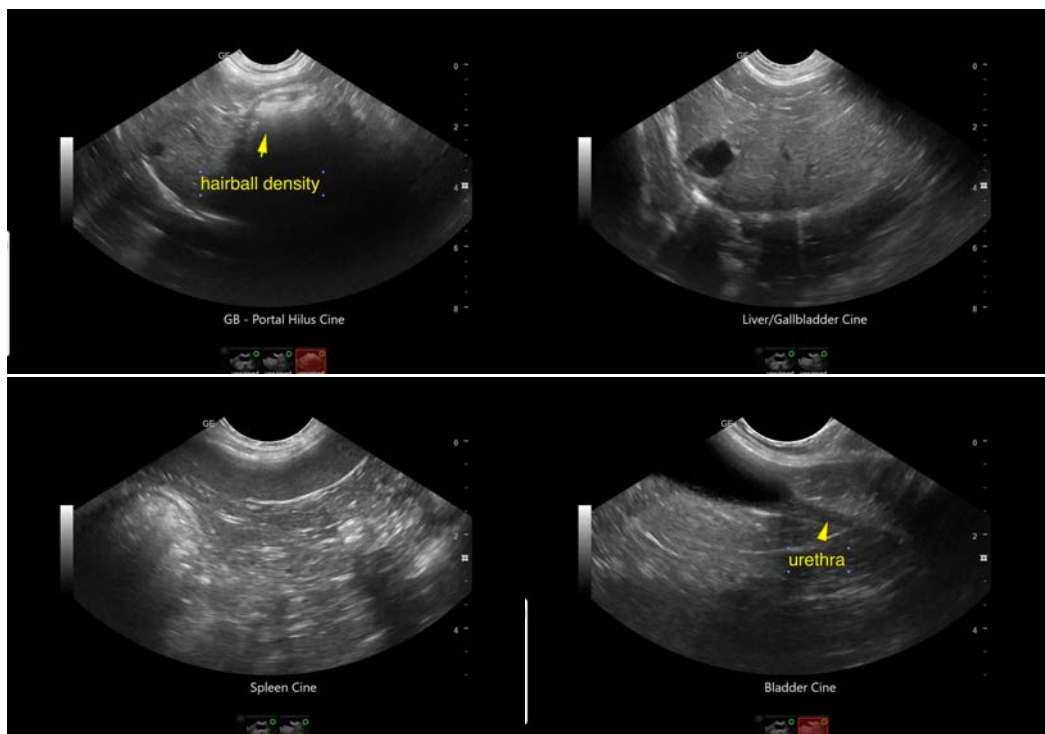
The base and limbs of the **pancreas** were observed to be largely isoechoic to surrounding omental fat. Pancreatic duct and capsular contour were acceptably normal and parenchyma respected normal curvilinear patterns. No overt evidence of active inflammatory or neoplastic disease was noted.

**ULTRASONOGRAPHIC FINDINGS**

- Bladder sand and debris – suspect UTI. No evidence of obstruction.
- Hairball density in the stomach
- Structurally unremarkable abdomen otherwise

**INTERPRETATION OF THE FINDINGS & FURTHER RECOMMENDATIONS**

Hairball therapy warranted. 4 week treatment for any evidence of UTI and dietary adjustment also indicated. No abdominal cause of weight loss, unless the patient is hyporexic owing to the presumed hairball accumulation in the stomach.





**PATIENT**

Loki Noll

**SPECIES**

Feline

**BREED**

DLH

**SEX**

Neutered Male

**AGE**

1 Year 8 Months

**WEIGHT**

5.25 kg

**INTERPRETED BY**

Eric Lindquist, DMV

DABVP, Cert. IVUSS

**IMAGING PERFORMED BY**

Jolee Stegemoller, DVM

**HOSPITAL NAME**

North Idaho AH

**REFERRING VET**

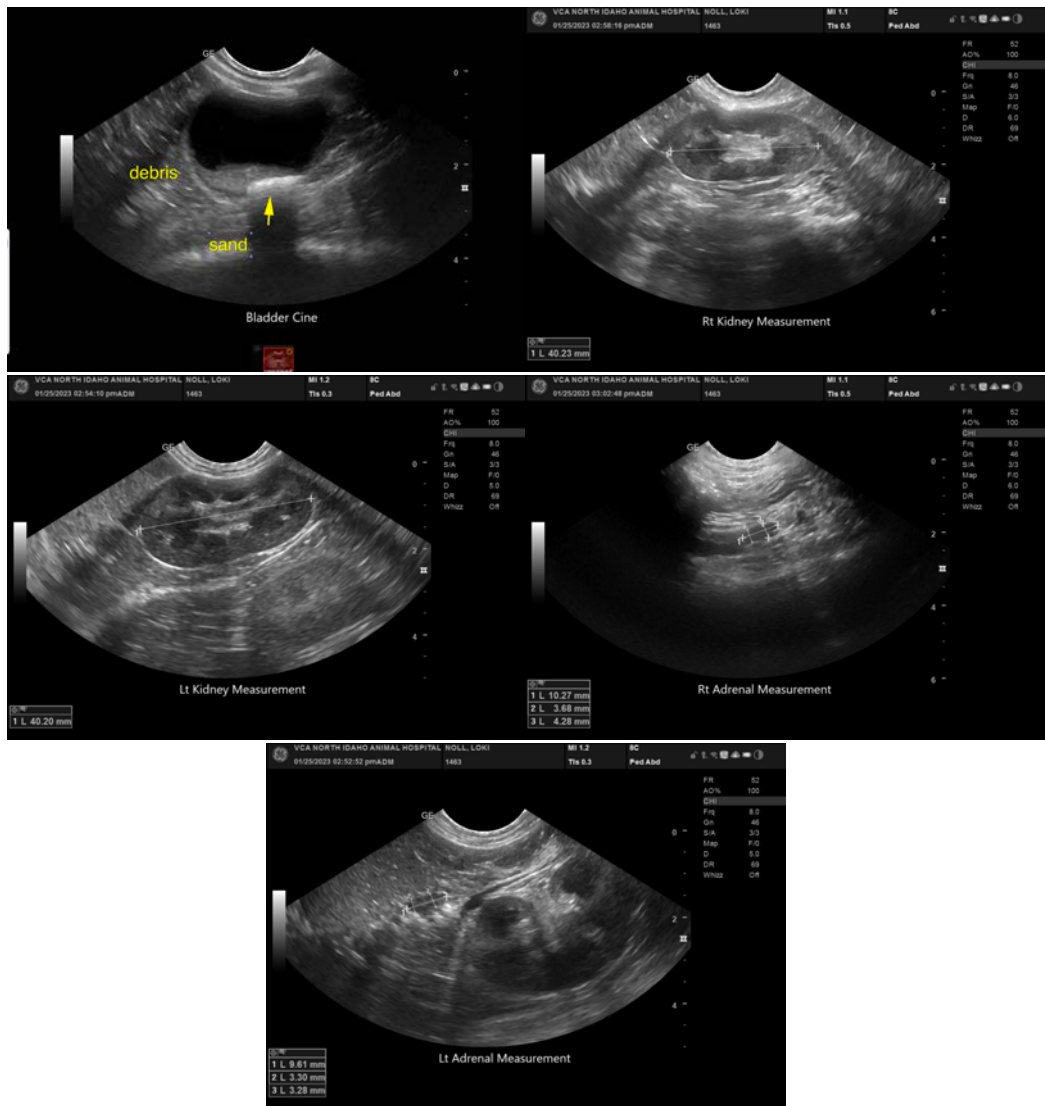
Talitha Neher, DVM

**INVOICE**

44479

**DATE**

1/25/23



The information and recommendations provided are based on the images presented by the referring veterinarian/sonographer. No evaluation can be communicated regarding pathology that was not visible in the image/video clips provided.

Thank you for this referral. If the clinical or image interpretation does not parallel your findings or if I can be of any further assistance please contact me.

**Eric Lindquist, DMV, DABVP, Cert. IVUSS, CEO of SonoPath.com**

[info@SonoPath.com](mailto:info@SonoPath.com)



**PATIENT**

Loki Noll

**SPECIES**

Feline

**BREED**

DLH

**SEX**

Neutered Male

**AGE**

1 Year 8 Months

**WEIGHT**

5.25 kg

**INTERPRETED BY**

Eric Lindquist, DMV

DABVP, Cert. IVUSS

**IMAGING PERFORMED BY**

Jolee Stegemoller,  
DVM

**HOSPITAL NAME**

North Idaho AH

**REFERRING VET**


Talitha Neher, DVM

**INVOICE**

44479

**DATE**

1/25/23



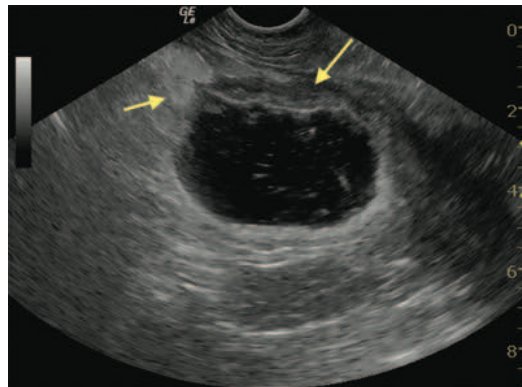
The following is an applicable excerpt from the *Curbside Guide to Diagnosis & Treatment of Sonographic Disease* offered by [SonoPath.com](http://sonopath.com) Lindquist, Frank, Lobetti, and Modler.

An essential quick guide for every general practitioner and sonographer.

<https://sonopath.com/products/curbside-guide-editing-due-release-12012015>

**Feline Idiopathic Cystitis**

<http://www.sonopath.com/FelineCystitis>



Short axis of the urinary bladder in a cat with chronic cystitis. Note the severe thickening and undulating surface of the bladder wall. The regular layers of the urinary bladder wall cannot be discerned (large arrow). There is a moderate amount of echogenic debris seen within the anechoic urine. Mild focal peritonitis is seen as echogenic perivesical fat (small arrow) consistent with adhesion formation stimulated by transmural pathology.

**Description:** Feline idiopathic cystitis (FIC) is defined as recurrent stranguria and hematuria in cats in the absence of an underlying cause. It is considered to be an exclusionary diagnosis once radiographs, ultrasound, coagulation profile, and aerobic urine culture by cystocentesis have eliminated the possibilities of urinary tract infection, urolithiasis, coagulopathies, and neoplasia. Clinical signs may resolve spontaneously within 3-7 days, with 30-50% recurrence within a year. Cats most frequently acquire the disease between the ages of 2 and 6, and although any breed is susceptible, Persian cats are overrepresented among those affected. Overweight spayed females and neutered males in a multi-cat household are at higher risk than their lean, solitary, or intact counterparts. Indoor, sedentary, dry-food eaters are at higher risk than outdoor cats that eat *ad libitum*. Psychosomatic influences—change of residence, new household members, pet additions, change of household objects—on the urinary bladder have been shown to play an important role in the pathophysiology of the disease. Neurogenic inflammation, decreased glycosaminoglycan concentration, and increased bladder permeability are tissue alterations found on histopathological review of affected bladders. Neurotransmitter P is increased in affected tissue and may be specifically targeted in eventual courses of treatment.

**Clinical Signs:** In the absence of an underlying urinary tract infection or evidence of neoplasia, FIC may present in an acute or chronic form with the following intermittent lower urinary tract symptoms: inappropriate urination (> 6 times/week in 70% of cases); stranguria (70%); hematuria (50%); and pollakiuria (80%).

**Diagnostics:** Since FIC is a diagnosis of exclusion, abdominal radiographs, abdominal ultrasound, blood pressure, coagulation profile, and urine culture are all required to rule out other differentials. Biopsy of



**PATIENT**

Loki Noll

the bladder wall can be useful to evaluate for lymphocytic plasmacytic inflammation, which can occur in some cases. Taking a history and having a thorough conversation about the cat's environmental stressors are imperative.

**SPECIES**

Feline

**Treatment:** Given that no specific cause has been cited and that FIC is considered a multifactorial disease, multimodal therapy is recommended. To date, no specific therapeutic has been effective in treating FIC.

**BREED**

DLH

Palliation with pain management can be achieved with buprenorphine (0.02 mg/kg PO, IM, or IV BID-TID for 3-4 days). Practitioners have attempted the following with varying results: the introduction of a strict canned food diet; a change of feeding location in multi-cat households; and stimulating increased water intake using tuna or clam juice additives or circulating water fountains. To date, the most scientifically valid evidence points to the need for reducing urine concentration, which is achieved with canned food diets. In multiple studies, the simple act of switching to a canned therapeutic diet has been shown to reduce the risk of recurrence significantly. One study showed that only 11% of cats on a canned diet exhibited recurrent signs after a year, while those on a dry food diet displayed a 40% recurrence rate.

**SEX**

Neutered Male

Urine concentration can be reduced further by adding additional water into servings of canned food. Reduction of stress may be achieved by increasing litter box hygiene, placing the litter box in a quieter environment, and providing separate food, water, and litter areas for the affected patient in a multi-cat household. It has been suggested that Feliway, the feline facial pheromone, can be used as a calming agent for cats when they are in unfamiliar surroundings. Feliway mimics the natural facial hormone released when a cat marks his or her territory by face rubbing. For unresponsive or severe cases, amitriptyline (10 mg PO Q24hr at bedtime) has been shown to have visceral analgesic, anticholinergic, mucosal mast cell inhibition, and anti-noradrenergic properties. Amitriptyline is considered standard therapy, but is only pursued once the preceding husbandry and feeding practices have proven to be ineffective. Amitriptyline should be used with caution in patients with cardiac disease or arrhythmias, and if instituted, should be used long-term. Studies indicate that short-term use of amitriptyline can result in faster recurrences.

**AGE**

1 Year 8 Months

Note: Urine retention may occur while therapy is being administered. Biochemical panels should be monitored while a patient is undergoing amitriptyline therapy as liver enzyme elevation can occur. Glycosaminoglycan supplementation (pentosan polysulphate 2-10 mg/kg PO BID) has shown modest success (10-20%) in human trials for idiopathic cystitis. If used, a powder form is recommended to avoid the stress of pill administration (feline Cosequin capsules contain a powder that can be sprinkled onto food). Antiviral agents have not been shown to be effective, and even though researchers have suggested that the concurrent presence of *Calicivirus* may play a role and virus-like particles have been identified in urethral plugs and urine, no adequate evidence of a viral etiology has yet been demonstrated. A double-blind placebo trial suggested that glucocorticoids had no clinical benefits in 12 cases. All cases were self-limiting, in spite of whether the subjects were medicated with corticosteroids or not.

**WEIGHT**

5.25 kg

**INTERPRETED BY**

Eric Lindquist, DMV

DABVP, Cert. IVUSS

**IMAGING PERFORMED BY**

Jolee Stegemoller, DVM

**HOSPITAL NAME**

North Idaho AH

If hematuria seems persistent despite therapy and does not follow a typical FIC pattern (i.e., resolving within one week but recurring within a few weeks), cystoscopy or surgical evaluation may be indicated. Biopsies can be obtained, which allows for histopathology and bladder wall culture.

**REFERRING VET**

Talitha Neher, DVM

Environmental enrichment is also important to reduce stress. Providing vertical climbing surfaces, such as cat trees, increasing the number of litter boxes on different floors of the house (the rule of thumb is the number of litter boxes per house should equal the number of cats plus one), and increasing owner attention time, scheduled playtime, as well as supervised outdoor activity can decrease stress for cats.

**INVOICE**

44479

**DATE**

1/25/23

**Conclusion:** Effective treatment of FIC involves a multi-modal approach with a strong emphasis on husbandry. Pet owners should focus on the fastidious upkeep of litter boxes and feed their cats canned food to both increase dietary water intake and maintain their cat's lean body weight. Stress management is also key and can be facilitated with environmental enrichment as well as an understanding of feline behavior.



**PATIENT**

Loki Noll

**SPECIES**

Feline

**BREED**

DLH

**SEX**

Neutered Male

**AGE**

1 Year 8 Months

**WEIGHT**

5.25 kg

**INTERPRETED BY**

Eric Lindquist, DMV

DABVP, Cert. IVUSS

**IMAGING PERFORMED BY**

Jolee Stegemoller,  
DVM

**HOSPITAL NAME**

North Idaho AH

**REFERRING VET**

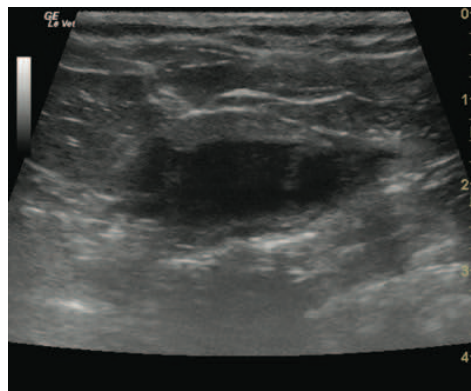
Talitha Neher, DVM

**INVOICE**

44479

**DATE**

1/25/23



Long axis view of 5-year-old FS feline bladder suffering from clinical signs of hematuria, inappropriate urination and straining. The ventral bladder wall is segmentally thickened. Feline interstitial cystitis is highly variable in presentation and can change sonographically from day to day. This enigma of a disease necessitates further investigation but sonographically, transmural erosion should be monitored as necrosis and perforation can occur.

**References:**

Buffington CA, Westropp JL, et al. Clinical evaluation of multimodal environmental modification (MEMO) in the management of cats with idiopathic cystitis. *J Feline Med Surg* 2006;8:261-68.

Chew DJ, Buffington CA, Kendall MS, et al. Amitriptyline treatment for severe recurrent idiopathic cystitis in cats. *J Am Vet Med Assoc* 1998;213(9):1282-86.

Defauw PAM, Van de Maele I, et al. Risk factors and clinical presentation of cats with feline idiopathic cystitis. *J Feline Med Surg* 2011;13(12):967-75.

Kraijer M, Fink-Gremmels J, Nickel RF. The short-term efficacy of amitriptyline in the management of idiopathic feline lower urinary tract disease: a controlled clinical study. *J Feline Med Surg* 2003;5(3):191-96.

Kruger JM, Conway TS, Kaneene JB, et al. Randomized controlled trial of the efficacy of short-term amitriptyline administration for treatment of acute, nonobstructive, idiopathic lower urinary tract disease in cats. *J Am Vet Med Assoc* 2003;222(6):749-58.

Westropp JL, Kass PH, Buffington CA. Evaluation of the effects of stress in cats with idiopathic cystitis. *Am J Vet Res* 2006;67:731-36.