**DATE**

1/25/23

**PATIENT**

Asher Martin

**SPECIES**

Canine

**BREED**

Golden Mix

**SEX**

Neutered male

**AGE**

8/9/21

**WEIGHT**

55 lbs

**INTERPRETED BY**Eric Lindquist, DMV  
DABVP, Cert. IVUSS**HOSPITAL NAME**

Mount Airy AH

**REFERRING VET**

Dr. Atchley

**INVOICE**

42332

**PRESENTING CLINICAL SIGNS**

Vomiting, restlessness, drooling, inappetence, uncontrollable licking.

Current Medications: Famotidine injection, Cerenia injection, Metoclopramide.

Radiographs: Thickened stomach lining, increased SI mobility, gas filled distended large GI with possible torsion at turn to descending colon. Barium study had rapid moving through most of GI, had gotten through most of GI after 4 hours, but dog left prior to seeing if entered the descending colon.

Date of Previous IntraPet Ultrasound: No previous.

Sedation: Declined, required for further imaging.

Stat Report: Not requested.

Imaging Performed By: Rachel Brillhart, RDMS.

**ULTRASONOGRAPHIC EXAMINATION OF THE ABDOMEN****Urinary System**

The **urinary bladder**, trigone, and pelvic urethra presented normal thicknesses and normal tone. The ureters were not visible which is normal. No uroliths or sediment were visualized and anechoic urine was present. No evidence of inflammatory or neoplastic changes was noted. Ureteral papillae were normal.

The **kidneys** revealed normal size and structure, corticomedullary definition and ratio for this age. The cortices presented largely uniform texture with normal echogenic relationship to liver and spleen. Medullary structure differed distinctly from the cortex and no evidence of pelvic dilation was present. The capsules were acceptably uniform without significant irregularities. The left kidney measured 6.02 cm. The right kidney measured 6.44 cm with slight pinpoint mineralization noted.

**Adrenal Glands**

Both **adrenal glands** were visualized and recognized as having normal shape, size, position and echogenicity for this breed. The phrenic vasculature, glandular echogenicity and detail were unremarkable. Capsule, cortex, and medullary definition were normal for this age patient. The left adrenal gland measured 2.87 x 0.72 cm at the caudal pole and 0.64 cm at the cranial pole. The right adrenal gland measured 3.3 x 0.74 cm at the caudal pole and 0.78 cm at the cranial pole.

**Spleen**

The **spleen** presented a smooth homogeneous parenchyma hyperechoic to liver and renal cortical parenchyma. The capsule was smooth without noticeable expansion or deviation from within the spleen or adjacent pathology. The splenic vasculature demonstrated normal volume without signs of congestion or thrombosis. No sonographic evidence of acute or chronic inflammatory, neoplastic, or infarctual changes was noted.

**Liver**

The **liver** revealed multi-focal, hypoechoic nodular changes with swollen, irregular contour. Slight free fluid was noted between the liver lobes. The gallbladder presented acceptably thin walls with primarily anechoic content. The cystic and common bile ducts were normal. No pathological hepatic lymphadenopathy was evident.

**Gastrointestinal**

Examination of the **gastrointestinal tract** revealed a stomach and intestine free of stasis, of normal wall thickness, acceptable curvilinear mural detail, and peristaltic activity. Small and large intestine demonstrated normal luminal chyme and stool consistency respectively. No obstructive or overt infiltrative disease was noted. No associated abnormal lymphatic activity was noted.

## Pancreas

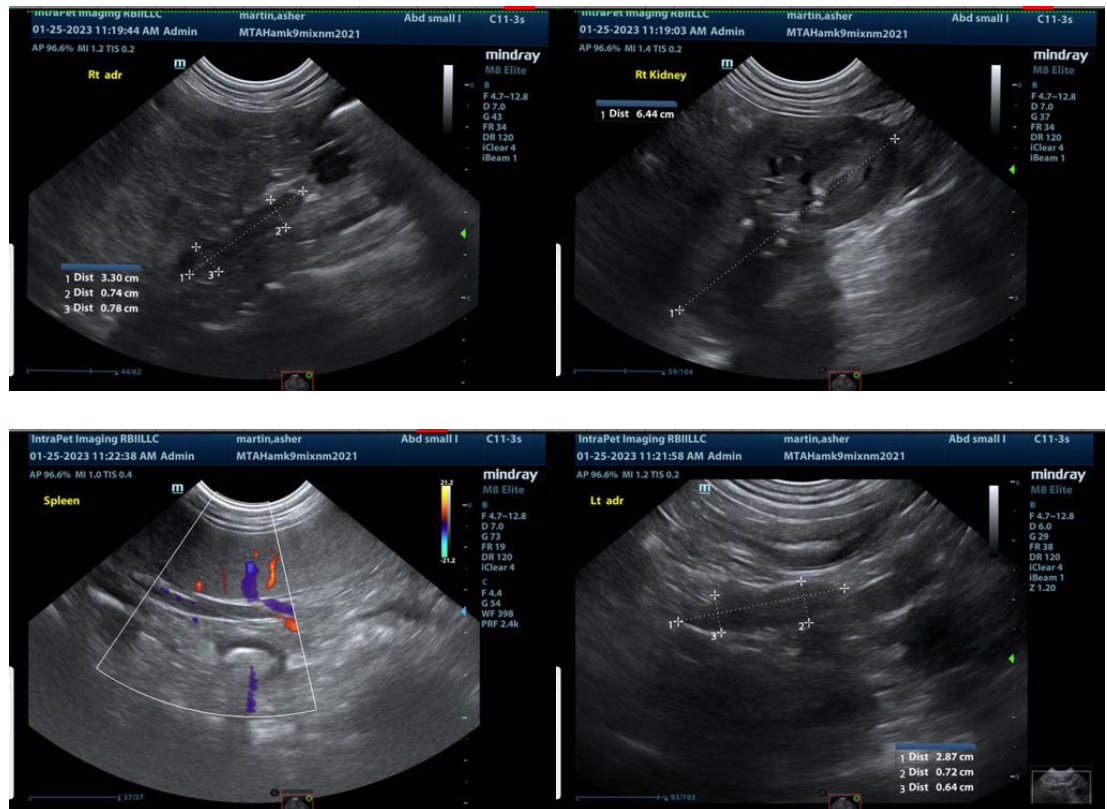
The base and limbs of the **pancreas** were observed to be largely isoechoic to surrounding omental fat. Some parenchymal remodeling, however, with mild deviation from curvilinear normalcy was observed. Pancreatic duct and capsular irregularities were present consistent with age related changes. If pain upon imaging (+ Murphy sign) was present or if the patient is focally painful in subxiphoid palpation then low-grade smoldering chronic pancreatitis should be suspected.

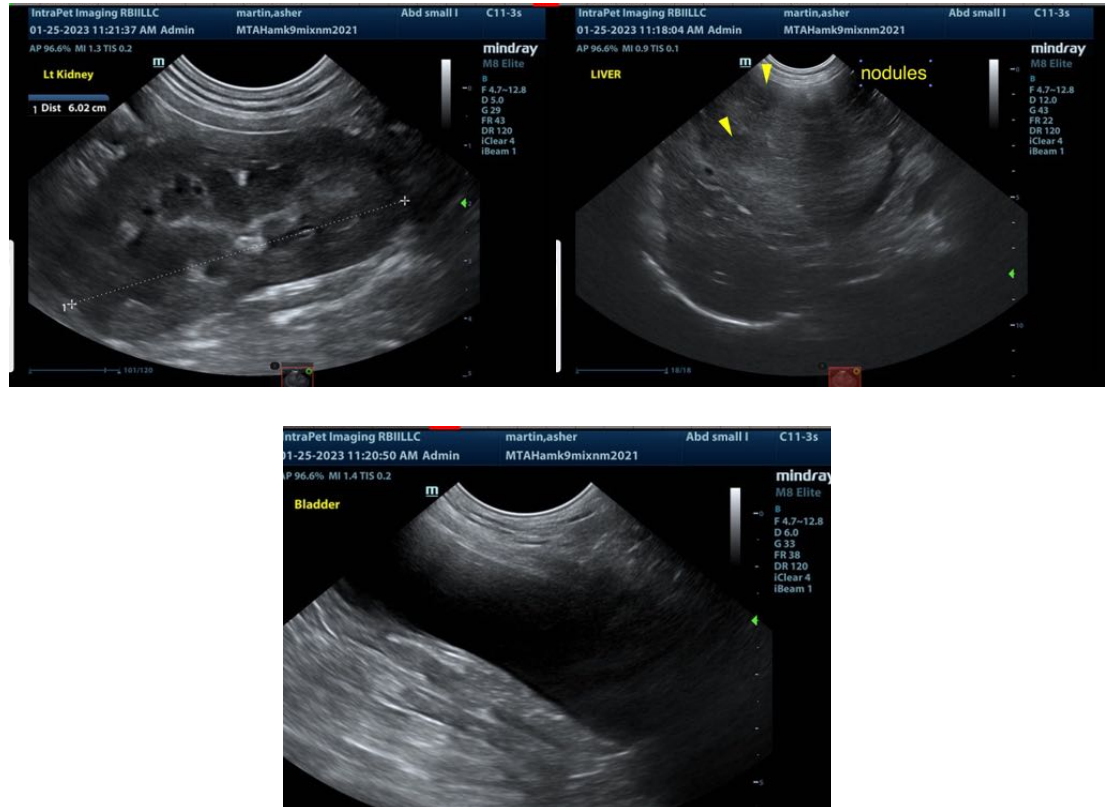
## ULTRASONOGRAPHIC FINDINGS

Undefined nodular hepatomegaly with slight free fluid.

## INTERPRETATION OF THE FINDINGS & FURTHER RECOMMENDATIONS

There is strong concern for underlying neoplasia. Pronounced nodular hyperplasia is possible, yet less likely. FNA of the liver is essential in this case.





The information and recommendations provided are based on the images presented by the referring veterinarian. No evaluation can be communicated regarding pathology that was not visible in the image/video clips provided.

Thank you for this referral. If the clinical or image interpretation does not parallel your findings or if I can be of any further assistance please contact me.

**Eric Lindquist, DMV, DABVP, Cert. IVUSS, CEO of SonoPath.com**  
Eric.Lindquist@SonoPath.com