



PATIENT

Tanner Griffin

SPECIES

Canine

BREED

Lhasa Apso

SEX

Neutered male

AGE

13 years

WEIGHT

13.5 lbs

INTERPRETED BY

Eric Lindquist, DMV
DABVP, Cert. IVUSS

IMAGING PERFORMED BY

Dr. Beard

HOSPITAL NAME

West Prince AH

REFERRING VET

Dr. Beard

INVOICE

95488

DATE

1/25/22

PRESENTING CLINICAL SIGNS

Acute onset of lethargy, ataxia, and disinclination to move. Would not eat this morning. Seizure activity. Abnormal PE/Chem/CBC/UA Results: Neutrophilic leukocytosis, monocytosis, hemoconcentration, dilute urine, and an increase in the albumin, ALP, ALT, T bili, BUN, Ca, Phos, Creatinine and Potassium. Plain view xrays reveal arthritis elbows, stifles, and spine and a mass in the cranial abdomen.

ULTRASONOGRAPHIC EXAMINATION OF THE ABDOMEN

Urinary System

The **urinary bladder**, trigone, and pelvic urethra presented normal thicknesses and normal tone. The ureters were not visible which is normal. No uroliths or sediment were visualized and anechoic urine was present. No evidence of inflammatory or neoplastic changes was noted. Ureteral papillae were normal.

The **kidneys** were swollen with mild pyelectasia. Slight subcapsular fluid accumulation was noted. Mild, age related, increased cortical echogenicity is noted. Occasional cortical cysts were noted. The left kidney measured 4.0 cm. The right kidney revealed minor pyelectasia and was swollen. The right kidney measured 4.3 cm. The vascularity appeared normal.

Adrenal Glands

The right adrenal gland was normal and measured 0.6 cm at the cranial pole and 0.4 cm at the caudal pole. The region of the left adrenal gland was imaged with no evidence of pathology.

Spleen

The **spleen** presented a smooth homogeneous parenchyma hyperechoic to liver and renal cortical parenchyma. The capsule was smooth without noticeable expansion or deviation from within the spleen or adjacent pathology. The splenic vasculature demonstrated normal volume without signs of congestion or thrombosis. No sonographic evidence of acute or chronic inflammatory, neoplastic, or infarctual changes was noted.

Liver

A right-sided inflamed caudate **liver** mass was noted as well. The mass measured 5.5 cm and was moderately complex. The remainder of the liver revealed increased portal markings and swelling. The gallbladder presented striating bile. Round, enhanced, pericapsular inflammation was noted. The gallbladder measured 5.0 x 4.0 cm in long axis. The common bile duct was visualized and mildly dilated with a minor amount of mucous debris measuring 0.4 cm. This is consistent with mucoduct.

Gastrointestinal

Examination of the **gastrointestinal tract** revealed a stomach and intestine free of stasis, of normal wall thickness, acceptable curvilinear mural detail, and peristaltic activity. Small and large intestine



PATIENT

demonstrated normal luminal chyme and stool consistency respectively. The cecum was static and dilated.

Tanner Griffin

SPECIES

Pancreas

Canine

Minor heterogenous **pancreatic** inflammation was present. .

BREED

ULTRASONOGRAPHIC FINDINGS

Lhasa Apso

Inflamed gallbladder mucocele with caudate liver mass.

SEX

Concurrent nephritis pattern.

Neutered male

Heterogenous pancreas.

AGE

INTERPRETATION OF THE FINDINGS & FURTHER RECOMMENDATIONS

13 years

Surgical intervention is recommended with caudate lobectomy, cholecystectomy and common bile duct lavage. I suspect hepatocellular carcinoma of the caudate process as well as inflamed gallbladder mucocele. Both appear to be potentially resolvable from a surgical standpoint. Guarded prognosis. This is a surgical emergency. Coagulation panel, plasma transfusion, plasma expanders and broad spectrum antibiotics are all warranted prior to surgery.

WEIGHT

13.5 lbs

INTERPRETED BY

Eric Lindquist, DMV
DABVP, Cert. IVUS

IMAGING PERFORMED BY

Dr. Beard

HOSPITAL NAME

West Prince AH

REFERRING VET

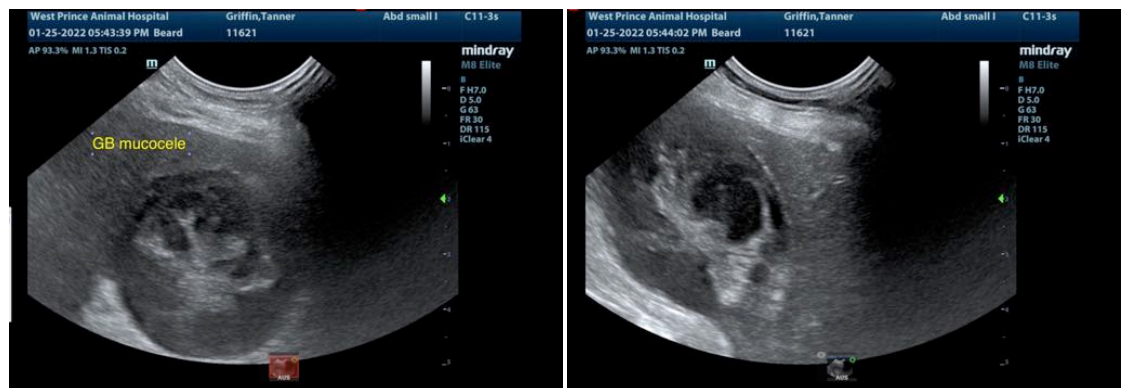
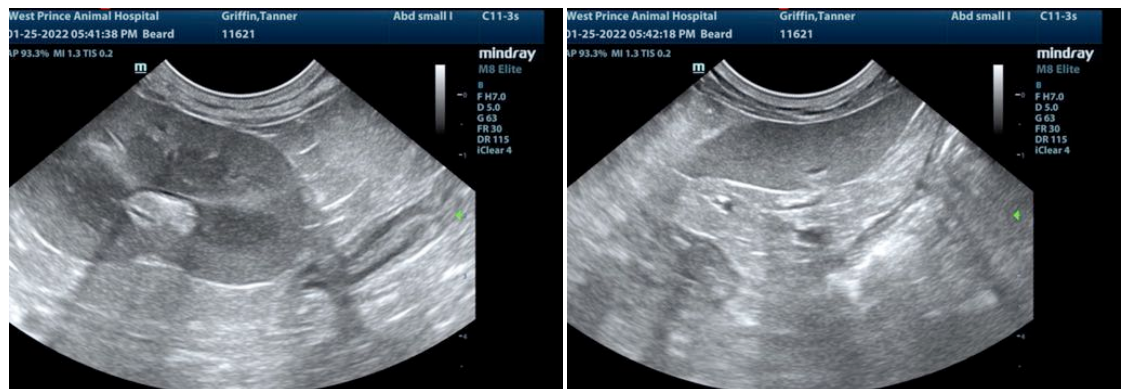
Dr. Beard

INVOICE

95488

DATE

1/25/22





PATIENT

Tanner Griffin

SPECIES

Canine

BREED

Lhasa Apso

SEX

Neutered male

AGE

13 years

WEIGHT

13.5 lbs

INTERPRETED BY

Eric Lindquist, DMV
DABVP, Cert. IVUSS

IMAGING PERFORMED BY

Dr. Beard

HOSPITAL NAME

West Prince AH

REFERRING VET

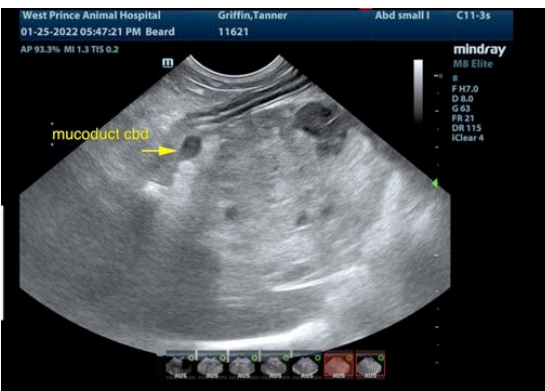
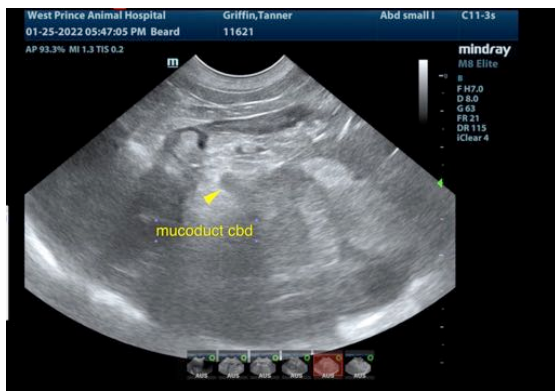
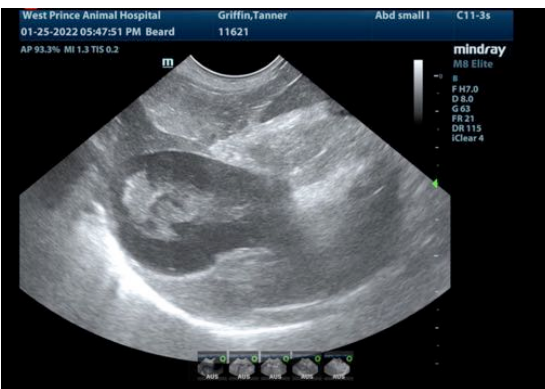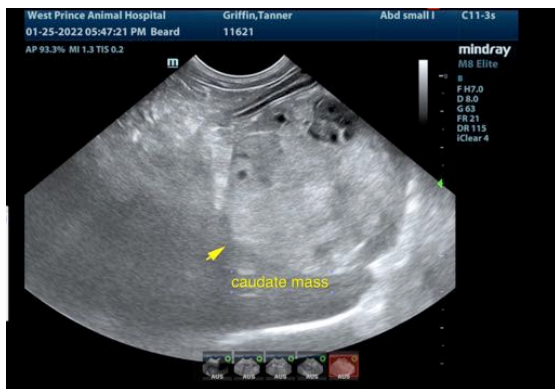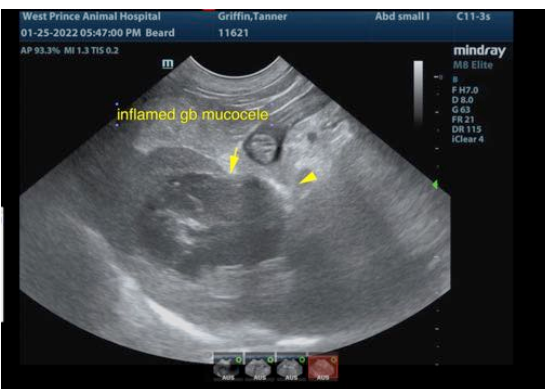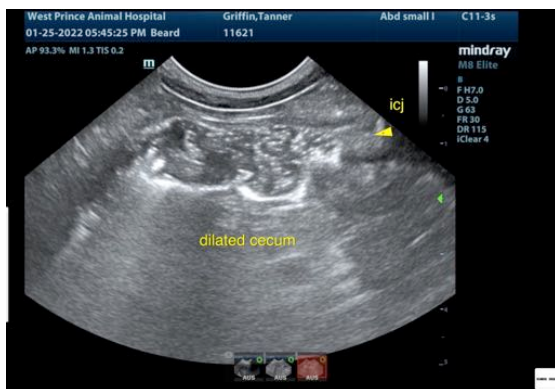
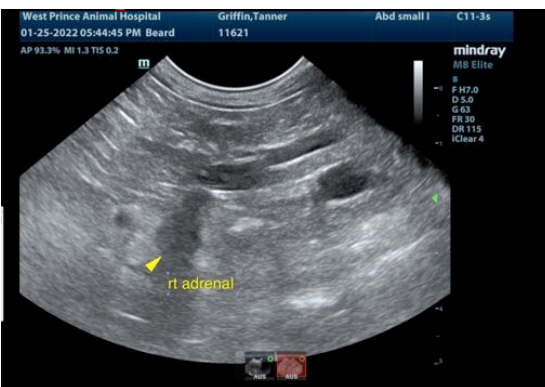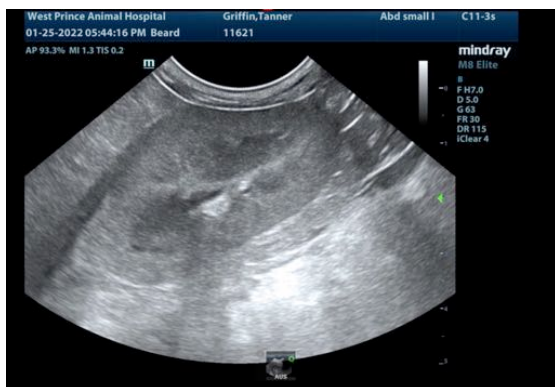Dr. Beard

INVOICE

95488

DATE

1/25/22





PATIENT

Tanner Griffin

SPECIES

Canine

BREED

Lhasa Apso

SEX

Neutered male

AGE

13 years

WEIGHT

13.5 lbs

INTERPRETED BY

Eric Lindquist, DMV
DABVP, Cert. IVUSS

**IMAGING
PERFORMED BY**

Dr. Beard

HOSPITAL NAME

West Prince AH

REFERRING VET

Dr. Beard

INVOICE

95488

DATE

1/25/22

The information and recommendations provided are based on the images presented by the referring veterinarian/sonographer. No evaluation can be communicated regarding pathology that was not visible in the image/video clips provided.

Thank you for this referral. If the clinical or image interpretation does not parallel your findings or if I can be of any further assistance please contact me.

Eric Lindquist, DMV, DABVP, Cert. IVUSS, CEO of SonoPath.com
info@SonoPath.com