



**PATIENT**

Stormi Guerrero

**PRESENTING CLINICAL SIGNS**

Not eating, vomiting, lethargy, weak

**SPECIES**

Canine

**ULTRASONOGRAPHIC EXAMINATION OF THE ABDOMEN**

**Urinary System**

**BREED**

French Bulldog

The **urinary bladder**, trigone, and pelvic urethra presented normal thicknesses and normal tone. The ureters were not visible which is normal. No uroliths or sediment were visualized and anechoic urine was present. No evidence of inflammatory or neoplastic changes was noted. Ureteral papillae were normal.

**SEX**

Female

The **kidneys** revealed normal size and structure, corticomedullary definition and ratio for this age. The cortices presented largely uniform texture with normal echogenic relationship to liver and spleen. Medullary structure differed distinctly from the cortex and no evidence of pelvic dilation was present. The capsules were acceptably uniform without significant irregularities. The right kidney measured 3.1 cm. The left kidney measured 3.3 cm.

**AGE**

7 weeks

**WEIGHT**

2 lbs

**Adrenal Glands**

Both **adrenal glands** were visualized and recognized as having normal shape, size, position and echogenicity for this breed. The phrenic vasculature, glandular echogenicity and detail were unremarkable. Capsule, cortex, and medullary definition were normal for this age patient. The right adrenal gland measured 0.4 cm.

**INTERPRETED BY**

Eric Lindquist, DMV  
DABVP, Cert. IVUSS

**Spleen**

The **spleen** presented a smooth homogeneous parenchyma hyperechoic to liver and renal cortical parenchyma. The capsule was smooth without noticeable expansion or deviation from within the spleen or adjacent pathology. The splenic vasculature demonstrated normal volume without signs of congestion or thrombosis. No sonographic evidence of acute or chronic inflammatory, neoplastic, or infarctual changes was noted.

**IMAGING PERFORMED BY**

Jenn

**HOSPITAL NAME**

Rockaway AH

**Liver**

The **liver** images submitted revealed subjectively normal liver size, contour, and structure. Parenchymal echogenicity was naturally coarse and hypoechoic to the spleen. Vascular and biliary tracts were of normal volume with no evidence of congestion. The gallbladder presented acceptably thin walls with primarily anechoic content. The cystic and common bile ducts were normal. No pathological hepatic lymphadenopathy was evident. No overt structural evidence of inflammatory, infiltrative or regenerative pathology was evident. Comet tail lung pattern was noted through the diaphragm.

**REFERRING VET**

Dr. Maniar

**INVOICE**

95487

**DATE**

1/25/22



**PATIENT**

**Gastrointestinal**

Stormi Guerrero

The **stomach** in this patient was hypertrophied with a mild amount of luminal fluid hyperperistalsis noted in the small intestine.

**SPECIES**

Canine

**Pancreas**

The base and limbs of the **pancreas** were observed to be largely isoechoic to surrounding omental fat. Pancreatic duct and capsular contour were acceptably normal and parenchyma respected normal curvilinear patterns. No overt evidence of active inflammatory or neoplastic disease was noted.

**BREED**

French Bulldog

**SEX**

Female

**ULTRASONOGRAPHIC FINDINGS**

Thickened stomach. Gastritis pattern.

Comet tail lung pattern, suspect pneumonitis or other pulmonary pathology as cause of the anorexia.

**AGE**

7 weeks

**INTERPRETATION OF THE FINDINGS & FURTHER RECOMMENDATIONS**

Chest radiographs are recommended to assess for pneumonitis as cause for the clinical signs. Worm burden should be considered as well.

**WEIGHT**

2 lbs

**INTERPRETED BY**

Eric Lindquist, DMV  
DABVP, Cert. IVUSS

**IMAGING PERFORMED BY**

Jenn

**HOSPITAL NAME**

Rockaway AH

**REFERRING VET**

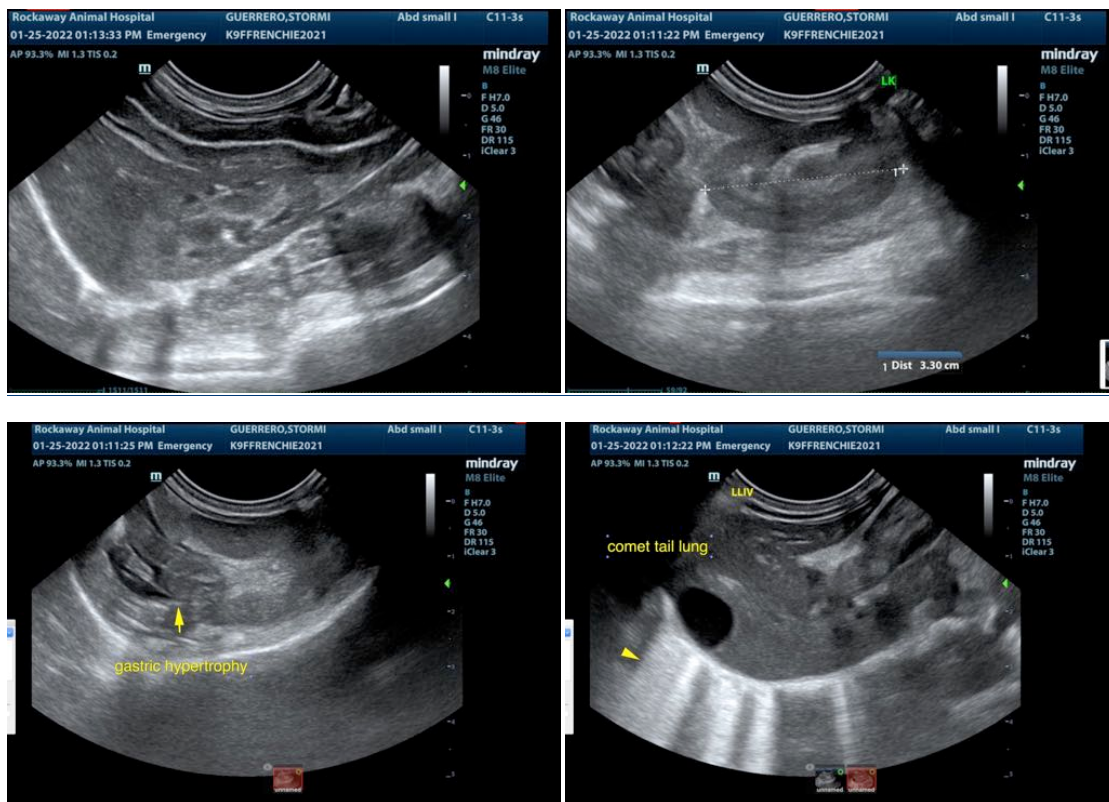
Dr. Maniar

**INVOICE**

95487

**DATE**

1/25/22





#### PATIENT

Stormi Guerrero

The information and recommendations provided are based on the images presented by the referring veterinarian/sonographer. No evaluation can be communicated regarding pathology that was not visible in the image/video clips provided.

#### SPECIES

Canine

Thank you for this referral. If the clinical or image interpretation does not parallel your findings or if I can be of any further assistance please contact me.

#### BREED

French Bulldog

Eric Lindquist, DMV, DABVP, Cert. IVUSS, CEO of SonoPath.com  
info@SonoPath.com

#### SEX

Female

#### AGE

7 weeks

#### WEIGHT

2 lbs

#### INTERPRETED BY

Eric Lindquist, DMV  
DABVP, Cert. IVUSS

#### IMAGING PERFORMED BY

Jenn

#### HOSPITAL NAME

Rockaway AH

#### REFERRING VET

Dr. Maniar

#### INVOICE

95487

#### DATE

1/25/22