



**PATIENT PRESENTING CLINICAL SIGNS**

Peanut Folger History: recheck liver doing well at home, increased ALT 470

**SPECIES ULTRASONOGRAPHIC EXAMINATION OF THE ABDOMEN**

Canine

**Urinary System**

**BREED**

Setter Mix

The **urinary bladder**, trigone, and pelvic urethra presented normal thicknesses and normal tone. The ureters were not visible which is normal. No uroliths or sediment were visualized and anechoic urine was present. No evidence of inflammatory or neoplastic changes was noted. Ureteral papillae were normal.

**SEX**

Spayed Female

The **kidneys** revealed largely normal size and structure, corticomedullary definition and ratio (cortex 1/3 of medulla) were essentially maintained with some age-related loss of curvilinear patterns regarding the capsule and C/M junction. The cortices presented largely uniform texture with some increased echogenicity expected for this age patient. Medullary structure differed distinctly from that of the cortex and no evidence of pelvic dilation was present. The right kidney measured 5.0 cm.

**AGE**

12 years

**WEIGHT**

66.5 lbs

**Adrenal Glands**

The right adrenal gland was slightly enlarged, nodular and mildly heterogenous. The right adrenal gland measured 3.42 x 2.09 cm at the cranial pole and 1.13 cm at the caudal pole. The left adrenal gland comprised mass that measured 2.5 x 2.0 cm and was rounded and expansive. The left adrenal gland impinged upon the left renal artery. Capsular expansion was noted without capsular escape or vascular invasion.

**INTERPRETED BY**

Eric Lindquist, DMV  
DABVP, Cert. IVUSS

**IMAGING PERFORMED BY**

Jenn

**Spleen**

The **spleen** was largely smooth with subtle heterogeneous parenchymal changes while maintaining normal echogenic relationship to the liver and kidney. These changes are consistent with normal age-related alteration. The capsule was smooth without noticeable impingement from within the spleen or from pathology in the adjacent abdomen. The splenic vasculature demonstrated normal volume without signs of congestion or significant contraction. No evidence of active acute or chronic inflammatory, neoplastic, or infarctual changes was noted.

**HOSPITAL NAME**

Rockaway AH

**REFERRING VET**

Dr. Ascot

**Liver**

The **liver** images from right and left intercostal as well as subcostal views revealed subjectively normal liver size, contour, and structure. Some age-related parenchymal remodeling was noted but likely not clinically significant at this time. Vascular and biliary tracts were of normal volume and no evidence of congestion was noted. The gallbladder presented some dependent debris with essentially normal contour. The cystic and common bile ducts were normal. No overt evidence of active inflammatory, infiltrative or regenerative pathology was noted but should be paired with current or past LE elevations regarding any clinical significance to this presentation. The hepatic lymph nodes were unremarkable.

**INVOICE**

95486

**DATE**

1/25/22



**PATIENT**

**Gastrointestinal**

Peanut Folger

Minor fluid accumulation was noted in the **stomach**. The small intestine and colon were unremarkable.

**SPECIES**

**Pancreas**

Canine

The base and limbs of the **pancreas** were observed to be largely isoechoic to surrounding omental fat. Pancreatic duct and capsular contour were acceptably normal and parenchyma respected normal curvilinear patterns. No overt evidence of active inflammatory or neoplastic disease was noted.

**BREED**

Setter Mix

**ULTRASONOGRAPHIC FINDINGS**

**SEX**

Left adrenal mass. Differentials include non-functional adenoma, minor potential for adenocarcinoma and pheochromocytoma.

Spayed Female

Right adrenal nodule. Nodular hyperplasia.

**AGE**

Non-specific inflammatory hepatopathy.

12 years

**INTERPRETATION OF THE FINDINGS & FURTHER RECOMMENDATIONS**

**WEIGHT**

Serial blood pressure measurements and urine catecholamine are warranted. If the patient appears Cushingoid then work-up for adrenal dependent Cushing's is indicated. If hypertension is an issue urine catecholamine is indicated. The adrenal glands should be reimaged in approximately 1 month. If any progression occurs then left adrenalectomy is indicated.

66.5 lbs

**INTERPRETED BY**

Eric Lindquist, DMV  
DABVP, Cert. IVUSS

**IMAGING PERFORMED BY**

Jenn

**HOSPITAL NAME**

Rockaway AH

**REFERRING VET**

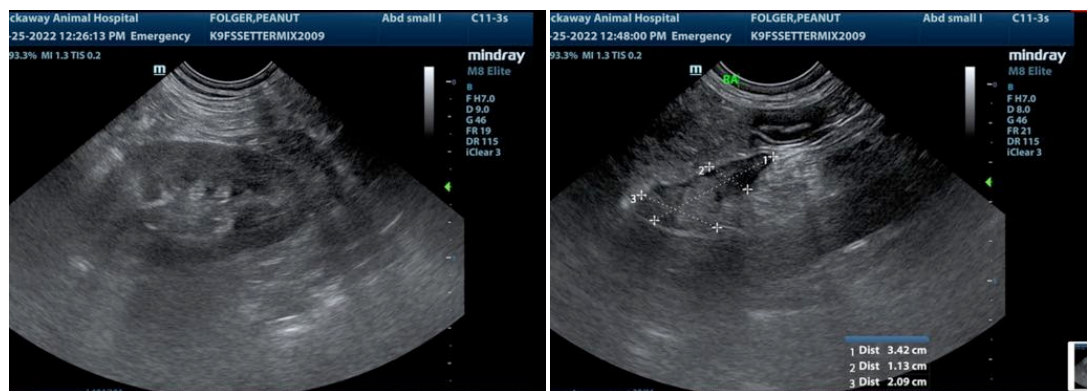
Dr. Ascot

**INVOICE**

95486

**DATE**

1/25/22





**PATIENT**

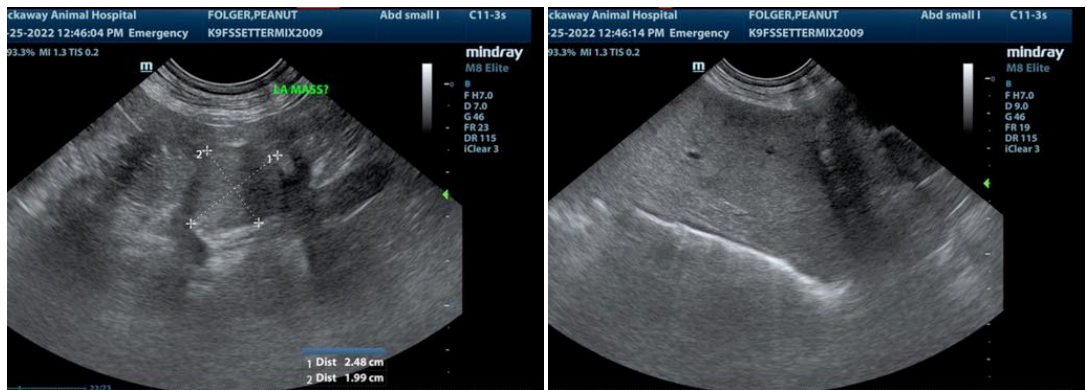
Peanut Folger

**SPECIES**

Canine

**BREED**

Setter Mix



**SEX**

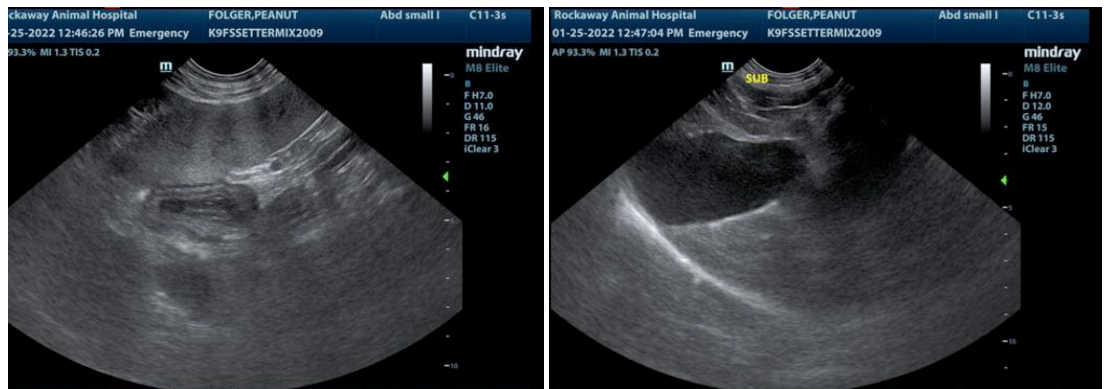
Spayed Female

**AGE**

12 years

**WEIGHT**

66.5 lbs



**INTERPRETED BY**

Eric Lindquist, DMV  
DABVP, Cert. IVUSS

**IMAGING PERFORMED BY**

Jenn

**HOSPITAL NAME**

Rockaway AH

**REFERRING VET**

Dr. Ascot

**INVOICE**

95486

**DATE**

1/25/22

The information and recommendations provided are based on the images presented by the referring veterinarian/sonographer. No evaluation can be communicated regarding pathology that was not visible in the image/video clips provided.

Thank you for this referral. If the clinical or image interpretation does not parallel your findings or if I can be of any further assistance please contact me.

Eric Lindquist, DMV, DABVP, Cert. IVUSS, CEO of SonoPath.com  
info@SonoPath.com