

PATIENT

Daisy Davenport

PRESENTING CLINICAL SIGNS

SPECIES

Canine

ALT increasing despite being on Denamarin
Abnormal PE/Chem/CBC/JA Results: ALT 276 on 2/2019, then Feb2021: TP 10.4, ALB 5.6 GLOB 4.8 ALB/GLOB 1.2 ALT 372, then ALT 349 in March 2021, then ALT 238 after Denamarin treatment then ALT dropped to 206 and now back up to 333. AUS to check liver due to liver ALT fluctuations despite being on Denamarin

BREED

Poodle X

ULTRASONOGRAPHIC EXAMINATION OF THE ABDOMEN

Urinary System

The **urinary bladder**, trigone, and pelvic urethra presented normal thicknesses and normal tone. The ureters were not visible which is normal. No uroliths or sediment were visualized and anechoic urine was present. No evidence of inflammatory or neoplastic changes were noted. Ureteral papillae were normal. The pelvic urethra was imaged 2.0 cm beyond the cystourethral junction.

SEX

Spayed Female

AGE

6 Years

The **kidneys** revealed normal size and structure, corticomedullary definition and ratio for this age. The cortices presented largely uniform texture with normal echogenic relationship to liver and spleen. Medullary structure differed distinctly from the cortex and no evidence of pelvic dilation was present. The capsules were acceptably uniform without significant irregularities. The right kidney measured 3.94 cm. The left kidney measured 3.90 cm.

WEIGHT

14 Pounds

Adrenal Glands

Both **adrenal glands** were visualized and recognized as having normal shape, size, position and echogenicity for this breed. The phrenic vasculature, glandular echogenicity and detail were unremarkable. Capsule, cortex, and medullary definition were normal for this age patient. The right adrenal gland measured 0.68 cm. The left adrenal gland measured 0.50 cm.

INTERPRETED BY

Eric Lindquist, DMV
DABVP. Cert. IVUS

Spleen

The **spleen** presented a smooth homogeneous parenchyma hyperechoic to liver and renal cortical parenchyma. The capsule was smooth without noticeable expansion or deviation from within the spleen or adjacent pathology. The splenic vasculature demonstrated normal volume without signs of congestion or thrombosis. No sonographic evidence of acute or chronic inflammatory, neoplastic, or infarctual changes were noted.

IMAGING BY

Loetitia Saint-Jacques,
LVT

HOSPITAL NAME

North Hills VC

Liver

The **liver** was subnormal in size and measured approximately 2.4 cm in width, structurally unremarkable with uniform parenchyma. The gallbladder was unremarkable. Portal vein/vena cava ratio appeared to be 1:1 at 6.0 mm each. Branching of the portal vein appeared to be normal.

REFERRING VET

Dr. David Bagget

Gastrointestinal

Some retention of ingesta was noted in the **stomach**. The small intestine and colon were unremarkable.

Pancreas

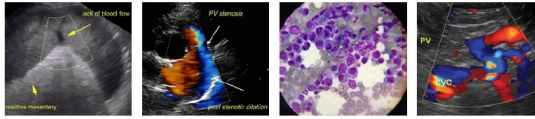
INVOICE

35080

The base and limbs of the **pancreas** were observed to be largely isoechoic to surrounding omental fat. Pancreatic duct and capsular contour were acceptably normal and parenchyma

DATE

1/25/22e



PATIENT

Daisy Davenport respected normal curvilinear patterns. No overt evidence of active inflammatory or neoplastic disease was noted.

SPECIES *Other*

Canine The uterine stump was uniform at 0.3 cm.

ULTRASONOGRAPHIC FINDINGS

BREED

- Mild microhepatica – Inflammatory hepatopathy, possible underlying portal hypoplasia.

Poodle X

INTERPRETATION OF THE FINDINGS & FURTHER RECOMMENDATIONS

SEX

Bile acid profile indicated. However, no evidence of intrahepatic or extrahepatic shunting. FNA of the liver could be considered for further definition.

Spayed Female

AGE

6 Years

WEIGHT

14 Pounds

INTERPRETED BY

Eric Lindquist, DMV
DABVP. Cert. IVUS

IMAGING BY

Loetitia Saint-Jacques,
LVT

HOSPITAL NAME

North Hills VC

REFERRING VET

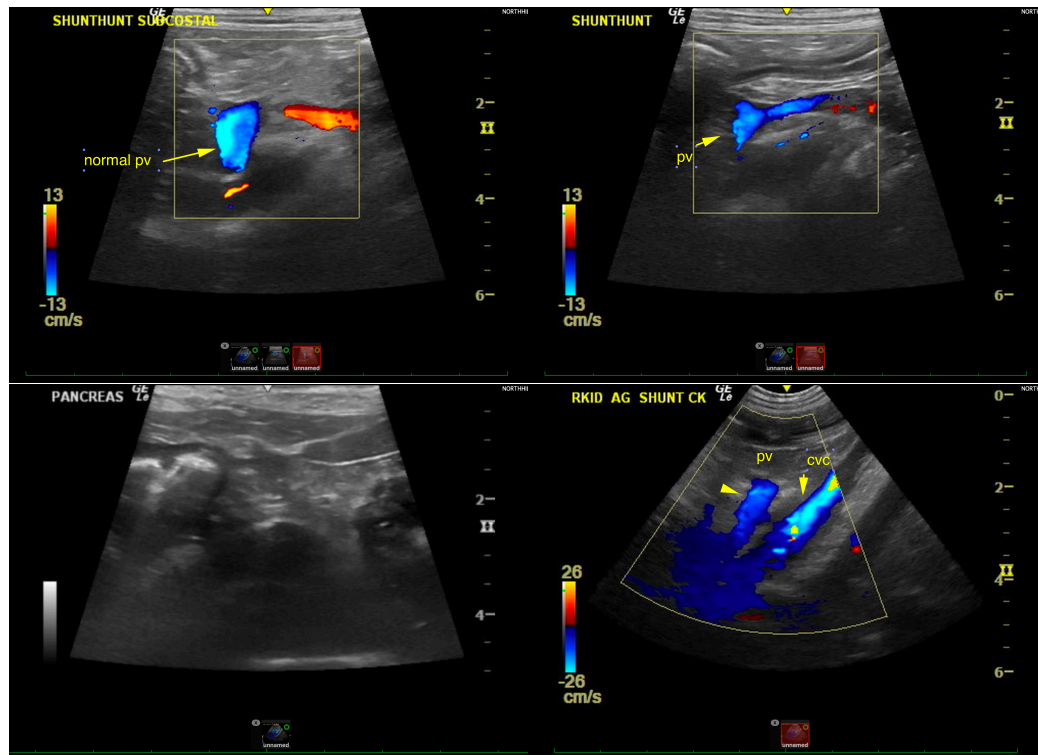
Dr. David Bagget

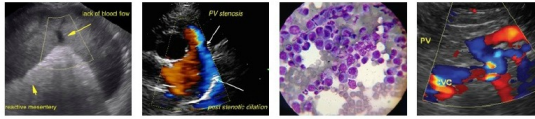
INVOICE

35080

DATE

1/25/22e





PATIENT

Daisy Davenport

SPECIES

Canine

BREED

Poodle X

SEX

Spayed Female

AGE

6 Years

WEIGHT

14 Pounds

INTERPRETED BY

Eric Lindquist, DMV
DABVP, Cert. IVUSS

IMAGING BY

Loetitia Saint-Jacques,
LVT

HOSPITAL NAME

North Hills VC

REFERRING VET

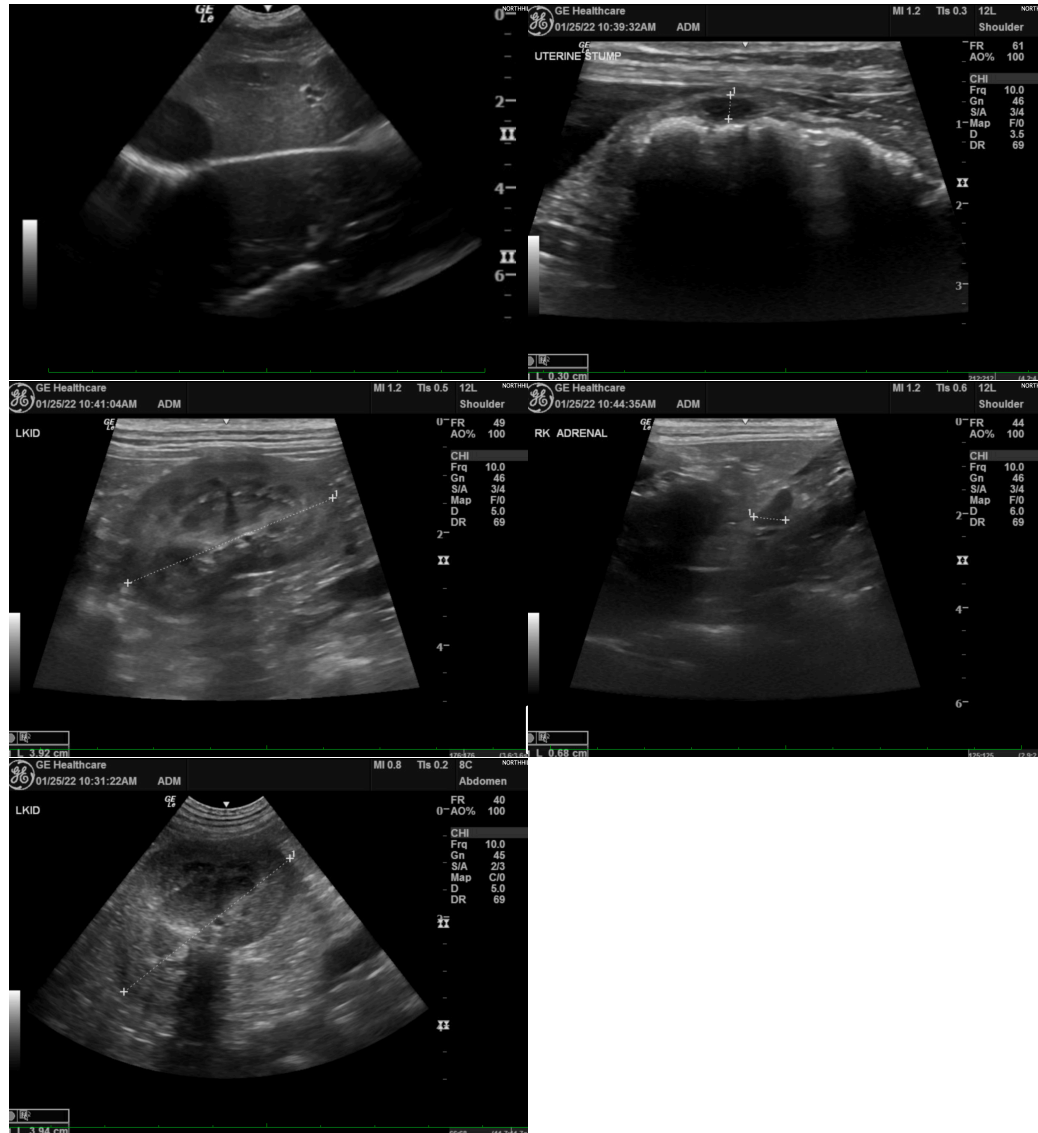
Dr. David Bagget

INVOICE

35080

DATE

1/25/22e



The information and recommendations provided are based on the images presented by the referring veterinarian/sonographer. No evaluation can be communicated regarding pathology that was not visible in the image/video clips provided.

Thank you for this referral. If the clinical or image interpretation does not parallel your findings or if I can be of any further assistance please contact me.

Eric Lindquist, DMV, DABVP, Cert. IVUSS, CEO of SonoPath.com
info@SonoPath.com