



## PATIENT

Snuggles Garulle

## PRESENTING CLINICAL SIGNS

History: Grade 2/6 murmur, elevated liver value  
 Abnormal PE/Chem/CBC/UA Results: Alk Phos 785. BP 180/105(122), 180/104(124), 178/96(112)

## SPECIES

Canine

## BREED

Multipoo

## SEX

Spayed female

## AGE

13 years

## WEIGHT

28 lbs

## ULTRASONOGRAPHIC EXAMINATION OF THE HEART

The echocardiogram in this patient demonstrated normal **left atrial** size based on 3 different LA measurement methods. Chamber volumes and echogenicity were normal. The cranial and caudal **mitral** valve leaflets presented vegetative thickening consistent with endocardiosis. Doppler indicated measurable insufficiency. The **left ventricle** presented thicknesses with linear contour and was not dilated nor restricted. The **myocardium** presented normal echogenicity without subjective evidence of significant fibrotic or ischemic disease. **Contractility** of the ventricular walls was adequate and in normal range for this patient evidenced by the fractional shortening measurement and subjective evaluation of the different regions of the myocardium. The **left ventricular outflow** tract demonstrated normal laminar flow and subjective structural integrity. The **right atrium** and auricle revealed normal size, structure and content. No evidence of masses was noted or chamber overload. **Tricuspid** valvular assessment demonstrated adequate linear morphology. The **right ventricle** was of normal size (1/3 diameter of LV), chordae structure, myocardial echogenicity and thickness. **Pulmonic** tract assessment revealed normal valve structure, laminar flow, and diameter (approx. 1:1 pa/ao ratio). No visible **pericardial** or free pleura fluid was noted. No echographically detectable evidence of infiltrative disease was visible. The cranial **mediastinum and pericardial regions** were free of masses in the visible window.

## INTERPRETED BY

Eric Lindquist, DMV  
 DABVP, Cert. IVUSS

## IMAGING PERFORMED BY

JK

## HOSPITAL NAME

Hamburg VC

## REFERRING VET

Dr. Martens

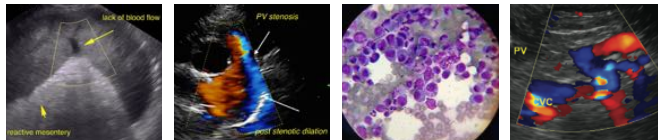
CANINE CARDIAC PARAMETERS	MR VMAX (m/s)	TR VMAX (m/s)	LA/AO (Boon method)	LA/AO (Heart Base;)	FS (%)	EF (%)	EPSS (cm)
NORMAL PARAMETER	4.5-5.5	<2.7	1.3	<1.6	28-40	40-100	<0.6
PATIENT		2.0	1.0	1.4			0.2
CANINE CARDIAC PARAMETERS	HR (BPM)	AV VMAX (m/s)	PV MAX (m/s)	BODY WEIGHT	LA 2D short axis Base view (cm)	LVIDd Avg; 2D and m-mode short axis (cm)	LVIDs Avg; 2D and m-mode short axis (cm)
NORMAL PARAMETER	50-100	0.7-1.7	0.7-1.6	BELOW	BELOW	BELOW	BELOW
PATIENT		1.33	0.7	28 lbs	3.0		

## INVOICE

42302

## DATE

1/24/23



**PATIENT** **ULTRASONOGRAPHIC EXAMINATION OF THE ABDOMEN**

Snuggles Garulle

**Urinary System**

**SPECIES**

Canine

The **urinary bladder**, trigone, and pelvic urethra presented normal thicknesses and normal tone. The ureters were not visible which is normal. No uroliths or sediment were visualized and anechoic urine was present. No evidence of inflammatory or neoplastic changes was noted. Ureteral papillae were normal.

**BREED**

Multipoo

The **kidneys** revealed largely normal size and structure, corticomedullary definition and ratio (cortex 1/3 of medulla) were essentially maintained with some age-related loss of curvilinear patterns regarding the capsule and C/M junction. The cortices presented largely uniform texture with some increased echogenicity expected for his age patient. Medullary structure differed distinctly from that of the cortex and no evidence of pelvic dilation was present. Slight areas of mineralization were noted. The left kidney measured 5.2 cm. The right kidney measured 4.05 cm.

**SEX**

Spayed female

**AGE**

13 years

**Adrenal Glands**

Both **adrenal glands** were visualized and recognized as having normal shape, size, position and echogenicity for this breed. The phrenic vasculature, glandular echogenicity and detail were unremarkable. Capsule, cortex, and medullary definition were normal for this age patient. The right adrenal gland measured 1.8 x 0.4 cm. The left adrenal gland measured 2.0 x 0.5 cm with slight cortical cysts noted.

**WEIGHT**

28 lbs

**INTERPRETED BY**

Eric Lindquist, DMV  
DABVP, Cert. IVUSS

**Spleen**

The **spleen** revealed hyperechoic, lipogranulomatous nodule measuring up to 0.4 cm.

**IMAGING PERFORMED BY**

JK

**Liver**

The **liver** was uniformly swollen with minor, excessive gallbladder debris and over distension with dependent and suspended bile without evidence of overt mucocele formation. However, excessive sludge was present. The liver presented coarse architecture with mildly increased portal markings and subtle, mixed echogenic changes. This is consistent with vacuolar hepatopathy and some level of remodeling and history of inflammatory component. Hypoechoic, nodular changes were noted in the liver.

**HOSPITAL NAME**

Hamburg VC

**REFERRING VET**

Dr. Martens

**Gastrointestinal**

Examination of the **gastrointestinal tract** revealed a stomach and intestine free of stasis, of normal wall thickness, acceptable curvilinear mural detail, and peristaltic activity. Small and large intestine demonstrated normal luminal chyme and stool consistency respectively. No obstructive or overt infiltrative disease was noted. No associated abnormal lymphatic activity was noted.

**INVOICE**

42302

**DATE**

1/24/23



## PATIENT

Snuggles Garulle

## SPECIES

Canine

## BREED

Multipoo

## SEX

Spayed female

## AGE

13 years

## WEIGHT

28 lbs

## INTERPRETED BY

Eric Lindquist, DMV  
DABVP, Cert. IVUSS

## IMAGING PERFORMED BY

JK

## HOSPITAL NAME

Hamburg VC

## REFERRING VET

Dr. Martens

## INVOICE

42302

## DATE

1/24/23

## Pancreas

The base and limbs of the **pancreas** were observed to be largely isoechoic to surrounding omental fat. Pancreatic duct and capsular contour were acceptably normal and parenchyma respected normal curvilinear patterns. No overt evidence of active inflammatory or neoplastic disease was noted.

## ULTRASONOGRAPHIC FINDINGS

Nodular hyperplasia, vacuolar hepatopathy liver pattern.

Moderate degenerative renal changes.

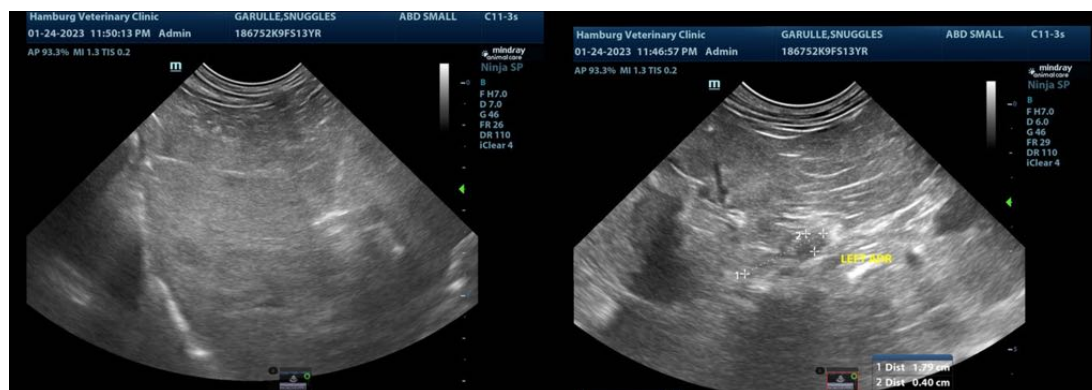
Otherwise, unremarkable abdomen.

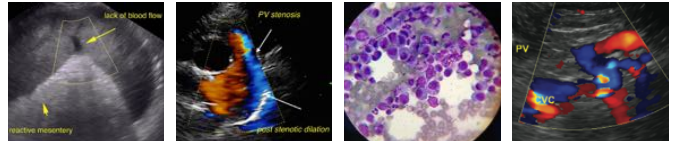
Stage B1 valvular disease.

## INTERPRETATION OF THE FINDINGS & FURTHER RECOMMENDATIONS

FNA of the liver can be considered for further definition.

The heart is stable without clinical disease. No overt contraindication for anesthesia of brief to moderate duration. I suggest Torbutrol premed, Propofol induction, Isoflor maintenance or similar protocol if anesthesia is desired. Blood pressure recommended if not already performed and target white coat negative systolic pressure of < 160 mmHg. If higher than this ACE-inhibitor is suggested to reach this level. Recheck echocardiogram is recommended in 6 months, earlier if murmur grade increases or clinical signs initiate.





**PATIENT**

Snuggles Garulle

**SPECIES**

Canine

**BREED**

Multipoo

**SEX**

Spayed female

**AGE**

13 years

**WEIGHT**

28 lbs

**INTERPRETED BY**

Eric Lindquist, DMV  
DABVP, Cert. IVUSS

**IMAGING PERFORMED BY**

JK

**HOSPITAL NAME**

Hamburg VC

**REFERRING VET**

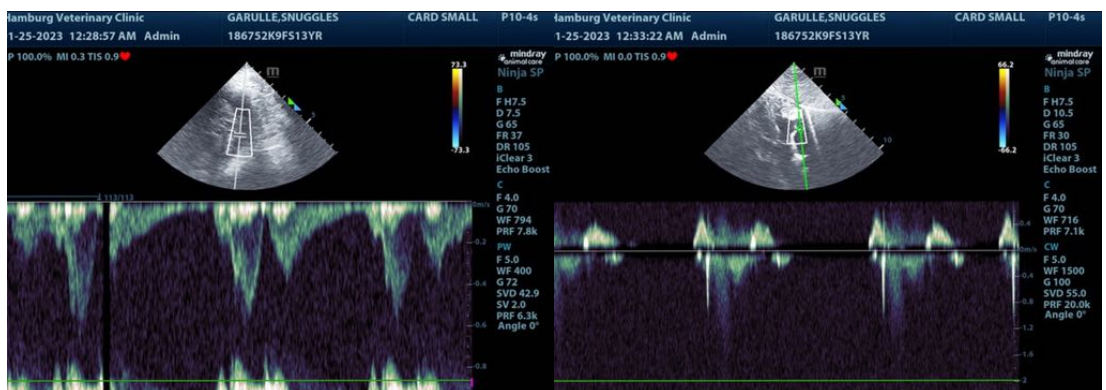
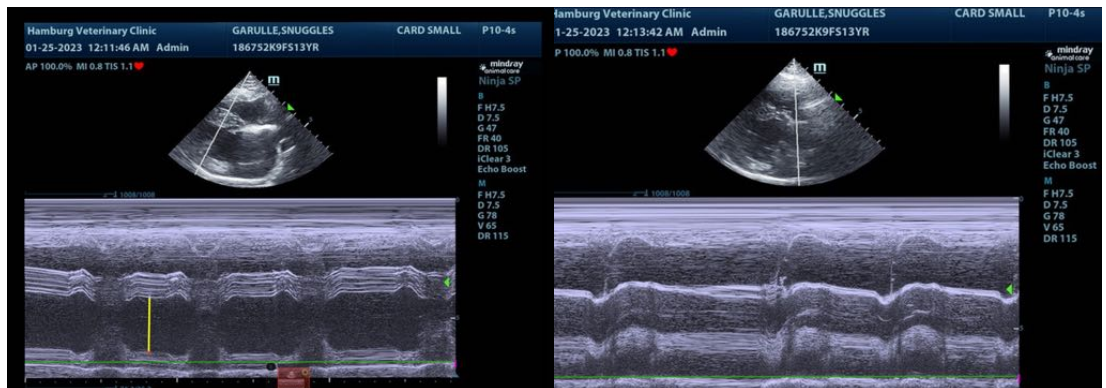
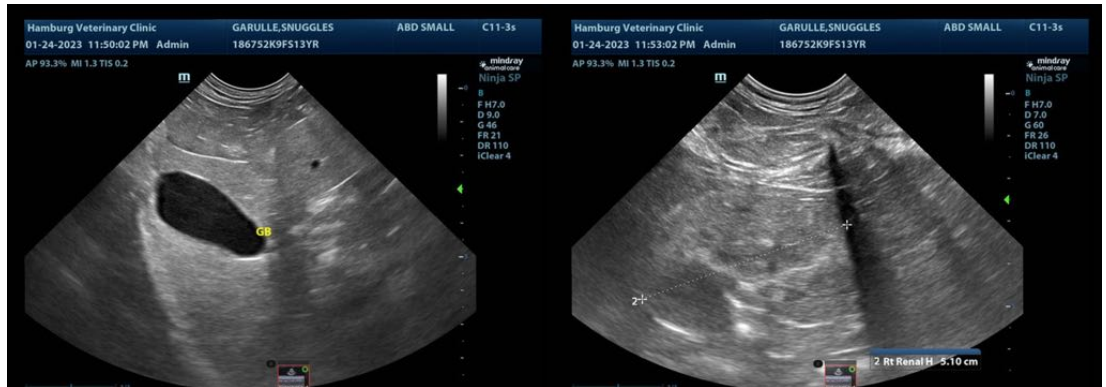
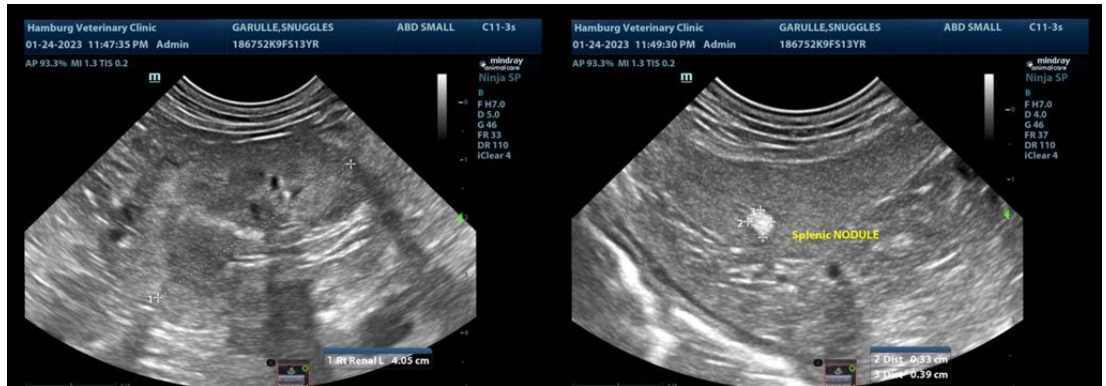
Dr. Martens

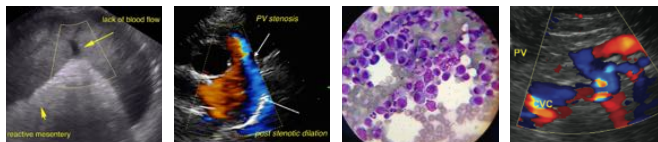
**INVOICE**

42302

**DATE**

1/24/23





**PATIENT**

Snuggles Garulle

**SPECIES**

Canine

**BREED**

Multipoo

**SEX**

Spayed female

**AGE**

13 years

**WEIGHT**

28 lbs

**INTERPRETED BY**

Eric Lindquist, DMV  
DABVP, Cert. IVUSS

**IMAGING  
PERFORMED BY**

JK

**HOSPITAL NAME**

Hamburg VC

**REFERRING VET**

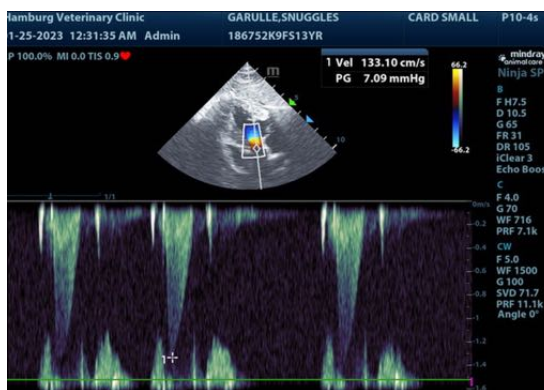
Dr. Martens

**INVOICE**

42302

**DATE**

1/24/23



The information and recommendations provided are based on the images presented by the referring veterinarian/sonographer. No evaluation can be communicated regarding pathology that was not visible in the image/video clips provided.

Thank you for this referral. If the clinical or image interpretation does not parallel your findings or if I can be of any further assistance please contact me.

Eric Lindquist, DMV, DABVP, Cert. IVUSS, CEO of SonoPath.com  
info@SonoPath.com