

**PATIENT**

Sophie Berna

SPECIES

Canine

BREED

Boxer

SEX

Spayed Female

AGE

6 years

WEIGHT

61 Pounds

INTERPRETED BYEric Lindquist, DMV
DABVP, Cert. IVUSS**IMAGING PERFORMED BY**

Kim Liedberg

HOSPITAL NAME

SVS Imaging TX

REFERRING VETDr. Klein, Pet Care in
Motion**INVOICE**

95463

DATE

1/24/22

PRESENTING CLINICAL SIGNS

Bradycardia with occasional pulse deficit. No noted heart murmur or coughing. This is a heart check for abnormalities.

ECG

Underlying rhythm is a sinus arrhythmia at average heart rate of 70-80 bpm. Respiratory sinus arrhythmia possible (due to airway resistance and vagal tone), given the fact that this is a boxer dog. In the last row there's one escape beat visible.

There's some hypovoltage noted, also a relatively deep S-wave (provided the recording resembles a second lead). Differentials for hypovoltage are hypothyroidism, obesity, insufficient electrical contact. The deep S-wave in lead II can be indicative for right heart enlargement.

In order to prove vagally induced sinus arrhythmia, an atropine test can be performed (0,03-0,04 mg/kg Atropine IM or IV - arrhythmia has to disappear within 5-15 min).

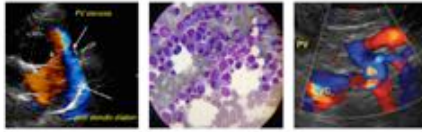
If no associated clinical signs, no therapy required.

If clinical signs are noted (weakness, syncope), a Holter-EKG is necessary, because this rhythm strip would not provide sufficient explanation.

Peter Modler DVM, Dipl.-Tzt. | SonoPath

ULTRASONOGRAPHIC EXAMINATION OF THE HEART

The echocardiogram in this patient demonstrated normal **left atrial** size based on 3 separate methods of LA evaluation. The cranial and caudal **mitral** valve leaflets presented normal linear structure, extension in systole, and union in diastole with normal kinesis. The **left ventricle** presented thicknesses with linear contour and was not dilated nor restricted. The **myocardium** presented normal echogenicity without subjective evidence of significant fibrotic or ischemic disease. **Contractility** of the ventricular walls was adequate and in normal range for this patient evidenced by the fractional shortening measurement and subjective evaluation of the different regions of the myocardium. The **left ventricular outflow** tract demonstrated normal laminar flow and subjective structural integrity. The **right atrium** was mildly enlarged with a 1.5:1 ratio with the left atrium. The atrial septum was unclear. A space of approximately 1.3 cm was noted. This may represent an atrial septal defect. However, acoustic fall out is also a potential. **Tricuspid** valvular assessment demonstrated adequate linear morphology and kinesis. The **right ventricle** was of normal size (1/3 diameter of LV), chordae structure, myocardial echogenicity and thickness. **Pulmonary outflow** tract assessment revealed normal valve structure, laminar flow, and diameter (approx. 1:1 pa/ao ratio). No visible **pericardial** or free pleura fluid was noted. The cranial **mediastinum** and **pericardial** and **extra-cardiac** regions were free of masses in the visible window.



PATIENT

Sophie Berna

SPECIES

Canine

BREED

Boxer

SEX

Spayed Female

AGE

6 years

WEIGHT

61 Pounds

INTERPRETED BY

Eric Lindquist, DMV
DABVP, Cert. IVUSS

IMAGING PERFORMED BY

Kim Liedberg

HOSPITAL NAME

SVS Imaging TX

REFERRING VET

Dr. Klein, Pet Care in
Motion

INVOICE

95463

DATE

1/24/22

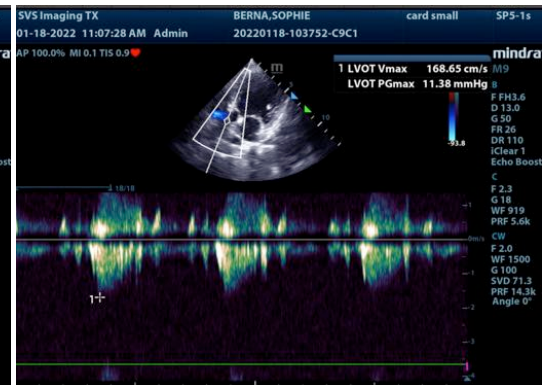
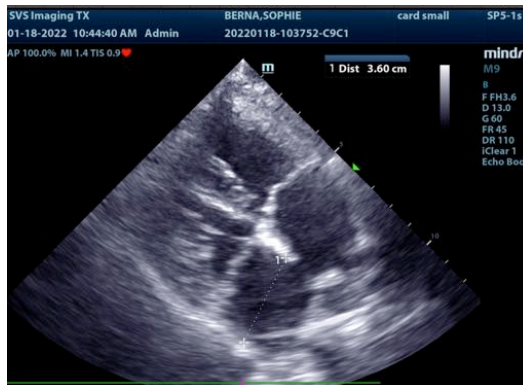
CANINE CARDIAC PARAMETERS	MR VMAX (m/s)	TR VMAX (m/s)	LA/AO (Boon method)	LA/AO (Heart Base; Swe)	FS (%)	EF (%)	EPSS (cm)
NORMAL PARAMETER	4.5-5.5	<2.7	1.3	<1.6	28-40	40-100	<0.6
PATIENT			1.38	1.5	30	80	0.21
CANINE CARDIAC PARAMETERS	HR (BPM)	AV VMAX (m/s)	PV MAX (m/s)	BODY WEIGHT	LA (cm)	LVIDd (cm)	LVIDs (cm)
NORMAL PARAMETER	50-100	0.7-1.7	0.7-1.6				
PATIENT		1.68	1.42	61 lbs	3.6	2.4	

ULTRASONOGRAPHIC FINDINGS

Slightly enlarged right atrium. Possible small atrial septal defect; however, further imaging would be needed to confirm.

INTERPRETATION OF THE FINDINGS & FURTHER RECOMMENDATIONS

Further imaging of the atrial septum with color flow and spectral Doppler is indicated (SDEP 1, 4 chamber long axis). No functional issues are noted with the heart.



INVOICE

95463

DATE

1/24/22

IMAGING PERFORMED BY

SVS Mobile Imaging 262-366-5970
fredgromalak@gmail.com



Clinical Sonography & Telectology

EDUCATIONAL TELECONSULTATION SERVICES™

1-800-838-4268 info@sonopath.com SonoPath.com

PATIENT

Sophie Berna

SPECIES

Canine

BREED

Boxer

SEX

Spayed Female

AGE

6 years

WEIGHT

61 Pounds

INTERPRETED BY

Eric Lindquist, DMV
DABVP, Cert. IVUSS

**IMAGING
PERFORMED BY**

Kim Liedberg

HOSPITAL NAME

SVS Imaging TX

REFERRING VET

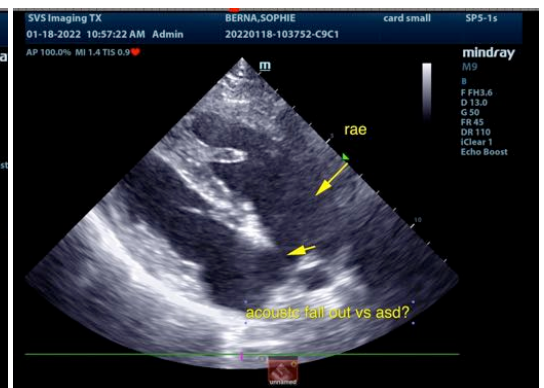
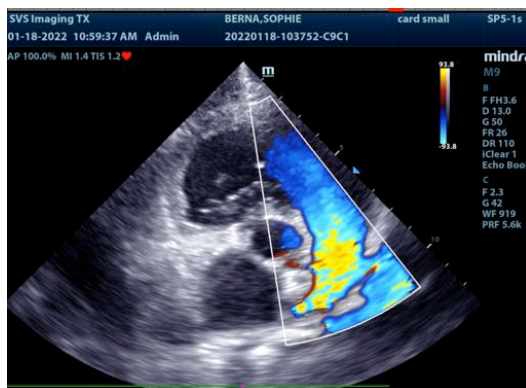
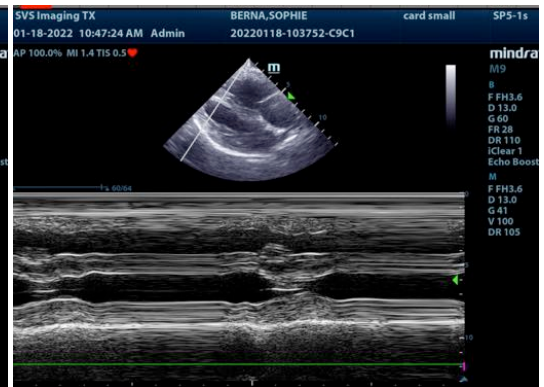
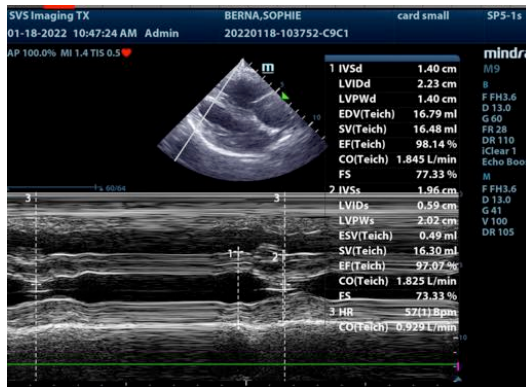
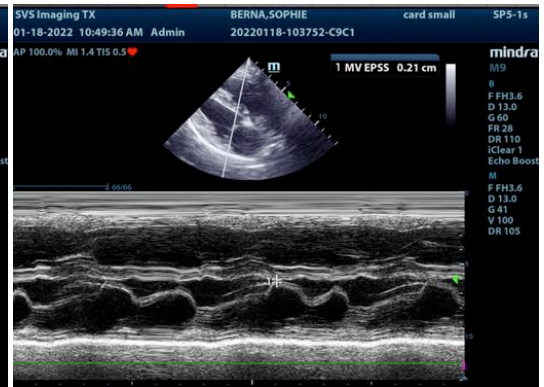
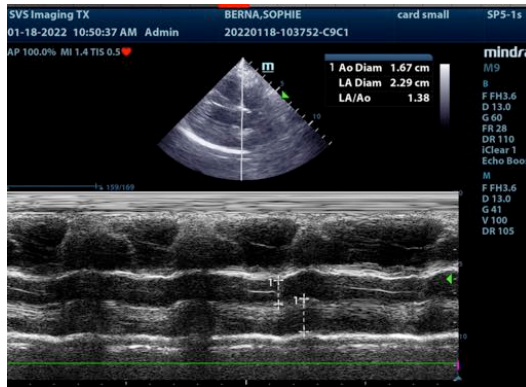
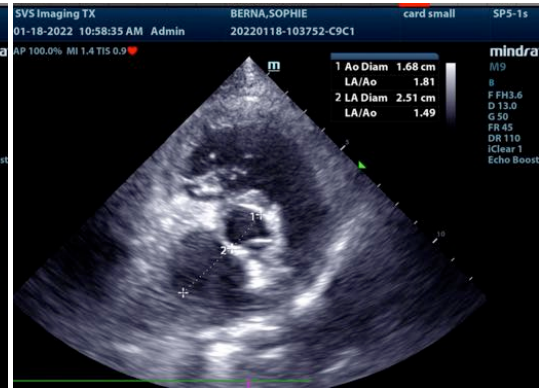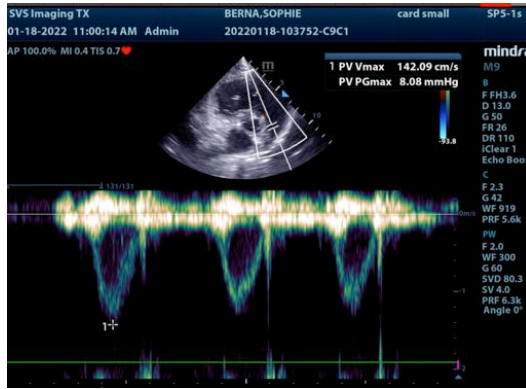
Dr. Klein, Pet Care in
Motion

INVOICE

95463

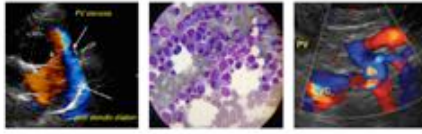
DATE

1/24/22



IMAGING PERFORMED BY

SVS Mobile Imaging 262-366-5970
fredgromalak@gmail.com



Clinical Sonography & Telectology

EDUCATIONAL TELECONSULTATION SERVICES™

1-800-838-4268 info@sonopath.com SonoPath.com

PATIENT

ADDENDUM 1/24/22

Sophie Berna

On further imaging a small atrial septal defect was noted with left to right flow. However, this is not of clinical significance and not likely related to the clinical signs. There is no evidence of right-sided heart failure present. I recommend Holter monitor in this patient with treatment based on Holter monitor results.

SPECIES

Canine

BREED

Boxer

SEX

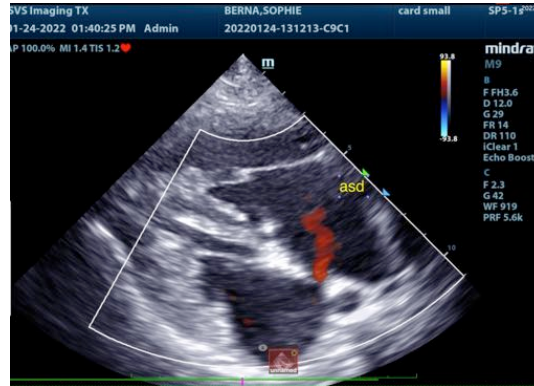
Spayed Female

AGE

6 years

WEIGHT

61 Pounds



The information and recommendations provided are based on the images presented by the referring veterinarian. No evaluation can be communicated regarding pathology that was not visible in the image/video clips provided.

Thank you for this referral. If the clinical or image interpretation does not parallel your findings or if I can be of any further assistance please contact me.

INTERPRETED BY

Eric Lindquist, DMV
DABVP, Cert. IVUSS

Eric Lindquist, DMV, DABVP, Cert. IVUSS, CEO of SonoPath.com
Eric.Lindquist@SonoPath.com

IMAGING PERFORMED BY

Kim Liedberg

HOSPITAL NAME

SVS Imaging TX

REFERRING VET

Dr. Klein, Pet Care in
Motion

INVOICE

95463

DATE

1/24/22