



PATIENT

Rufus Stafford

SPECIES

Mustelidae

BREED

Ferret

SEX

Neutered Male

AGE

6 Years

WEIGHT

1010 Grams

PRESENTING CLINICAL SIGNS

History: Heart murmur, bradycardia. Radiographs revealed generalized cardiomegaly and possible early pulmonary edema.

ULTRASONOGRAPHIC EXAMINATION OF THE HEART

FERRET CARDIAC PARAMETERS	BODY WEIGHT (kg)	HR (BPM)	IVSd (cm)	LVIDd (cm)	LVWd (cm)	FS (%)	EF (%)
NORMAL PARAMETER	-----	150-240	0.3-0.6	1.0-2.1	0.25-0.6	35-67	80-100
PATIENT	--	NM	--	--	--	--	--
FERRET CARDIAC PARAMETERS	LA/AO (Boon)	LA/AO HEART BASE (Sisson)	LA 2D 4-chamber long axis AS to FW (Sisson) (cm)	LVOT VEL. (m/s)	RVOT VEL. (m/s)	IVRT (m/)	
NORMAL PARAMETER	<1.5	0.88-1.79	0.7-1.7	<1.6	<1.3	40-60	
PATIENT	1.7	1.8	--	--	--	NM	
Adapted from June Boon, Veterinary Echocardiography, 1998 Sisson D et al. JVIM 1991; 5: 232, Jacobs et al. Am J Vet Res 1985; 46:1705							

INTERPRETED BY

Eric Lindquist, DMV
DABVP, Cert. IVUSS

IMAGING PERFORMED BY

Shari Reffi, CVT

HOSPITAL NAME

Companion AH

REFERRING VET

Dr. Wolf

INVOICE

13594

DATE

1/24/22

Cardiac Presentation

A rapid echocardiogram was performed in this patient given the precarious presentation. Severe arrhythmia noted in this patient with volume overload of the left atrium and left ventricle. The left ventricular outflow tract was unremarkable. The right atrium and right ventricle were also enlarged. Hepatic veins were not dilated. Generalized contractility was poor, however, likely owing to arrhythmia. Septal and free wall thicknesses were normal to thinning.

ULTRASONOGRAPHIC FINDINGS

- Suspect myocarditis with volume overload and bradycardia

INTERPRETATION OF THE FINDINGS & FURTHER RECOMMENDATIONS

I recommend Lasix, Pimobendan (off-label), EKG and reassessment of the patient once stable. However, given the nature of the arrhythmia, sudden death is a strong concern in this patient. Causes of myocarditis should be evaluated.



PATIENT

Rufus Stafford

SPECIES

Mustelidae

BREED

Ferret

SEX

Neutered Male

AGE

6 Years

WEIGHT

1010 Grams

INTERPRETED BY

Eric Lindquist, DMV
DABVP, Cert. IVUSS

IMAGING PERFORMED BY

Shari Reffi, CVT

HOSPITAL NAME

Companion AH

REFERRING VET

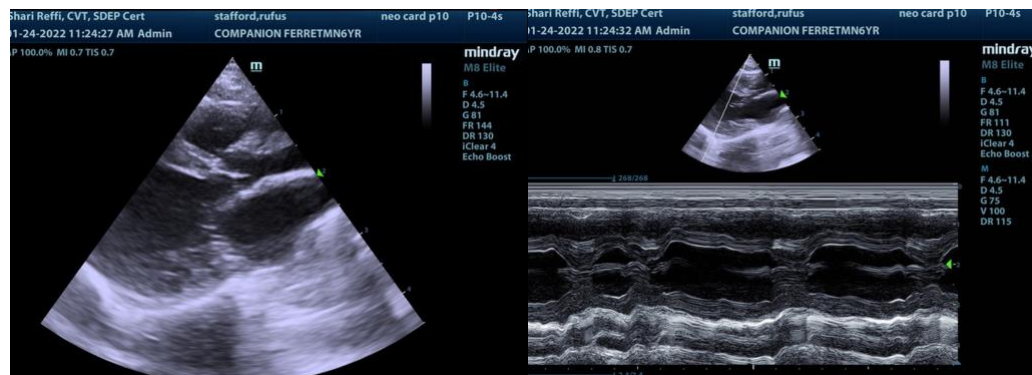
Dr. Wolf

INVOICE

13594

DATE

1/24/22



The information and recommendations provided are based on the images presented by the referring veterinarian. No evaluation can be communicated regarding pathology that was not visible in the image/video clips provided.

Thank you for this referral. If the clinical or image interpretation does not parallel your findings or if I can be of any further assistance please contact me.

Eric Lindquist, DMV, DABVP, Cert. IVUSS, CEO of SonoPath.com
info@SonoPath.com