



PATIENT

Ranger Winawer

SPECIES

Canine

BREED

Mixed Breed

SEX

Neutered Male

AGE

10 Years

WEIGHT

18.1 Lbs.

INTERPRETED BY

Eric Lindquist, DMV
DABVP, Cert. IVUSS

IMAGING PERFORMED BY

Kelly Vazquez

HOSPITAL NAME

New Bridge VP

REFERRING VET

Dr. Glennon

INVOICE

13575

DATE

1/24/22

PRESENTING CLINICAL SIGNS

History: HGE=pancreatitis. Anorexic x 3 days but improving. Current treatments: IVF, Cerenia, Baytril, Sucralfate, and metronidazole. New inguinal bruising noted today.

Abnormal PE/Chem/CBC/UA Results: Elevated lipase, but CBC WNL.

ULTRASONOGRAPHIC EXAMINATION OF THE ABDOMEN

Urinary System

The **urinary bladder**, trigone, and pelvic urethra presented normal thicknesses and normal tone. The ureters were not visible which is normal. No uroliths or sediment were visualized and anechoic urine was present. No evidence of inflammatory or neoplastic changes were noted. Ureteral papillae were normal.

The **kidneys** revealed largely normal size and structure, corticomedullary definition and ratio (cortex 1/3 of medulla) were essentially maintained with some minor age-related loss of curvilinear patterns regarding the capsule and C/M junction. The cortices presented largely uniform texture with some increased echogenicity expected for his age patient. Medullary structure differed distinctly from that of the cortex and no evidence of pelvic dilation was present. The left kidney measured 4.31 cm. The right kidney measured 3.61 cm.

Adrenal Glands

Both **adrenal glands** were visualized and recognized as having normal shape, size, position and echogenicity for this breed. The phrenic vasculature, glandular echogenicity and detail were unremarkable. Capsule, cortex, and medullary definition were normal for this age patient. The left adrenal gland measured 2.04 cm x 0.69 cm at the caudal pole and 0.72 cm at the cranial pole. The right adrenal gland measured 1.52 cm x 0.63 cm at the caudal pole and 0.68 cm at the cranial pole.

Spleen

The **spleen** presented a smooth homogeneous parenchyma hyperechoic to liver and renal cortical parenchyma. The capsule was smooth without noticeable expansion or deviation from within the spleen or adjacent pathology. The splenic vasculature demonstrated normal volume without signs of congestion or thrombosis. No sonographic evidence of acute or chronic inflammatory, neoplastic, or infarctual changes were noted.

Liver

The **liver** images submitted revealed subjectively normal liver size, contour, and structure. Parenchymal echogenicity was naturally coarse and hypoechoic to the spleen. Vascular and biliary tracts were of normal volume with no evidence of congestion. The gallbladder presented acceptably thin walls with primarily anechoic content. The cystic and common bile ducts were normal. No pathological hepatic lymphadenopathy was evident. No overt structural evidence of inflammatory, infiltrative or regenerative pathology was evident.

Gastrointestinal

The upper **gastrointestinal tract** in this patient revealed minor, edematous wall. There was no evidence of foreign bodies. Minor areas of fluctuant fluid accumulation were noted within the lumen with hyperperistalsis. This pattern continued to the ileocecal valve. Soft stool was noted in the colon.



PATIENT

Ranger Winawer

The colon was mildly thickened yet no loss of mural detail present. This presentation is most consistent with gastrointestinal irritation/inflammation without obstruction.

SPECIES

Canine

Pancreas

The **pancreas** revealed hyperechoic changes consistent with remodeling. Ill-defined changes were noted in the pancreas that would suggest pancreatitis.

BREED

Mixed Breed

ULTRASONOGRAPHIC FINDINGS

- Gastroenteritis/Colitis. Enterotoxin should be considered.
- Pancreatitis

SEX

Neutered Male

INTERPRETATION OF THE FINDINGS & FURTHER RECOMMENDATIONS

I recommend IV fluid support, GI protectants and enrofloxacin/metronidazole or enrofloxacin/clindamycin combination to treat for enterotoxins. No evidence of foreign bodies or neoplasia. Enterotoxin, parasitic disease and dietary indiscretion all possible in this patient. Recheck sonogram in 48-72 hours, post therapy to ensure adequate resolution.

AGE

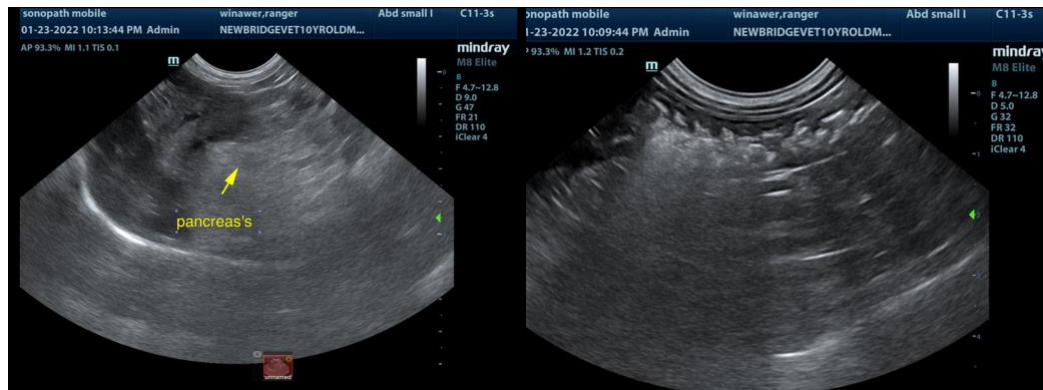
10 Years

WEIGHT

18.1 Lbs.

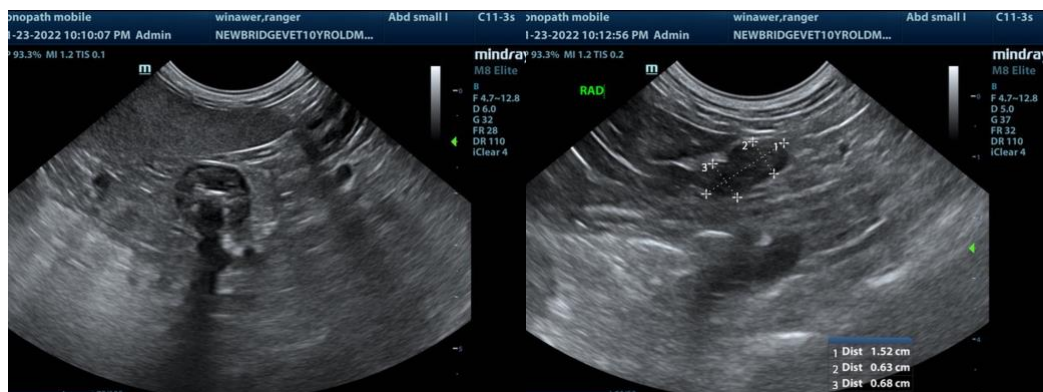
INTERPRETED BY

Eric Lindquist, DMV
DABVP, Cert. IVUSS



IMAGING PERFORMED BY

Kelly Vazquez



HOSPITAL NAME

New Bridge VP

REFERRING VET

Dr. Glennon

INVOICE

13575

DATE

1/24/22



PATIENT

Ranger Winawer

SPECIES

Canine

BREED

Mixed Breed

SEX

Neutered Male

AGE

10 Years

WEIGHT

18.1 Lbs.

INTERPRETED BY

Eric Lindquist, DMV
DABVP, Cert. IVUSS

IMAGING PERFORMED BY

Kelly Vazquez

HOSPITAL NAME

New Bridge VP

REFERRING VET

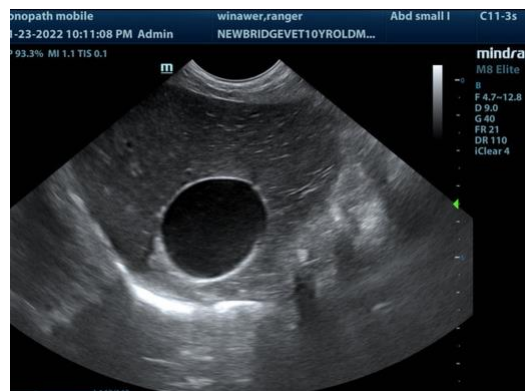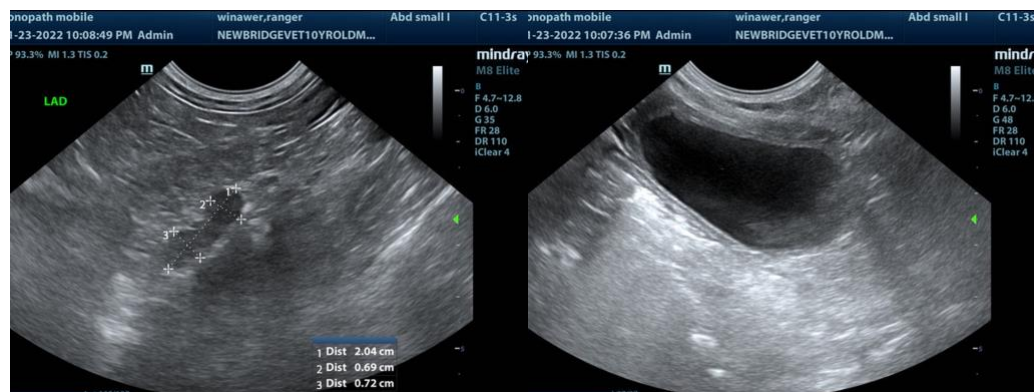
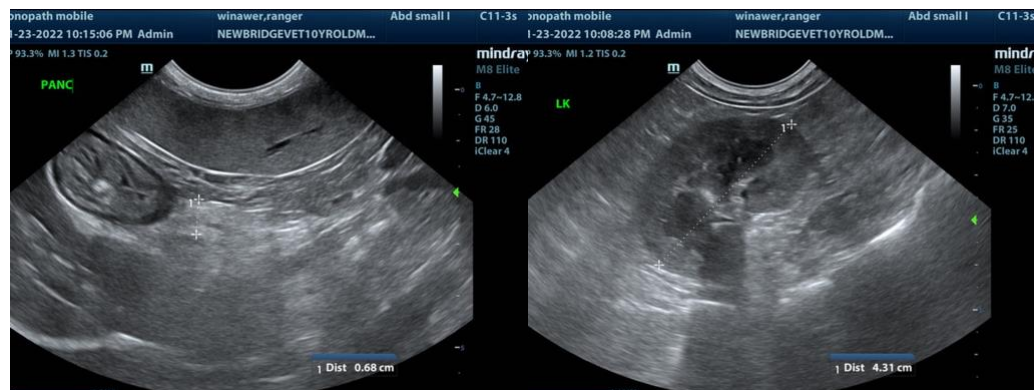
Dr. Glennon

INVOICE

13575

DATE

1/24/22



The information and recommendations provided are based on the images presented by the referring veterinarian. No evaluation can be communicated regarding pathology that was not visible in the image/video clips provided.

Thank you for this referral. If the clinical or image interpretation does not parallel your findings or if I can be of any further assistance please contact me.

Eric Lindquist, DMV, DABVP, Cert. IVUSS, CEO of SonoPath.com
info@SonoPath.com