

## PATIENT

Ollie Gelbert

## SPECIES

Canine

## BREED

Cavalier King Charles

## SEX

Neutered Male

## AGE

8 Years

## WEIGHT

35 Lbs.

## INTERPRETED BY

Eric Lindquist, DMV  
DABVP, Cert. IVUSS

## IMAGING PERFORMED BY

Kelly Vazquez

## HOSPITAL NAME

New Bridge VP

## REFERRING VET

Dr. Glennon

## INVOICE

13596

## DATE

1/24/22

## PRESENTING CLINICAL SIGNS

History: Mass in cervical neck, needs ultrasound and U/S guided FNA for cytology. No current meds; had Convenia injection 10 days ago.

Abnormal PE/Chem/CBC/UA Results: Bloods WNL, CXR NSF.

## LIMITED ULTRASONOGRAPHIC EXAMINATION

A focal hypoechoic nodule (4.0 cm x 3.0 cm) was noted in the left thyroid lobe and could be consistent with an enlarged parathyroid, not likely clinically significant for this particular patient. A mixed echogenic tissue mass was noted. The mass appears to derive from the subcutaneous tissues and has a disorganized fat pattern- granulomatous change or liposarcoma possible. Ultrasound guided FNA performed without complication. The mass appears to be somewhat encapsulated with mixed hypoechoic nodules. CT of the region recommended for possible surgical planning. The thyroid glands do not appear to be involved. A second parathyroid nodule measured 3.0 mm and was slightly prominent in the left thyroid gland.

The right thyroid lobe was uniform, measuring 2.01 cm x 0.27 cm.

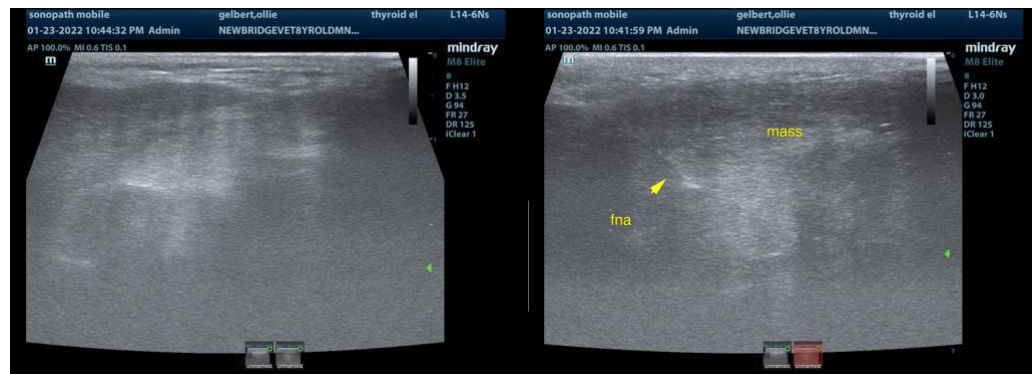
## ULTRASONOGRAPHIC FINDINGS

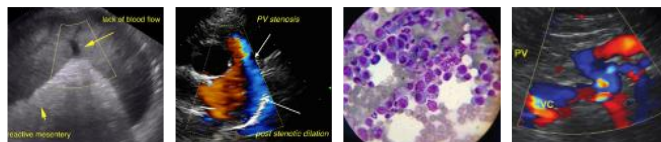
- Prominent parathyroids, likely incidental finding
- Granulomatous or lipomatous type mass in the subcutaneous space, possibly resectable. CT evaluation warranted. Lipogranuloma versus liposarcoma are primary concerns.

## INTERPRETATION OF THE FINDINGS & FURTHER RECOMMENDATIONS

**SonoPath CT Services** are offered at the [Blairstown Animal Hospital](#). Blairstown animal hospital is just a 30-minute drive west on route 80 from the route 80/287 interchange/Parsippany, New Jersey. More information can be found at:

<https://sonopath.com/resources/sonopaths-teleconsultation-services-and-sdep-certification/sonopath-ct-services>





**PATIENT**

Ollie Gelbert

**SPECIES**

Canine

**BREED**

Cavalier King Charles

**SEX**

Neutered Male

**AGE**

8 Years

**WEIGHT**

35 Lbs.

**INTERPRETED BY**

Eric Lindquist, DMV  
DABVP, Cert. IVUSS

**IMAGING PERFORMED BY**

Kelly Vazquez

**HOSPITAL NAME**

New Bridge VP

**REFERRING VET**

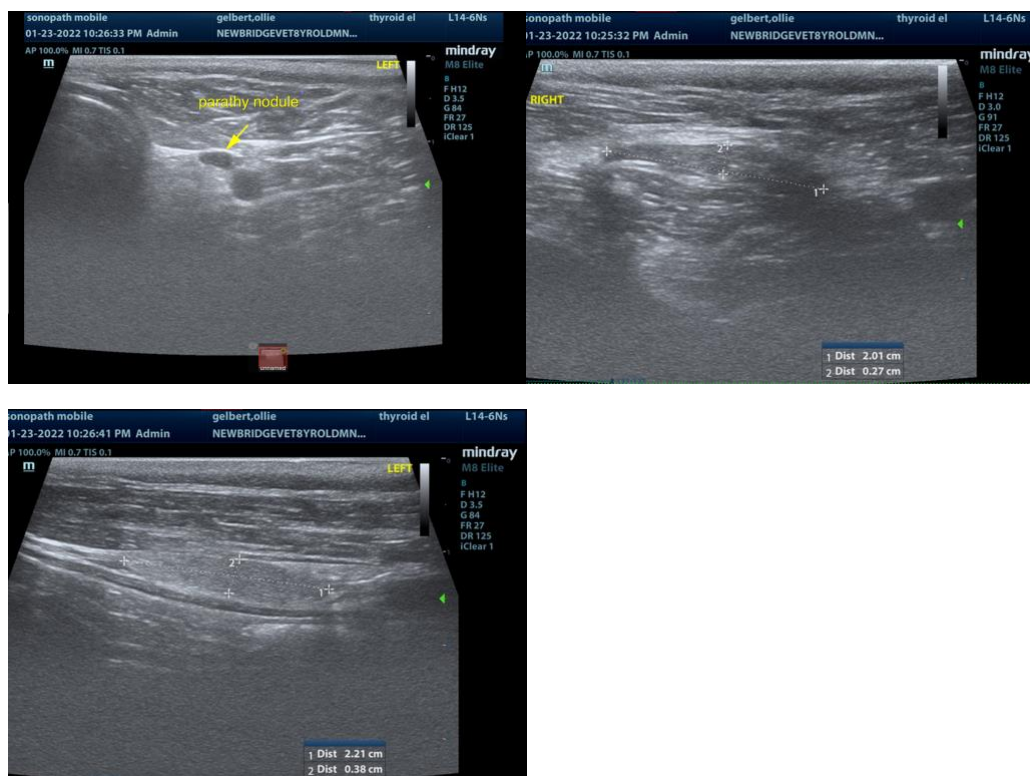
Dr. Glennon

**INVOICE**

13596

**DATE**

1/24/22



The information and recommendations provided are based on the images presented by the referring veterinarian. No evaluation can be communicated regarding pathology that was not visible in the image/video clips provided.

Thank you for this referral. If the clinical or image interpretation does not parallel your findings or if I can be of any further assistance please contact me.

**Eric Lindquist**, DMV, DABVP, Cert. IVUSS, CEO of SonoPath.com  
info@SonoPath.com